

BERNHARD LIEDL

President ICOPF (International Collaboration of Pelvic Floor Surgeons)

Almost all modern urogynecological surgery has been inspired by 2 major scientific discoveries. In the 1990s, an entirely new theory, the "Integral Theory", by Petros (Australia) and Ulmsten (Sweden)^{1,2}, proposed that bowel and bladder problems originate mainly from damaged vaginal ligaments, not from the bladder or bowel itself.

The second discovery by Petros and Papadimitriou⁴, was a method for repairing these ligaments by creation of artificial ligaments. This had the effect of converting major operations with large incisions to relatively minor procedures performed through "keyhole incisions".

Application of these twin discoveries has revolutionized the treatment of stress incontinence, with more than 1,500,000 operations performed world-wide to date. The experience of myself and other surgeons world-wide, confirms that this method can cure or improve many other conditions besides stress incontinence, for instance, prolapse, and symptoms such as urgency, nocturia, pelvic pain, bowel and bladder incontinence⁵⁻⁷.

Many of these conditions were previously considered incurable.

It takes many years for a radical change in thinking to become widely known, especially when it involves a whole new approach to diagnosis and treatment.

This presentation, "A simplified clinical approach" has been especially prepared for those readers who are not familiar with the Integral Theory System. It begins with the basic anatomy of the structures. Then, step by step, the reader is introduced to the ligaments and other connective tissue structures, and their key role in pelvic floor function, dysfunction, diagnosis and surgery. A number of practical clinical examples outline in detail how to diagnose the site of connective tissue damage, and correction thereof, using the minimally invasive "keyhole" surgical procedures which derive from the Integral Theory System.

Some original articles based on the Integral System follow: 1.) 3 year follow-up data on an RCT of 80 patients between the TFS midurethral sling and a TOT approach; 2) a case report of hemorrhoid cure following TFS sling applications to the uterosacral ligaments and perineal body for cure of large rectocele; 3.) symptom cure of pelvic pain, nocturia, abnormal emptying, urgency and idiopathic fecal incontinence in 67 patients who had a posterior TFS sling; 4.) an interesting challenge to the theory's prediction that many symptoms of pelvic pain, vulvodinia, and interstitial cystitis may be referred pain from the uterosacral ligaments. Three patients with documented Interstitial Cystitis reported temporary disappearance of urethral and cervical tenderness, vulval hypersensitivity and lower abdominal pain following local anesthetic injection into the region of the uterosacral ligaments.

It is hoped that these presentations will stimulate researchers to go one step beyond presentation of observational data, and to reference their findings against the Integral Theory System's predictions, so as to test the Theory for truth or falsity.

REFERENCES

1. Petros P E, Ulmsten U, An Integral Theory of female urinary incontinence. *Acta Obstetrica et Gynecologica Scandinavica*, Supplement 153, Vol 69, (1990), 1-79.
2. Petros P E, Ulmsten U, An Integral Theory and its Method, for the Diagnosis and Management of female urinary incontinence, *Scandinavian Journal of Urology and Nephrology* (1993) - Vol 27 Supplement No 153 – 1-93.
3. Petros P E, The International Continence Society and Integral Theory systems for management of the incontinent female -a comparative analysis. *Pelviperrineology* 2007; 26: 25-29
4. Petros P E, Ulmsten U, Papadimitriou J, The Autogenic Neoligament procedure: A technique for planned formation of an artificial neoligament. *Acta Obstetrica et Gynecologica Scandinavica*, Supplement 153, Vol 69, (1990), 43-51.
5. Petros P E, New ambulatory surgical methods using an anatomical classification of urinary dysfunction improve stress, urge, and abnormal emptying, *Int. J. Urogynecology* (1997) vol 8, 5: 270-278.
6. Abendstein B, Petros PE, Richardson PA Ligamentous repair using the Tissue Fixation System confirms a causal link between damaged suspensory ligaments and urinary and fecal incontinence, 2008, *J. Pelviperrineology*, 27;114-117.
7. Abendstein B, Brugger BA, Furtschegger A, Rieger M, Petros PE, . Role of the uterosacral ligaments in the causation of rectal intussusception, abnormal bowel emptying, and fecal incontinence-a prospective study, (2008), *J. Pelviperrineology*, 27;118-121.

Correspondence to:

BERNHARD LIEDL

Chefarzt Urogenitale Chirurgie

Beckenbodenzentrum München, Denningerstr. 44, D-81679 München

E-mail: liedl@bbzmuenchen.de

Phone: +49-89-92794-1522

The Integral Theory System.

A simplified clinical approach with illustrative case histories

PETER E. PAPA PETROS^(1,2)

⁽¹⁾ University of Western Australia

Abstract: *The integral theory:* states that prolapse and pelvic floor symptoms such as urinary stress, urge, abnormal bowel and bladder emptying, and some forms of pelvic pain, mainly arise, for different reasons, from laxity in the vagina or its supporting ligaments, a result of altered connective tissue. **Normal Function:** The organs are suspended by ligaments against which muscles contract to open or close the outlet tubes, urethra and anus. These ligaments fall naturally into a 3 zone classification, anterior, middle, and posterior.

Dysfunction: Damaged ligaments weaken the force of muscle contraction, causing prolapse and abnormal bladder and bowel symptoms

Diagnosis: A pictorial diagnostic algorithm relates specific symptoms to damaged ligaments in each zone.

Treatment: In mild cases, new pelvic floor muscle exercises based on a squatting principle strengthen the natural closure muscles and their ligamentous insertions, thereby improving the symptoms predicted by the Theory. With more severe cases, polypropylene tapes applied through “keyhole” incision using special instruments reinforce the damaged ligaments, restoring structure and function.

Problems which can be potentially addressed by application of the Integral System: Urinary stress incontinence; Urinary urge incontinence; Abnormal bladder emptying; Faecal incontinence and “obstructed evacuation” (“constipation”); Pelvic pain, and some types of vulvodynia and interstitial cystitis; Organ prolapse.

Key words: Integral Theory; diagnosis; minisling; ligaments; connective tissue; pictorial algorithm.

INTRODUCTION

The Integral Theory states that prolapse and most pelvic floor symptoms such as urinary stress, urge, abnormal bowel and bladder emptying, and some forms of pelvic pain, mainly arise, for different reasons, from laxity in the vagina or its supporting ligaments, a result of altered connective tissue.¹⁻⁵ Birth related laxity, fig. 1, compounded by ageing, are the principal causes of ligament laxity.

The Integral Theory has evolved into the Integral Theory System, which applies the damaged ligament theory to

- **Function** – the role of competent suspensory ligaments in organ support and function.
- **Dysfunction**-how damaged ligaments upset the musculoelastic control mechanism to cause prolapse and abnormal bowel and bladder symptoms.
- **Diagnosis**- how to diagnose which damaged ligaments are causing which prolapse and which symptoms.
- **Treatment** - in mild cases, new pelvic floor muscle exercises based on a squatting principle strengthen the natural closure muscles and their ligamentous insertions. With more severe cases, polypropylene tapes applied through “keyhole” incision using special instruments, reinforce the damaged ligaments, restoring structure and function.

PART 1

THE DYNAMIC ANATOMY OF NORMAL FUNCTION

Bladder, bowel and uterus

Fig. 2 is a schematic view of the bladder, bowel and uterus with the woman in a sitting position. The organs are storage containers. The bladder stores urine, the uterus the foetus, and the rectum faeces. Each organ is connected to the outside by a tube, the urethra, which is about 4cm long, vagina, which is 10-12cm long, and the anus, about 4 cm long. The menstrual blood and foetus pass through the vagina. Urine and faeces pass through the urethra and anus. Muscles compress these tubes to close them, and stretch them open for emptying.

The importance of suspensory ligaments

“Problems of bladder, bowel, prolapse, and some types of pelvic pain, mainly originate from the vaginal ligaments, not from the organs themselves”- *Integral Theory* 1996.

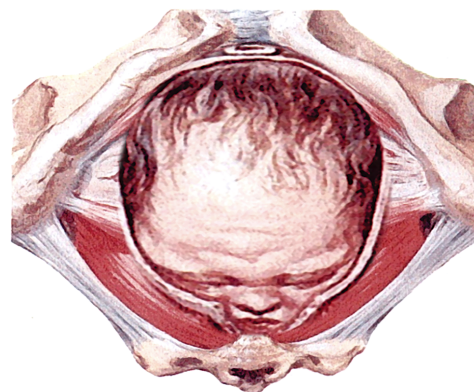


Fig. 1 - Birth-related laxity The diagram shows the baby’s head severely stretching ligaments and other tissues in and outside the vagina. This may cause various degrees of looseness, prolapse of the bladder and bowel, and urine and bowel incontinence. Fundamental to any surgical treatment is the approximation of laterally displaced tissues, and the strengthening of damaged suspensory ligament(s).

The bladder sits on top of the vagina, and is partly attached to it. Muscles pull against the ligaments to close or open the urethra. Therefore loose ligaments may weaken the muscle contraction to cause problems with closure (incontinence)

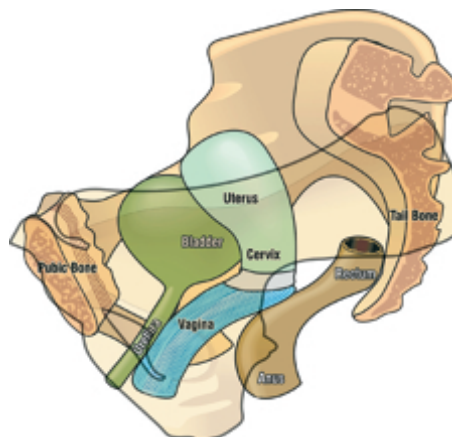


Fig. 2 - The organs and their outlet tubes.

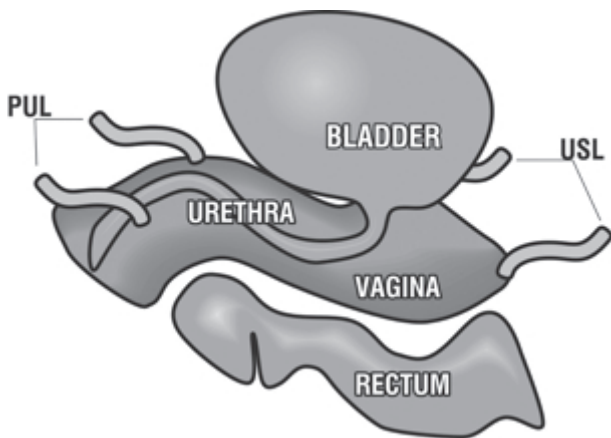


Fig. 3 - Unsuspended ligaments have no shape, strength or function.

or opening (evacuation of urine). Figure 3 indicates what the vagina, bladder, and bowel would look like with no ligaments to suspend them, a blob of tissue, with no form, no structure, no strength, and no function.

A ligament is like a thick cord in a suspension bridge, fig. 4. In fact, the vagina is suspended exactly like a suspension bridge, with the ligaments above, and the muscles (arrows) below. The muscle forces (arrows) contract against the suspensory ligaments to give the bridge form and strength.

The organs, fig. 5, are suspended from above by the vaginal ligaments - exactly like a suspension bridge. All the ligaments are attached to the vagina and/or uterus. The vagina supports the bladder situated above it, and the rectum situated below it, so anything which damages the vaginal structure can also affect the bladder and rectum.

Separating the lower end of the vagina from the rectum is a solid mass of tissue, the perineal body (PB) complex which is about 4 cm long. If this is damaged, the rectum may bulge forwards into the vagina as a rectocele.

The uterus is an anchoring point for the ligaments - it needs to be preserved where possible

The role of the uterus in maintaining the structure, fig. 6, and function of the pelvic floor is greatly underestimated. Some doctors routinely recommend removal of the uterus during surgery for prolapse. It is preferable to retain the uterus wherever possible, as many important ligaments are attached to it. During the menopause, the ovaries cease production of oestrogen. Since oestrogen is essential for maintaining the strength of the ligaments, the detrimental effects of hysterectomy on prolapse and incontinence become especially evident after the menopause. Hysterectomy reduces the blood supply to the cardinal and uterosacral ligaments, weakening them further. All these factors

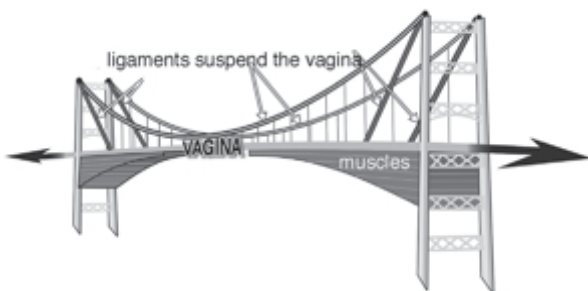

Fig. 4 - The vagina is suspended from above, like a suspension bridge, with the ligaments above, and the muscles (arrows) below. PS=pubic symphysis; S=sacrum; PUL=pubourethral ligament; ATFP=arcus tendineus fascia pelvis; USL=uterosacral ligament.

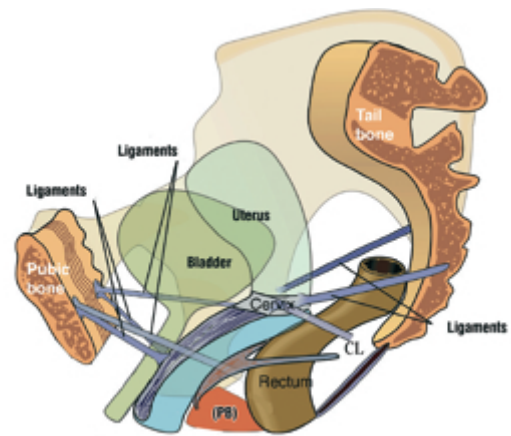


Fig. 5 - Four ligaments suspend the organs from above like a suspension bridge. The perineal body (PB) supports the organs from below. CL=cardinal ligament.

predispose to prolapse, and development of posterior zone symptoms.⁶

The pelvic muscles (dark red), fig.7, have a dual function, organ support, and opening and opening and closure of urethra and anorectum. They extend from the coccyx to the pubic bone, and contract to support the vagina, bladder and bowel from below. The red arrows indicate the directions where the muscles contract, backwards to open these organs, forwards to close them.

An external striated muscle opening and closure mechanism, fig 8,^{7&8, 9-17}

Put simplistically, when the muscles pull backwards (blue arrows), the urethra and anus are pulled open, vastly decreasing intracavity resistance to the 4th power, so that the woman can quickly and easily evacuate her urine and faeces; when the muscles pull forwards* (black arrows), the urethra and anus are closed by a vast increase in resistance to the 4th power. Normally all the organs, even the vagina, are kept in the closed position by slow-twitch muscle contraction.

* The closure mechanism is a little more complex than that depicted in fig. 8, involving a distal and proximal mechanism for closure of the urethral and anal tubes.⁷⁻¹⁰

How damaged ligaments may cause incontinence or emptying disorders. We saw from the suspension bridge diagram, that the muscles pull against the ligaments.

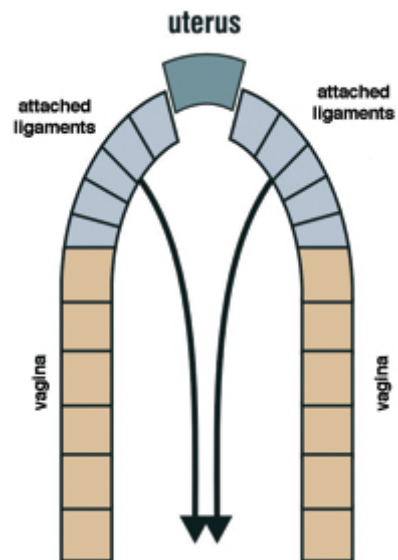


Fig. 6 - The uterus functions like the keystone of an arch. Remove the arch, and the whole structure is put at risk of a downward collapse.

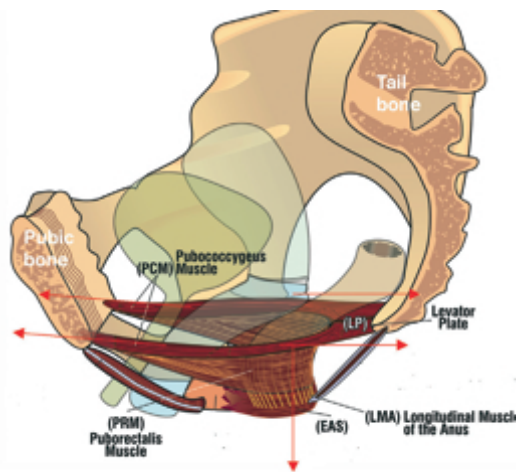


Fig. 7 - The muscles support the organs, vagina, bladder, and bowel from below, and also, open and close them by 3 external directional muscle forces (arrows).

So if the suspensory ligaments are loose, the muscle strength weakens, and may not be able to keep the bladder or bowel emptying tubes closed. As a consequence of this, a patient may feel a leakage of urine, wind or faeces, “incontinence”. Another related condition is failure to close the vaginal tube, so water may enter the vagina during swimming, or complain of vaginal flatus. If the damaged ligaments do not allow the muscles to open these same emptying tubes, a patient may have to strain to empty her bladder or bowel, “evacuation disorder” or “emptying disorder”.

A Symphony Orchestra

The vagina, bladder, bowel, muscles, and ligaments, fig. 9, are like instruments in an orchestra*. The brain is the conductor, and ensures that all the instruments work harmoniously to produce the right music. Every instrument in the orchestra has a specific task. Damage to even one instrument will affect the performance. The brain directs the orchestra to open the bladder (and bowel) or to close it. Depending on what structure is damaged, the bladder may not be able to close properly, and the patient leaks (“incontinence”); or she may not be able empty her bladder, or she may have both problems. Nerves at the base of the bladder (‘N’ in the diagram which follows) sense when the

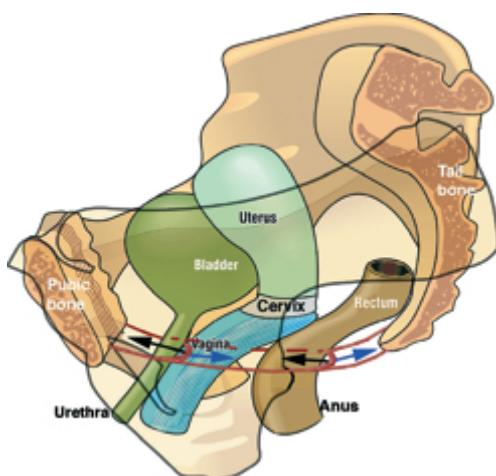


Fig. 8 - An external striated muscle opening and closure mechanism. The red lines represent the pelvic muscles. Fibromuscular extensions from these muscle fibres loop around the urethra and anorectum to activate closure and opening.

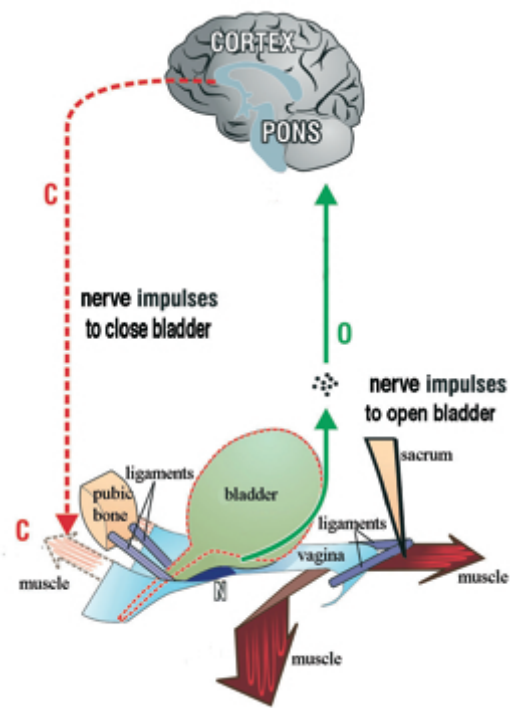


Fig. 9 - The cortex of the brain gives directions for closure (C), and opening (O). Nerves “N”, at the base of the bladder sense when the bladder is full, and send impulses to the brain. Depending on the situation, the brain sends directions either for closure (C), or opening (O). Like instructions from the orchestra conductor, these directions, “C” and “O”, engage all the muscles, nerves, ligaments and tissues required for each function. The Pons, a lower part of the brain, works as a co-ordinating station.

bladder is full, and send impulses to the brain. These are perceived as urgency, a desire to go to the toilet.

* I am grateful to Dr Alfons Gunnemann for the orchestra analogy

The brain and its nerves- a sophisticated feedback system

The brain works like the computer at a big telephone exchange. Think of the nerves as telephone wires going out to the bladder, the vagina and bowel. These organs have sensors which send signals posterior to the brain via another set of nerves, to inform it as to what is happening. The brain receives and processes these signals, and depending on what is required, sends out orders via a series of nerves. Most of this co-ordination occurs in “automatic mode”. The patient is not aware of what is happening. Sometimes, a patient may actually instruct the brain. For example, if it is inconvenient to empty the bladder or bowel, the muscles can be pulled upwards to close off the urethral and anal tubes. Pushing down assist emptying the urine and faeces. During intercourse the vagina can be narrowed by pulling the muscles upwards. This action grips the penis, and increases the sensation for both partners.

PART 2

DYSFUNCTION - THE ROLE OF LAX LIGAMENTS IN THE CAUSATION OF SYMPTOMS AND PROLAPSE

The structure of ligaments

A ligament is a complicated contractile structure which needs to be both elastic and strong, and have the ability to contract or relax according to whether the urethra and anus are being closed or opened. It relies on its collagen content for strength, elastin for flexibility, smooth muscle for contractility, and nerves to co-ordinate all these functions.

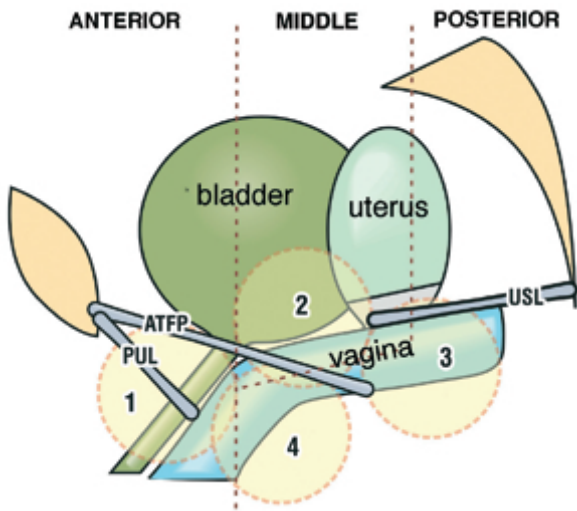


Fig. 10 - The baby's head (circles) may damage the ligaments and vaginal tissues to varying degrees as it descends through the vagina to cause stress incontinence '1', cystocoele '2', uterine/apical prolapse '3', and rectocoele '4'. PUL=pubourethral ligament; ATFP=arcus tendineus fascia pelvis; USL=uterosacral ligament. Not shown are cardinal ligament (Middle Zone) and Perineal Body (Posterior zone).

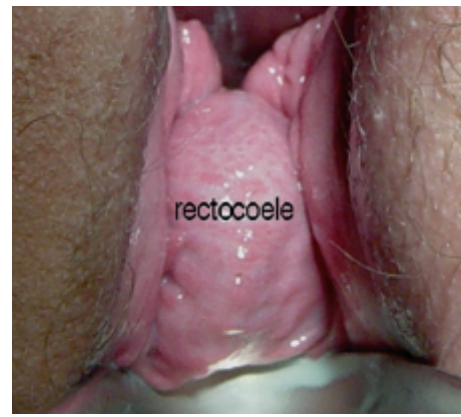

Fig. 13 - A rectocoele bulging out of the vagina during straining.

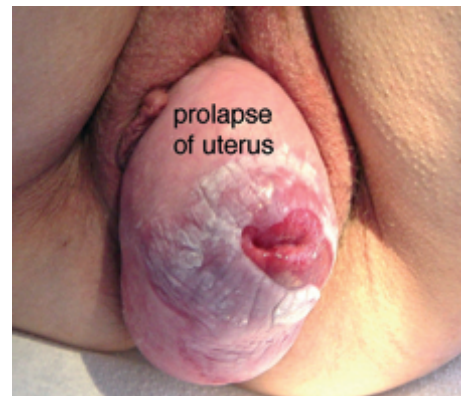

Fig. 14 - A uterus chronically bulging out of the vagina. The white areas are caused by chronic friction.

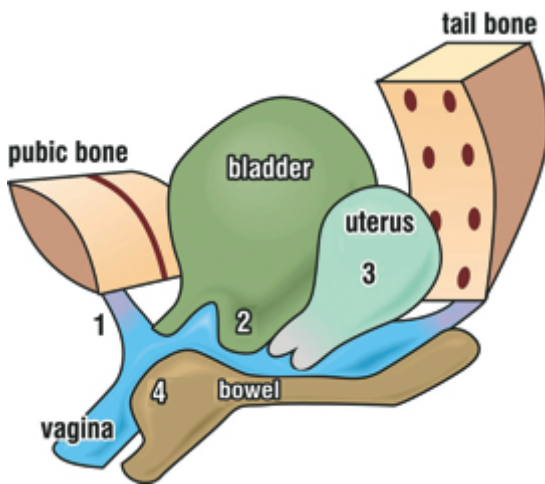


Fig. 11 - This diagram illustrates the cystocoele "2", rectocoele "4" and uterus "3", all pushing into the vagina, as "lumps", like a glove turning inside out. All are caused by looseness in the suspensory ligaments and their associated tissues.

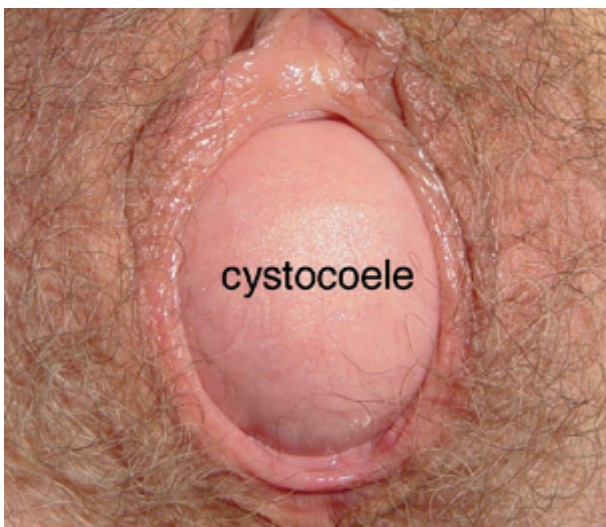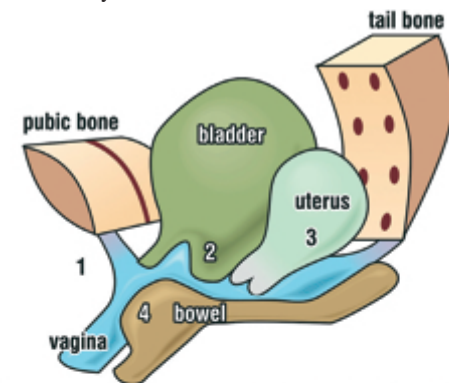


Fig. 12 - A cystocoele bulging out of the vaginal entrance during straining.

Front ligaments	Middle ligaments	Back ligaments
Stress incontinence	cystocoele	Prolapse of uterus Rectocoele
	abnormal emptying	
	frequency and urgency	
		nocturia
faecal incontinence		faecal incontinence obstructed defecation
		pelvic pain

Fig. 15 - Pictorial Diagnostic Algorithm. The anterior (pubourethral) and posterior (uterosacral) ligaments are in purple. The middle ligaments (ATFP & cardinal) are not shown in this diagram. There are 3 columns, one for each ligament group and the symptoms and prolapses (lumps) associated with damage to these ligaments. Labelling is 'front' and 'back' instead of 'anterior' and 'posterior'.

Collagen fibres work like the steel rods in cement. Single collagen fibres are “glued” together to give ligaments strength. The elastin content gives them elasticity. It is the change in collagen which is the ultimate cause of prolapse and incontinence.

How ligaments are stretched and damaged during pregnancy and labour

As we saw from the suspension bridge diagram, the muscles pull against the ligaments which support the bridge. If the ligaments are stretched and loosened during childbirth, as in fig. 1, a patient may develop a prolapse, a “dragging” pain low in the abdomen, bladder symptoms, for example urgency, frequency, nocturia, or even problems with bowel emptying or faecal incontinence.

Commencing 6 months before childbirth, the “glue” between the collagen rods begins to soften in response to hormones from the placenta (“afterbirth”). This explains the onset of bladder, bowel, and pain symptoms at this time. Some 24-48 hours before delivery, however, this softening accelerates, and the collagen rods lose 95% of their strength.¹⁸ During delivery, the baby’s head greatly stretches these collagen rods. Of course, the rods “re-glue” soon after delivery, but often they “re-glue” in a loose and extended position. Neither the ligaments nor the muscles can now work properly, and this may lead to prolapse of the uterus, cystocele, rectocele, and a wide range of bladder, bowel and pelvic pain symptoms (fig. 11). Women who have had Caesarian sections may also become incontinent, but they have less stretching, and therefore, fewer problems than vaginal delivery patients. Loose ligaments may occur in women who have never had children. Such women are born with loose ligaments, or they may have a congenital defect in their collagen. All these conditions are potentially curable by creation of artificial ligaments, as will be explained later.

The effect of age and menopause

Both collagen and elastin deteriorate markedly after the menopause, and this explains the vast increase in prolapse and incontinence which occurs after this event. A partly damaged ligament which is only just functioning before the menopause, may lose enough collagen after it, to “give way”. This looseness may result in organ prolapse, abnormal symptoms, or both. The oestrogen hormone replacement therapy (“HRT”) helps to slow down the degeneration of collagen. HRT can be applied vaginally, or by patches, creams, tablets, injections. Though oestrogens may be associated with an apparent increased risk of breast cancer, this has to be weighed against their benefits, prevention of osteoporosis, hip fractures, thickening of the vaginal wall in sexually active patients, even perhaps prevention of heart disease. Vaginally inserted oestrogen tablets are considered safe, as they act locally, and so are advantageous for every post-menopausal woman, even those of the most mature age.

Site of damage and its consequences

The circles in fig. 10 represent the baby’s head descending through the vagina during childbirth. This may stretch and loosen the ligaments (thick grey lines) in the 3 zones of the vagina. These are, Anterior Zone (meatus to bladder neck), Middle Zone, (bladder neck to cervix), and the Posterior Zone (cervix to perineal body). The numbers 1-4 indicate damage to specific ligaments which may cause

1. Stress incontinence
2. Cystocele
3. Prolapse of the uterus
4. Rectocele.

All may occur to varying degrees in the same patient.

It is evident that a head descending down a vulnerable

vaginal canal, fig. 10, is unlikely to damage just one single structure. All structures will be damaged to a greater or lesser extent. This explains appearance of a cystocele, for example, months or years after apparently successful surgery for prolapse of the uterus. Further prolapse can occur in perhaps 30-50% of cases after a successful vaginal repair. The problem is that once the vaginal tissues are damaged, it is difficult to fully repair them. It is like repairing frayed cloth. The surgeon repairs one area, only to see it give way in another area. That is why we have to create artificial ligaments by using tapes.

A *cystocele* “balloons” out from above, fig. 12. The cause is damage to the middle ligaments (ATFP and/or cardinal ligaments) and the anterior wall of the vagina.

A *rectocele*, fig. 13, balloons out from below. Separating the lower end of the vagina from the rectum is the perineal body, a major supporting structure, as it occupies 50% of the posterior vaginal wall. A rectocele, may be caused by damage to the uterosacral ligaments (high rectocele), and/or rectovaginal fascia & perineal bodies (mid & low rectocele).

Uterine prolapse, fig. 14, is caused by damage to the cardinal and uterosacral ligaments.

A perspective on organ prolapse

The organs bulge to varying degrees. Clearly a severe prolapse, such as the uterine prolapse above, requires treatment. If the bulge is minor, and there are no associated symptoms, there is no need for treatment. However, a patient may have severe symptoms which may require treatment, even though the prolapse is minor.

When are these symptoms and prolapses problematical?

If a patient answers “yes” to one of the following, she has a problem.

1. You lose urine during exertion or coughing.
2. You can’t “hold on” and you wet yourself.
3. You can’t empty your bladder properly.
4. You have bowel soiling.
5. You feel a lump in your vagina (prolapse)
6. You have lower abdominal or pelvic pain.

How serious is the problem?

Assessment by the patient. This question “how serious is my problem” is not so easy to answer, as symptoms vary, and patients’ perceptions vary. A simple rule is to seek help if it is interfering with the patient’s quality of life. If the problem is mild and not bothersome, no action is required.

Assessment by the clinic. The doctor has a different perspective, a) to assess which ligaments have been damaged, and b) to assess the seriousness of the problem. An accurate assessment is paramount. This will vary according to the clinic, but at a minimum, use of the Pictorial Diagnostic Algorithm, examination to assess ligamentous damage in the 3 zones, and “simulated operations”(e.g. midurethral anchoring during coughing in patients with urinary stress incontinence or urge symptoms).

Symptoms – what they mean

A symptom is a warning bell from the brain that something is wrong with some part of the body. As regards the pelvic floor, many bladder and bowel symptoms are secondary to damage in one or more related ligaments, not from the organ itself. The challenge is to find which ligaments are causing the problem.

The Diagnostic Algorithm indicates which ligaments are causing symptoms and prolapse

The Diagnostic Algorithm which follows is a simplified version of that published in the textbook, “The Female Pelvic Floor” 2nd Edition (2006), Springer, Heidelberg. To use this diagram, a tick is placed in every column which describes a patient’s symptoms, and the diagram will indicate the zone of damage, anterior, middle, or posterior ligaments.

How to use the Diagnostic Algorithm. Simply tick every column which describes a symptom. One needs to tick all the relevant columns for symptoms such as urgency and emptying, which may occur in more than one column. In such cases, other associated symptoms which are more specific, will help to guide the diagnosis.

Definitions for Symptoms

- *Stress incontinence* Urine loss on effort, such as coughing, exercise.
- *Abnormal emptying* Inability to empty the bladder or abnormal flow.
- *Urgency* An uncontrollable desire to pass urine.
- *Frequency* Going more than 8 times a day to the toilet to pass urine.
- *Nocturia* Getting up twice or more per night to pass urine.
- *Faecal incontinence* Uncontrolled soiling from the bowel.
- *Obstructed defaecation or constipation* Difficulty in emptying the bowel.
- *Pelvic pain.* Pain in the lower abdomen, lower posterior, or during intercourse. Some types of vulvodynia and interstitial cystitis are often associated with pelvic pain.

Symptoms occur in groups – an aid to diagnosis

For example, urgency symptoms are indicated in all 3 columns. Symptom grouping is the only way we can deduce which column (ligament) is causing the urgency. Fortunately, urgency almost always occurs in tandem with at least one other symptom.

Characteristics of pain caused by posterior ligament looseness*

- Low abdominal ‘dragging’ pain usually unilateral, often right-sided
- Low sacral pain (pain near the tailbone)
- Pain on deep penetration with intercourse
- Low abdominal ache the next day after intercourse
- Tiredness
- Irritability
- Pain worsens during the day, and is relieved by lying down
- Pain is reproduced on pressing the cervix or the posterior wall of the vagina if a patient has had a hysterectomy.

* There is growing evidence that some types of introital hypersensitivity (‘vulvodynia’) and perhaps even some types of bladder pain (‘interstitial cystitis’) may be part of the posterior zone symptom complex in figure 15, nocturia, urgency and abnormal bladder emptying.

Characteristics of ‘vulvodynia’

A burning pain over the entrance of the vagina and anus, with extreme sensitive to touch. This condition is often associated with dragging lower abdominal pain and sometimes painful bladder conditions.

Characteristics of bladder emptying difficulty

Typical symptoms are a slow stream, starting and stopping, dribbling after micturition has been completed, a feeling that the bladder has not emptied. Often such patients have chronic urinary infections.

Characteristics of faecal incontinence

Typical symptoms, in order of severity, are uncontrolled wind loss, liquid soiling, solid faecal soiling. There are two main categories, patients with faecal incontinence caused by an anal sphincter torn at childbirth, and another where no obvious cause can be found. The anal sphincter constricts the lower part of the anus. It is what a patient feels when she contracts her muscles to delay bowel emptying. Where no obvious cause can be found, it is called “idiopathic incontinence”. It is “idiopathic incontinence” which is potentially curable by reconstructing the anterior or posterior ligaments.

Characteristics of lumps (prolapse) in the vagina

Initially, these only appear during straining. The three main causes of such ‘lumps’ are from the bladder (cystocele “2”) uterus (“3”) and bowel (rectocele “4”), fig. 15. These can only be accurately diagnosed by a vaginal examination, as not all lumps are accompanied by symptoms. Where symptoms accompany the prolapse, the symptoms may give an indication of where the problem is. For example if a patient has a lump plus nocturia, pelvic pain and urgency, it is highly likely that she has weak posterior ligaments, as per the Diagnostic Diagram, fig. 15.

New time efficient pelvic floor exercises strengthen muscles and ligaments

In 1995, we first conceived another approach to pelvic floor exercises. We knew from our ultrasound studies that the traditional Kegel methods were NOT addressing the posterior closure muscles, which stretch, rotate, and close the proximal urethra against the pubourethral ligament.

Our ultrasound studies had demonstrated that squatting exercises the very same muscles which close the urethra during coughing. We also reasoned that strengthening a pelvic muscle would also strengthen the ligament against which it contracted, and we knew from the surgery, that it was ligament weakness which was causing the incontinence problems.

We therefore added squatting exercises to the traditional Kegel programme. Our target group of patients were those with symptoms which were bothersome, but not sufficiently to require surgery. The results were dramatic. This patient group reported a more than 60% improvement in such symptoms as urgency, nocturia, pelvic pain, and abnormal bladder emptying. The most interesting observation, however, was that those patients who were cured, did not need to remember to contract their pelvic floor in advance. They coughed, and did not leak.¹⁹⁻²¹

A major problem with pelvic floor exercises is that women with young families and jobs, simply do not have time to perform them regularly. Even with our highly motivated group, the dropout rate was 50%. Because of this, we concluded that the programme required re-analysis. We knew that the slow-twitch muscle fibres were the prime contributors to continence. Sitting on a “fitball” instead of a chair, is a very simple and effective exercise technique, as it requires a balanced upright position, with co-ordinated contraction of abdominal, back, and pelvic floor muscles. Unlike all traditional Kegel exercises which require attention and time, sitting on a “fitball” requires no extra time to be set aside during the day. We have found that the “fitball” method applied alone was well accepted, and results seemed equally effective in the short-term.



Fig. 16 - Sitting on a rubber “fitball” instead of a chair strengthen all the pelvic slow-twitch muscles, and their ligamentous attachments.

Surgery based on the Integral Theory System

“Tension-free” techniques Beginning in the late 1980s an entirely new surgical method for stress incontinence was introduced. Polypropylene tapes were placed around the middle part of the urethra (best known as the “TVT” operation) to reinforce the pubourethral ligaments, then a little later, the posterior ligaments (infracoccygeal sacropexy, “PIVS”).⁵ This method, now known as the “tension-free tape” technique, has revolutionized the treatment of stress incontinence (SI) and prolapse surgery. The operations are conducted via 1cm incisions in the abdominal skin just above the pubic bone, groin or perineum. There is minimal pain, hospital stay is reduced to 1 or 2 days, and patients generally have few problems passing urine after the operation. The cure rate is high in the longer term. Later variations of these operations, include the transobturator (TOT) approach for SI (very successful), and the addition of mesh sheets to the TOT and PIVS techniques (not so successful). The only significant problem with all tape/mesh implant operations, was partial or total rejection of the tape/mesh. More recently, an even less invasive method, the “minisling” has been introduced to address incontinence and organ prolapse.²²

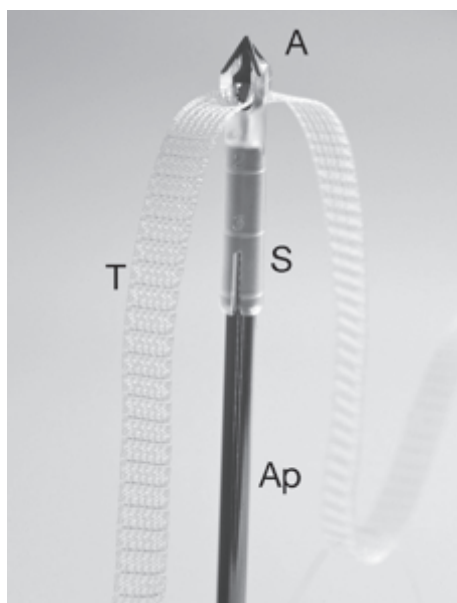


Fig. 17 - TFS applicator ‘Ap’. ‘A’ is the soft tissue anchor which sits on the saddle ‘S’. The tape ‘T’ is a ‘next generation’ non-stretch macroporous monofilament polypropylene tape. The polypropylene tape passes through the unidirectional ‘trapdoor’ at the base of the anchor. This one-way system of tightening brings the laterally displaced ligaments and fascia towards the midline.

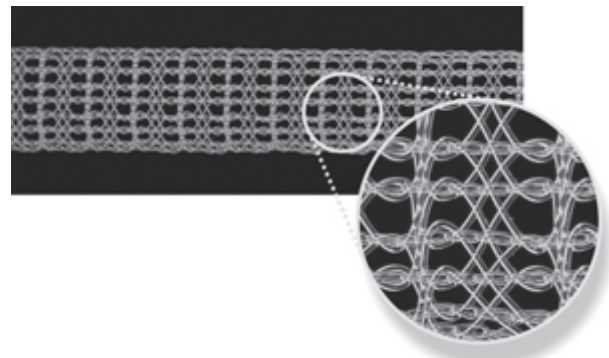


Fig. 18 - An example of ‘next generation’ nonstretch monofilament tape. Such tapes are purpose knitted, not cut from sheets, with finer fibrils, and less weight per unit area. They do not fragment, and are less likely to surface in the wound.

Minislings- a new horizon for stress incontinence, and repair of cystocoele, rectocoele, and prolapse of the uterus.

The TFS, fig 17, was the first minisling. It was applied in late 2003 to a patient with stress incontinence and uterovaginal prolapse. Since 2006, there has been a profusion of other minislings introduced for cure of stress incontinence, for example, TVT-Secur, Mini Arc, Ophira, and many others.

Because the TFS is a tensioned sling, it can also address not only prolapse, but also, many symptoms from the Pictorial Diagnostic Algorithm (fig. 15), including urgency, nocturia, abnormal emptying and pelvic pain.

Like other minislings, the TFS uses only small sections of monofilament tape (fig. 18), so it causes less tissue irritation. It uses a bioengineering principle similar to that of a buttressed cathedral ceiling (fig. 19) for cystocoele and rectocoele repair. It avoids the spaces between rectum, bladder and vagina, and so it is not subject to the adhesive complications seen with large mesh. As with all polypropylene implantations, the main complication is rejection of the tape by the body’s immune mechanisms. However, this occurs only in a small percentage of patients, as only very small segments of tape are used, and the anchor prevents “slippage” into the wound, a major cause of erosion.

Only a tensioned minisling can reliably improve symptoms

Essential to cure of posterior zone symptoms with the posterior “tension-free” sling was restoration of tissue tension by approximation of laterally displaced tissues.⁵ With the infracoccygeal sacropexy (“posterior IVS”), this could only be done with a suture, which was neither sufficiently strong, nor reliable.

The TFS minisling,²²⁻²⁶ was designed to precisely reconstruct and tension the 5 main structures which support the organs, pubourethral, ATFP, cardinal, uterosacral ligaments, and perineal body, fig. 20, and to approximate laterally displaced tissues.

PART 3

ILLUSTRATIVE CASE HISTORIES

The following illustrative case histories are taken from the files of the Kvinno Centre, Perth Western Australia, the first clinic in the world to apply the Integral Theory System.

ANTERIOR ZONE DAMAGE

In this section, we give a series of typical case reports from patients who came to the Clinic with particular problems which mainly derive from front (pubourethral) ligament looseness, in particular, stress incontinence. We also discuss other less typical problems.

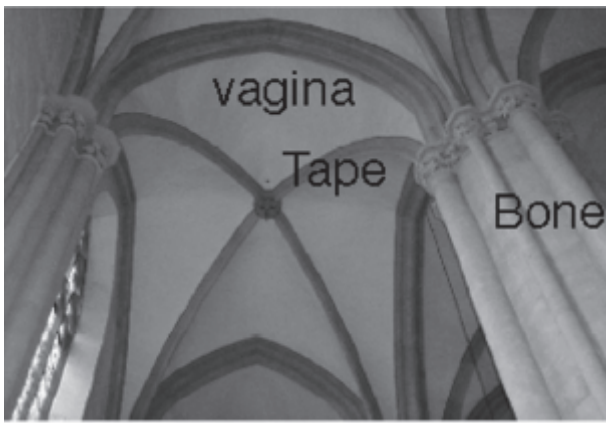


Fig. 19 - The TFS works like a buttressed cathedral ceiling structure. The pillars (bone) provide the anchoring point for the beams (tapes), which in turn provide sufficient support for the weaker plaster board (vagina). Like a wire suspension bridge, tensioned TFS tapes provide a much stronger support than meshes which have a tendency to sag.

Stress incontinence (leaking during coughing) is the main symptom for front ligament looseness.

Mrs CYL, was 55 years old, and she had had 3 normal deliveries. The ultrasound showed that her bladder and urethra became one large funnel when she coughed, and the urine just ran out. The Diagnostic Diagram confirmed that the damage was in the front ligament column, fig. 21. Maximal Urethral Closure Pressure was 16cm H2O.

“Mixed” stress and urge incontinence from front ligament looseness

Mrs JC, was a 38 year para 2. She had stress incontinence, and she also wet with urgency 2-3 times a day before she arrived at the toilet. She had been refused surgery for her stress incontinence because a urodynamic test had shown an “unstable bladder”. With reference to the Diagnostic Diagram, fig. 23, it was evident that she had specific middle or posterior zone symptoms, indicating that her pubourethral ligament (PUL) was probably causing both problems, stress and urge. This was confirmed with a “simulated operation”, gently pressing an instrument upwards on one side in the position of PUL at midurethra, just behind the pubic bone. This controlled her urine loss on coughing, and greatly diminished her urge symptoms. She was cured of both stress and urge with a polypropylene sling placed around the middle of her urethra to strengthen the front ligament.

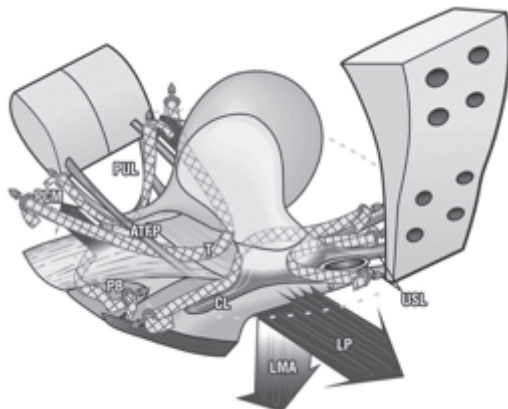
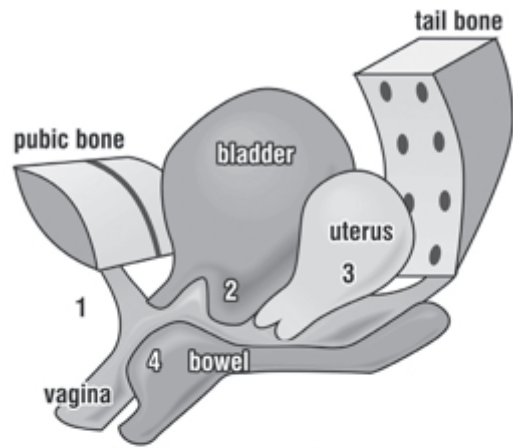


Fig. 20 - The TFS minisling (Tissue Fixation System) a new approach to surgery for prolapse. It works by approximating laterally displaced tissues, and by reinforcing the 4 suspensory ligaments of the vagina, PUL (pubourethral), ATFP, cardinal (CL), uterosacral (USL) and also, the perineal body (PB).



Front ligaments	Middle ligaments cystocele	Back ligaments Prolapse of uterus Rectocele
Stress incontinence ✓		
	abnormal emptying	
	frequency and urgency	
		nocturia
faecal incontinence		faecal incontinence obstructed defecation
		pelvic pain

Fig. 21 - Anterior Zone defect The tick indicates only front ligament damage. A TFS polypropylene tape was inserted through a very small incision in the vagina to repair the front ligament, fig 22 (23,24). The patient went home the next day entirely dry.

Bedwetting from childhood caused by a lax front ligament

Miss M was 25 years old, para 0. She had wet her bed as a child. Bedwetting cleared at puberty, but she still wet with coughing and exercise, and with urge. Ultrasound demonstrated bladder neck rotation, indicating that the front ligament (pubourethral) was loose. Her bladder symptoms were cured with a TFS sling which reinforced her pubourethral ligaments.

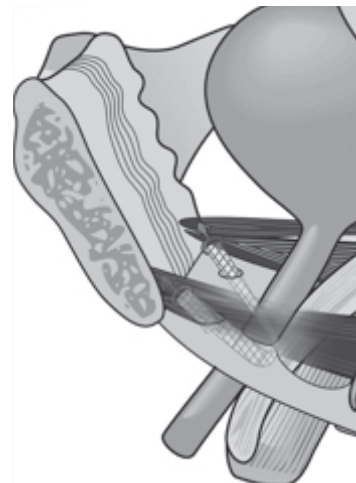


Fig. 22 - The “mini” or “micro” sling is inserted exclusively from the vagina. It avoids most complications of “tension-free” slings.

Bedwetting from childhood and faecal incontinence caused by a lax front ligament

In contrast, Miss G, 18 years old, had continued wetting wet her bed since childhood, and also had stress urinary and faecal incontinence. On examination, her urine loss was controlled by gentle pressure upwards in the vagina, applied just behind the pubic bone. Transperineal ultrasound demonstrated rotation of bladder neck, indicative of a loose anterior (pubourethral) ligament. At the 6 week post-operative visit, all symptoms were cured, and there was a remarkable transformation in the patient's psychological state.

Stress faecal incontinence caused by a lax front ligament

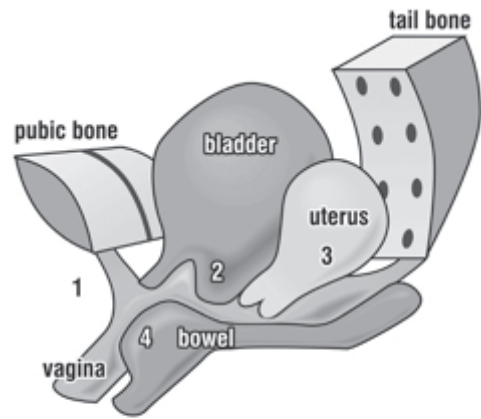
Mrs T, 45years old, came to see us because she lost urine and solid faeces on coughing. Again, symptom grouping gave us the clue that her symptoms originated from pubourethral ligament damage. Her assessment indicated she had damaged front ligaments, which was successfully addressed with a polypropylene midurethral sling.²⁷

Comment

The bowel works in a similar way to the bladder. If a ligament is loose, the muscles which close the bowel cannot work properly, and the patient may leak wind, fluid or solid faeces

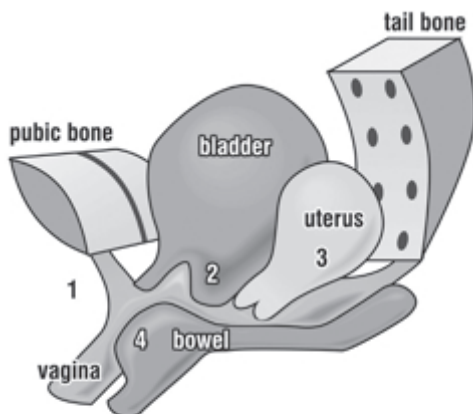
MIDDLE ZONE DAMAGE (CYSTOCOELE)

In this section, a series of typical case reports is presented from patients who came to our Clinic with particular problems which mainly derive from middle ligament



Front ligaments	Middle ligaments cystocele	Back ligaments Prolapse of uterus Rectocele
Stress incontinence ✓		
	abnormal emptying	
	frequency and urgency	
		nocturia
faecal incontinence ✓		faecal incontinence ✓ obstructed defecation
		pelvic pain

Fig. 24 - Anterior Zone Defect Stress and faecal incontinence. Grouping of SI symptoms with FI, and absence of other posterior zone symptoms indicates anterior ligament damage.



Front ligaments	Middle ligaments cystocele	Back ligaments Prolapse of uterus Rectocele
Stress incontinence ✓		
	abnormal emptying	
✓	frequency and urgency ✓	✓
		nocturia
faecal incontinence		faecal incontinence obstructed defecation
		pelvic pain

Fig. 23 - Anterior Zone Defect Stress and Urgency in Mrs JC's case are both most likely caused by damage to the front ligament. Because urge symptoms may derive from all 3 zones, all 3 spaces are ticked. Diagnosis of anterior zone defect was made by deduction using the presence of SI and absence of other zone-specific symptoms.

looseness. Mostly patients with a cystocele, only complain of a "lump" in the vagina. However, they sometimes have symptoms of urgency and difficulty in emptying the bladder, and chronic bladder infections.

Urge incontinence caused by cystocele occurring after prolapse repair

Mrs DV was 53 years old. She had had a successful repair of the uterosacral ligaments for prolapse of the uterus 12 months earlier. She came to see us, stating that her symptoms had reappeared in the past few weeks.

It was noted from Mrs DV's questionnaire, that the nocturia and pelvic pain she had 12 months ago, remained cured, fig. 25. When she was examined, it was evident that her posterior ligaments (uterosacrals) were intact. There was no prolapse of the uterus. However, a cystocele was seen just inside the vaginal entrance on straining. Her urgency symptoms were relieved by gently supporting the cystocele, indicating that this was the cause of her urge symptoms. The cystocele was cured by TFS AAFP and cardinal ligament operation, fig 26. Relief of urgency, and improved bladder emptying were reported immediately after the surgery.²²

Comment Mrs DV is a good example of what happens in patients with damaged ligaments. In up to 30% of cases, repairing one part of the vagina can be followed by another lump or symptom appearing weeks, months or even years later.

Recurrent or chronic cystitis – its relationship to abnormal emptying, cystocele and prolapse of the uterus

Whilst there are many causes of cystitis, this presentation concerns patients who have recurrent cystitis because they

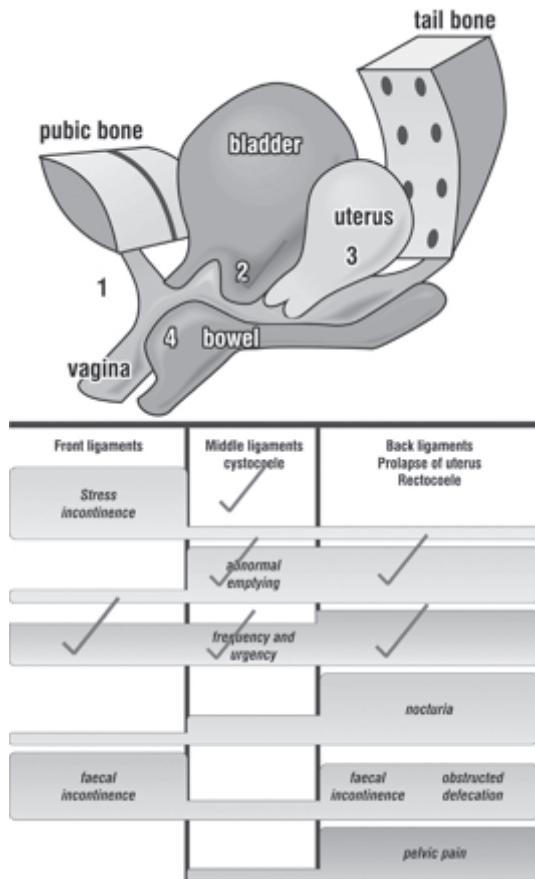


Fig. 25 - Middle Zone Defect The ticks indicated a middle or posterior defect for Mrs DV. The presence of a cystocele, absence of a prolapse of the uterus and its specific symptoms, nocturia and pelvic pain, indicated it was a middle ligament problem.

cannot empty their bladder adequately due to damaged ligaments in the middle or posterior parts of the vagina. In the author's experience, cystocele, and prolapse of the uterus are major correctable causes of abnormal emptying and chronic bladder infections.⁵

Other causes of recurrent cystitis

Anything which irritates the inside of the bladder, such as a polyp, a bladder stone, or penetration of a plastic mesh after a surgical procedure for incontinence can cause recurrent cystitis. The mesh can cause irritation per se, or become calcified into a stone. Inserting a cystoscope into the bladder is the best method for diagnosing such a problem.

Other causes of abnormal emptying?

Anything which interrupts the messages from the brain may cause this problem. One cause which is often stated is diabetes. However, in the author's experience, many patients labelled as "diabetic neuropathy" in fact had damaged uterosacral ligaments which prevented the opening muscles from working properly. Such patients had accompanying symptoms such as nocturia, urgency and pelvic pain, as per the Pictorial Diagnostic Algorithm Diagram, fig. 15, and were able to be cured. A much rarer cause of abnormal emptying, multiple sclerosis, cannot be cured, and often requires intermittent self-catheterization.

Severe wetting on getting out of bed in the morning caused by excessive scarring from previous surgery "tethered vagina" – a hitherto unrecognised problem

Mrs EM, 68 years old, was referred with a history of worsening incontinence over the previous 2 years. She had

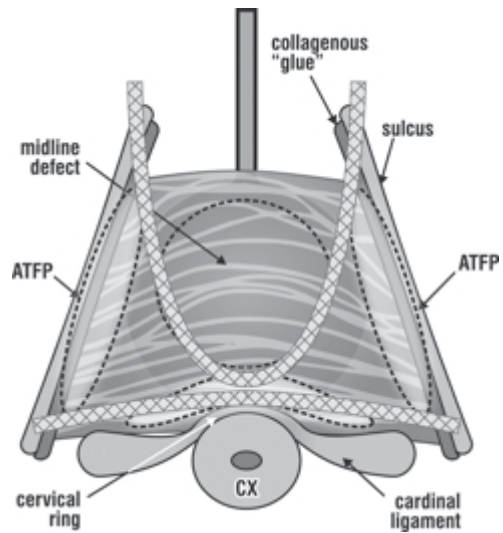


Fig. 26 - The ceiling joist principle for cystocele repair. Schematic view into the anterior wall of the vagina. The horizontal tape provides structural support to the proximal half of the anterior vaginal wall and recreates the cervical ring. The vertical U-sling joins with existing ATFP structures to provide structural support to the distal half of the vagina.

had 4 previous operations for prolapse and incontinence some years earlier. She offered the cardinal symptom of this condition "my bladder empties uncontrollably immediately my foot touches the floor on getting out of bed in the morning." She also lost urine on standing up from a chair, or bending down.

On examination, she did NOT lose urine during coughing, a common feature of this condition. The large amount of urine measured with a 24 hour pad test validated the seriousness of this lady's problem. There was very little movement of her bladder neck during straining with ultrasound testing, consistent with the thick scarring observed in the bladder neck area of her vagina. This scarring immobilized the muscles and ligaments needed to close the urethra, hence the name, "tethered vagina". A skin graft placed in this area, fig. 28, restored elasticity and vastly improved her incontinence.

Comment The "tethered vagina" syndrome is still not a well-recognized condition. It is entirely iatrogenic, and is caused by excessive scarring from previous

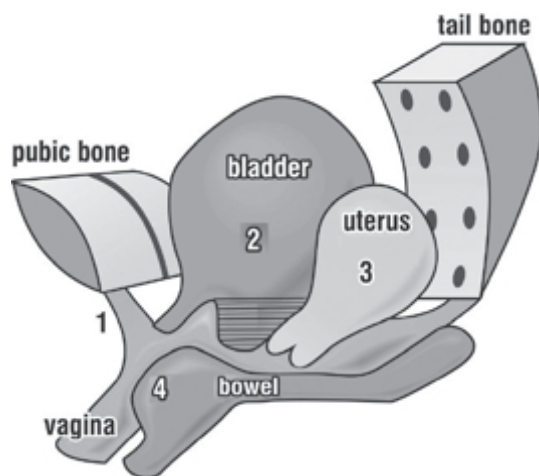


Fig. 27 - The diagram shows how a cystocele "2", droops downwards in a sac, preventing it from emptying. The urine pool gets infected over time, leading to chronic cystitis.

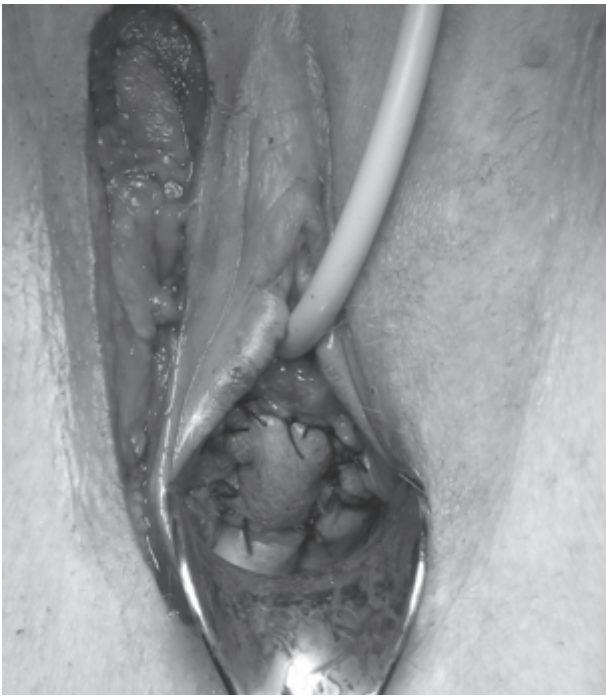

Fig. 28 - Martius skin graft applied to the bladder neck area of the vagina subsequent to extensive freeing of the urethra and vagina from adhesions to the pubic bone and each other in a case of “tethered vagina syndrome”.

surgeries. It is called the “tethered vagina syndrome” because dense scar tissue in the vagina “tethers” the muscles, and prevents them from closing the urethral tube. This condition was not previously recognized as originating from a scarred vagina. It was thought to originate from the bladder itself, and was (still is, by many!) treated with drugs, which, of course, cannot succeed, as the cause is mechanical. Treatment involves restoration of elasticity in the bladder neck area of vagina, using some sort of skin graft. Restoration of continence following skin graft surgery is the ultimate proof of the Integral Theory .

POSTERIOR ZONE DEFECTS

In this section, some typical case reports from patients are presented, from problems which mainly derive from posterior (uterosacral) ligament looseness.

Structural and functional consequences of laxity in the uterosacral ligaments

The problems associated with posterior (uterosacral) ligament damage are usually far more complicated and serious, than those seen with damaged anterior or middle ligaments. Sometimes patients complain of just a “lump” in the vagina without accompanying symptoms. However, symptoms such as pelvic pain, nocturia, and abnormal emptying are found as accompaniments to the prolapse. However, these symptoms may occur without significant prolapse.

Laxity in the uterosacral ligaments associated with uterovaginal prolapse nocturia, urgency, abnormal emptying and pelvic pain

Mrs LM, 53 years old, stated “ I get up 4-5 times a night. I find this very tiring, as I have to work next day. I have a dragging pain on the right side which can be quite distracting by the end of the day. I am always going to the toilet at

work. My urine dribbles away after I stand up, and I often wet the toilet seat. I have problems with bladder infections”

Mrs LM had symptoms typical of looseness in the posterior ligaments, fig. 29. When we examined her, we noted that she had significant prolapse of the uterus, but it was not protruding. A TFS “minisling” was inserted to reinforce the damaged uterosacral ligaments. The advantage of the TFS method is that it can precisely tighten the vaginal membrane to prevent sensitive nerve endings from firing off at a low bladder volume. It is a very minimal technique, and is performed entirely from the vagina. Mrs LM required only an overnight stay in hospital, and she returned to work in 7 days. When reviewed at 9 months, she was getting up only once per night to empty her bladder. She said that her low abdominal pain was still present, but was 90% better. Her bladder emptying also was not entirely cured, but had improved significantly, and she had not had any bladder infections since the operation.

The posterior TFS “minisling” operation is performed entirely from the vagina, which makes it minimally invasive and less painful than other sling procedures which pierce the skin. It has a one-way tightening system, so it can restore the tension in the ligaments (white arrows). Adequate tissue tension is required to support the nerves which cause pain and urgency symptoms. Without restoring the tension, it is unlikely that such symptoms can be cured.

Comment on the causation of urgency, nocturia and pain by damaged ligaments

Strong uterosacral ligaments are required to support the pain fibres which run inside them, and to anchor

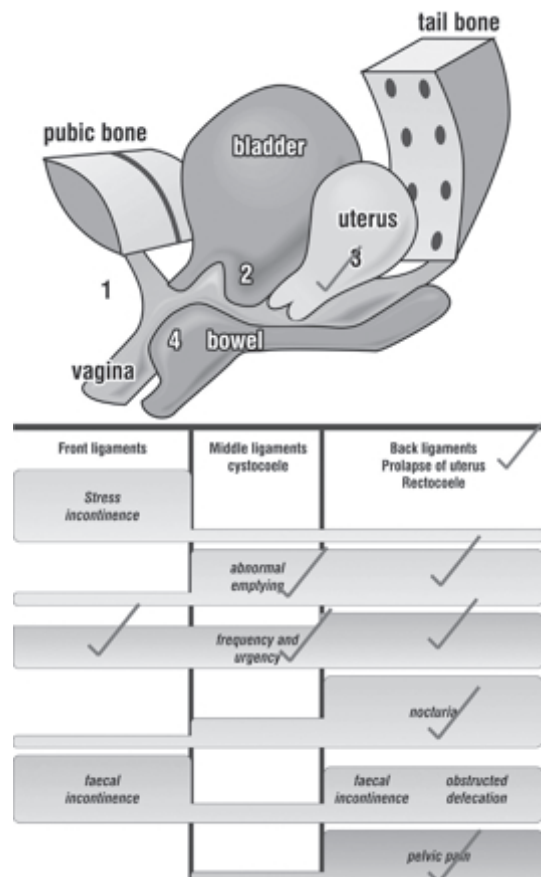


Fig. 29 - Posterior Zone Defect Ticks in the posterior column are typical for symptoms from damaged uterosacral ligaments. Ticks are inserted in all column for urge and emptying. Grouping of symptoms indicates either a middle or posterior defect. Absence of a cystocele on vaginal examination confirmed a posterior defect.

the muscle forces which stretch the vagina to support the nerves and volume receptors at bladder base. Loose tissues will not support the pain nerves, which “droop” and fire off, sending signals of pain to the brain. Like a trampoline with damaged springs, loose ligaments will not allow the muscles to stretch the vagina. The bladder nerves are unsupported, and fire off prematurely causing urge and frequency.

Pain during intercourse and bowel problems caused by posterior ligament looseness.

Mrs R M was a 47 year old para 2. She stated “I always have urgency to empty my bowel, but I am also frequently constipated. I get up 3-4 times a night to pass urine. I have problems emptying my bladder. My worst problem is that I can’t have sex any more. Almost every time I have intercourse, my bowels open.

Reference to her Diagnostic Diagram, fig. 29, indicated that most of Mrs RM’s bladder problems may have been caused by damaged posterior ligaments. On examination, however, there was very minimal prolapse. This was consistent with the Theory, which states that major symptoms may be caused by minimal prolapse, and a high rate of improvement (up to 80-%) was possible with a posterior sling. No predictions were made for the urge to empty her bowel, and her constipation. She was advised these could be due to many other causes, so we were reluctant to predict cure for these symptoms. A posterior TFS “minisling” was inserted to repair the posterior ligaments. Mrs RM was discharged the next day with very little pain, and she went to work the following week. She attended with her husband for the post-operative visit. Smiling and confident, she reported cure of all her bowel symptoms, and a major improvement in her other symptoms.

Comment on losing faeces during intercourse

This patient was a challenge to us, as some of her symptoms were not the typical symptoms seen in the Diagnostic Diagram. We had encountered women opening their bladder during intercourse before, but never their bowel. In such cases, we rely on the other typical symptoms to guide us as to which ligaments have been damaged, and on the guiding principle of this type of surgery, “repair the structure, and you will repair the function”.

Comment on pain with intercourse

Earlier we discussed how a loose ligament will not

support the pain fibres. As the penis thrusts into the posterior part of the vagina, it will cause pain if it stretches the unsupported nerve fibres.

Severe Pelvic pain caused by uterosacral ligament looseness.

Mrs D was a 34 year old para2. She attended with severe pain in the right side of her abdomen. Some years previously, she had previously attended a London hospital which had developed an international reputation using psychological tests to prove that such pain was psychological in origin.

Mrs D had read widely on the subject of pain. Her facial expression indicated a person who was guarded. Her face lit up after she answered positively to the following questions, as she knew, that we knew, what her problem was.

“Do you have pain on deep penetration with intercourse?

“Do you get up more than twice per night to pass urine?

“Do you have problems emptying your bladder?

“Do you have urgency?”

Positive answers to at least some symptoms other than pain are required before we can predict that the pain is caused by damage to the posterior ligaments. There are, after all, many other causes of chronic pelvic pain in the 30 plus age group, for example, endometriosis, infection in the Fallopian tubes, problems with large intestine, to name just a few.

This is what she said one week after her pain was cured by a small operation which tightened her posterior ligaments.²⁸

“I was almost suicidal after interminable attacks of pain on my right side. It has now been a week since the operation, and I feel like a rabbit that has been released from a trap.

My mind keeps scanning up and down my body searching for the pain which for so long has been my centre and focus.”

The operation, fig. 31, was simple, and it was performed entirely under local anaesthesia. A 3 cm incision was made in the vagina behind the cervix. Two sutures (green lines) were inserted to tighten the ligaments (white arrows).

Comment

This condition, severe pelvic pain caused by loose posterior ligaments, is still not well recognized by the majority of gynaecologists. The operation, fig. 31, unfortunately has a significant recovery rate, as it approximates damaged tissue to damaged tissue. Insertion of a polypropylene sling gave a higher symptomatic cure rate, by creating a collagenous reinforcement, better able to support the unmyelinated nerve endings.

Vulvodynia – pain and burning at the entrance to the vagina caused by posterior ligament looseness.

Mrs P was 49 years old para3 with chronic pelvic pain diagnosed as having a psychological cause. Her General Practitioner, an empathetic and caring man rang the doctor before she arrived, and asked that we “handle her very carefully”, as she was severely disturbed psychologically, that this was the reason for her pain, and “there was nothing anyone could do for her”. The first impression of this lady did indeed fit the description of her GP. Her face was contorted, she spoke rapidly and with obvious anxiety. She had visited many specialists over the years for her pain. She had undergone several diagnostic laparoscopies, even a hysterectomy, and had attended a pain clinic. None of these treatments had helped her pain. The consensus from other specialists as reported to the GP, was that her problem was psychological. Her replies to the questionnaire gave the first hint that this woman may have a physical cause for her problem, damage to her posterior ligaments. She woke 6 times per night to empty her bladder (nocturia), wore pads

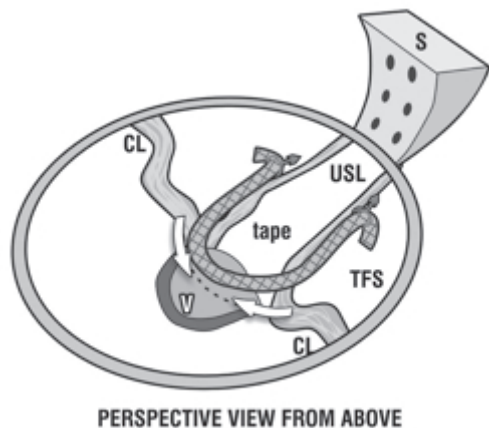


Fig 30 - The TFS posterior minisling repairs and tightens the posterior ligaments (arrows) without penetrating the skin of the buttocks.

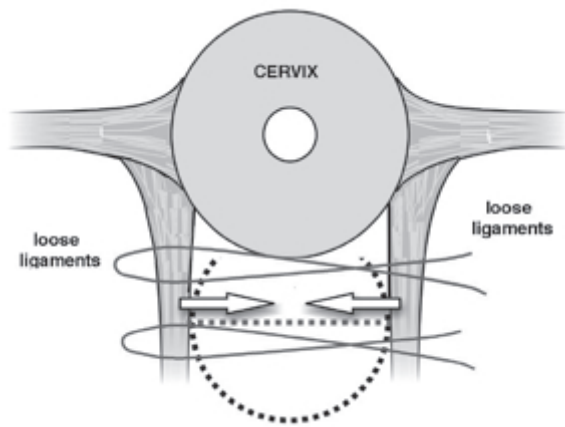


Fig. 31 - Approximation of uterosacral ligaments A small 3cm transverse incision into the vagina just below the cervix gave access for tightening her loose posterior ligaments (white arrows).

continually as she wet 6 times per day, and had difficulties emptying her bladder. She also had faecal incontinence. We asked her if she had told her General Practitioner about her bladder and bowel problems. She said she had only consulted him about the burning pain around her vagina and anus. She said that her vagina was so tender, that she couldn't have sexual intercourse, and sometimes had problems sitting. Examination revealed a prolapse of the posterior part of her vagina. The entrance to the vagina was hypersensitive- she recoiled when gently tested with a cotton bud, the classical test for "vulvodynia" (pain at the entrance of the vagina).

We did not claim that we could cure this lady's pain, as there are many other causes for pelvic pain. Nevertheless, it was explained that her vaginal prolapse needed to be fixed, and that there was a strong possibility that some of her symptoms would also improve with a sling inserted into the posterior part of her vagina, a fairly minor day-care procedure.^{29, 30}

The first thing we noticed at the 6 week post-operative visit was the absence of tension in her face. She was smiling and calm. Her pain was gone, as was her urgency and faecal incontinence. Her nocturia had reduced to 2 per night, and her bladder emptying was "60% improved".

A diagnosis that a patient's pain is of psychological origin is not entirely unreasonable. Any type of chronic pain is sufficient to unsettle even the most rational person, and such patients do become "psychologically disturbed". But this disturbance is usually secondary to the pain.

Comment

We do not claim that all vulvodynia patients have this causation. However, if other symptoms of posterior ligament looseness such as nocturia, abnormal bladder emptying, and urgency are grouped with the vulvodynia, there is a strong possibility that this pain can be improved in many patients with a posterior sling for repair of the posterior ligaments.

Hysterectomy for lower posterior ache and pelvic pain caused by posterior ligament looseness.

Mrs JMK developed chronic lower posterior pain and pain with intercourse after a difficult forceps delivery of her second child 50 years ago, when she was 27 years old. The pain worsened after the birth of her third child 3 years later. The pain was constant and debilitating, and she also had heavy menstrual bleeds. By the age of 35, the pain had worsened sufficiently to require consultation with a specialist gynaecologist. He told her that she needed to have

a hysterectomy. By the time Mrs JMK was 65 years old, the chronic pelvic pain and low abdominal ache had returned. She had developed prolapse of the vagina and bladder, with significant bladder symptoms, urgency and nocturia. The return of symptoms can be attributed to age-related loss of collagen, and weakening of the posterior ligaments, a long-term problem in patients who have had hysterectomy.

Abnormal emptying and chronic bladder infection caused by looseness in the posterior ligaments

Mrs KB, a 32 year para 0 flight attendant, had a long history of inability to empty her bladder, and chronic bladder infections, dating back to her teenage years. She came to us because the infections were becoming more frequent, and were affecting her ability to work on long flights. Her situation had reached a stage where she felt forced to consider leaving her profession. She was diagnosed as having congenitally weak posterior ligaments. She did not respond to our pelvic floor regime, and she requested surgical reconstruction of the ligaments. We agreed, having advised her that she may need a caesarian section if she fell pregnant, as any vaginal delivery could disrupt her operation. Her bladder returned to normal emptying immediately after the surgery, and she reported no further bladder infections even 10 years afterwards

Comment on abnormal bladder emptying in the younger woman Congenitally weak posterior ligaments must always be considered as a cause of abnormal bladder emptying in the younger woman, as these women do not generally have a cystocele. Increased difficulty in emptying the bladder at period time in such women is highly suggestive that the cause is looseness in the posterior ligaments. Other symptoms such as pelvic pain, urgency and nocturia are frequently present, and these may become worse during period time. Though not helpful with Mrs KB, good results in young women have been achieved at our Clinic by encouraging such patients to "squat" instead of bending, and to sit on a fitball at work instead of a chair. These exercises work by strengthening the pelvic muscles and ligaments.

An 87 year old woman not able to pass urine, requiring self-catheterisation caused by posterior ligament looseness.

There is a prevalence of this condition in Nursing Homes. Many patients require indwelling catheters.

Mrs R was 87 years old, and weighed 90kg. She had had a hysterectomy 40 years earlier. For some years she needed to self-catheterize 3-4 times a day, as she could not pass urine adequately. She had large residual volumes (the amount retained in the bladder after passing urine). On testing, we confirmed she also had severe incontinence, with a large measured urine loss over a 24 hour period. She had 3rd degree prolapse of the vagina. We inserted a posterior sling, performed a rectocele repair and perineal body repair. She passed urine immediately after the surgery. Her nocturia, previously 5 times per night, reduced to twice per night.

Comment on how age causes ligament looseness and bladder emptying difficulties

The tissues of the vagina and its supporting ligaments may loosen considerably with age. The effect of this is that many older women, especially those in Nursing Homes, cannot empty their bladder, and they require indwelling catheters. These catheters are a major cause of chronic cystitis, as they introduce bacteria. We have returned many women to normal micturition by reconstructing the posterior ligaments and tightening the neighbouring tissues.

Faecal incontinence, “constipation” and bleeding caused by posterior ligament looseness.

Mrs DMV, 63 year old para4, complained of a lump in the vagina. She had a 2nd degree prolapse of the uterus, urgency, and nocturia. She also had faecal incontinence, constipation, fig.32, and occasional bleeding from the bowel. She had been investigated for the bleeding by a specialist who found no evidence of bowel cancer. In the early days where the Diagnostic Algorithm was applied, we sometimes encountered patients with symptoms whose origin we did not fully understand. One example of this is the constipation, faecal incontinence and bleeding which had afflicted this lady. Faecal incontinence was not part of the Diagnostic Diagram at that time. In all such cases, we followed the principles of the Theory, “repair the structure, and you will improve the symptoms”. We repaired the prolapse of the uterus by reinforcing the posterior ligaments with a polypropylene sling. Mrs DMV had a good result. Her faecal incontinence was cured, her constipation improved, and her bleeding disappeared.^{31, 32}

Explanation for Mrs DMV’s improvement in her “constipation” and bleeding. The reason for improvement in this lady’s “constipation” and bleeding was discovered some years later by an Austrian colleague, Dr Abendstein.³¹ With reference to the diagram fig. 32, it is evident that the uterus, vagina, and rectum (bowel) are suspended by the uterosacral ligaments, like the apex of a tent. If the guy rope of the tent (posterior ligament) is loose, the wall of the vagina and rectum. It is difficult to have a normal bowel motion when the bowel walls are loose and sagging into the cavity of the bowel. Furthermore, the sagging wall of the rectum (bowel) caused congestion of the veins close to the cavity similar to what happens with a haemorrhoid. This congestion caused bleeding into the bowel cavity from time to time.

The tape lifted up and tightened the attachments of the uterus, vagina and rectum to the tail bone in the same way a guy rope does to the apex of a tent. This tightened the tissues, restored the function and improved her symptoms.

Bowel emptying problems cured by repair of posterior ligaments and perineal body

Mrs VCD, 46 years, presented with a rectocoele, faecal incontinence and difficulty with emptying her bowel, fig. 32. She stated, “every time I need to open my bowels, I have to press my fingers into the posterior wall of my vagina so I can empty. I find the necessary hygiene after completion quite unpleasant.” In Mrs VCD’s case, we found that her perineal body had been stretched very thinly, and the muscle bellies of this structure had been pushed to the side, allowing the rectocoele to protrude into the vagina as a sac containing faeces. That is why she had to press into the lower part of her vagina to facilitate evacuation.

Her posterior ligaments were repaired with a sling, and her perineal body was repaired in the traditional way, without a sling. The rectocoele and bowel evacuation difficulty were initially cured, but recurred within 6 months, as did requirement to assist evacuation by pressing her fingers into the posterior wall of her vagina. The faecal incontinence remained cured, and we attributed this to the continuing action of the posterior sling. The rectocoele and lax perineal body were repaired by the TFS (Tissue Fixation System) adjustable tape technique, fig. 33. Bowel evacuation returned to normal, and the rectocoele remained cured at her 2year review.

Comment Why a tape was necessary for repair of the perineal body There are really 2 perineal bodies joined together with a fibrous band. When these are

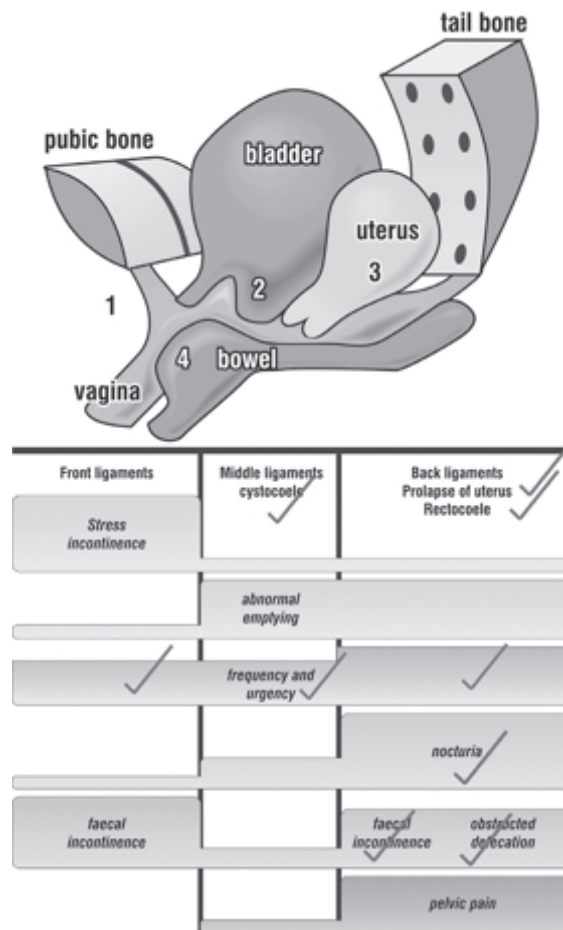


Fig. 32 - Posterior Zone Defect Difficulty with bowel evacuation in a patient with a large rectocoele indicates perineal body damage added to posterior ligament damage. Both needed to be repaired.

pushed aside by childbirth, the rectum protrudes into the vagina. The traditional method relies on suturing damaged tissue to damaged tissue under significant tension. This method is very painful, and is prone to recur. The TFS repair creates an artificial ligament to permanently join the laterally displaced bodies.

Urinary urgency, pelvic pain and nocturia cured by Pelvic Floor Exercises

Miss B, 31 years, gave this story. ‘I began to experience symptoms of urgency, pelvic pain and nocturia at the age of 25, sufficiently to seek medical advice. I saw 8 different specialists. I was given drugs to stop the bladder contracting. I spent a small fortune on herbal medicines. Nothing seemed to work’. Finally she contacted our Clinic through an intermediary. She worked overseas, and could not attend the Clinic for a formal assessment. We advised her how to use a large rubber fitball as a substitute for a chair, and to develop good pelvic floor habits such as squatting wherever possible, (instead of bending), erect posture, and exercise. The result was remarkable- virtually all her symptoms disappeared, and she remained cured at last contact 4 years later .

Comment Non-surgical treatment of posterior ligament symptoms A vast improvement in symptoms such as pelvic pain, urgency, abnormal emptying and nocturia has been achieved in many patients attending our Clinic, by the regime utilized by Miss B, in particular, substituting a “fitball” for a chair, and squatting instead of bending. This regime is especially effective in the younger woman.

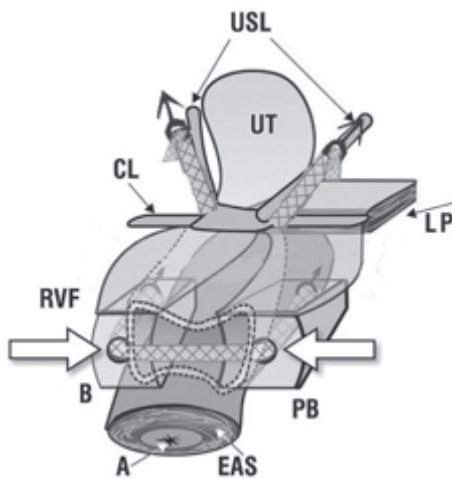


Fig. 33 - Large rectocele repair. Approximation of the perineal body (PB) and uterosacral ligaments (USL) by tightening the TFS, effectively blocks entry of the rectocele into the vagina. A=anus; RVF=rectovaginal fascia; CL=cardinal ligament.

Permission to publish

The Editors grant permission for any individual, group or company to reproduce any text or document in this series of articles, with the sole condition that this article is quoted as a literature reference, and any diagram is appropriately acknowledged in the text.

REFERENCES

- Petros P E, Ulmsten U. An Integral Theory of female urinary incontinence. Acta Obstetricia et Gynecologica Scandinavica, 1990; Supplement 153, 69: 1-79.
- Petros P E, Ulmsten U. An Integral Theory and its Method, for the Diagnosis and Management of female urinary incontinence, Scandinavian Journal of Urology and Nephrology 1993; 27 Supplement No 153 – 1-93.
- Petros P E, The International Continence Society and Integral Theory systems for management of the incontinent female -a comparative analysis. Pelviperineology 2007; 26: 25-29.
- Petros P E, Ulmsten U, Papadimitriou J. The Autogenic Neoligament procedure: A technique for planned formation of an artificial neo-ligament. Acta Obstetricia et Gynecologica Scandinavica. 199; Supplement 153, 69: 43-51.
- Petros PE, New ambulatory surgical methods using an anatomical classification of urinary dysfunction improve stress, urge, and abnormal emptying, Int. J. Urogynecology 1997; 8: 270-278.
- Petros PE, Influence of hysterectomy on pelvic floor dysfunction, Lancet 2000; 356: 1275.
- Petros P E, Ulmsten U. Role of the pelvic floor in bladder neck opening and closure: I muscle forces, Int. J. Urogynecol. and Pelvic Floor, 1997; 18: 74-80.
- Petros P E, Ulmsten U, Role of the pelvic floor in bladder neck opening and closure: II vagina. Int. J. Urogynecol. and Pelvic Floor, 1997; 8: 69-73.
- Petros PE, Swash M. The Musculoelastic Theory of anorectal function and dysfunction. Pelviperineology, 2008; 27: 89-93.
- Petros PE, Swash M. Directional muscle forces activate anorectal continence and defecation in the female, Pelviperineology 2008; 27: 94-97.
- Petros PE, Swash M.A. Direct test for the role of the pubourethral ligament in anorectal closure. Pelviperineology 2008; 27: 98.
- Petros PE, Swash M. Reflex contraction of the levator plate increases intra-anal pressure, validating its role in continence. Pelviperineology 2008; 27: 99.
- Petros PE, Swash M. Abdominal pressure increase during anorectal closure is secondary to striated pelvic muscle contraction. Pelviperineology, 2008; 27:100-101.
- Petros PE, Swash M. A prospective endoanal ultrasound study suggests that internal anal sphincter damage is unlikely to be a

major cause of fecal incontinence. Pelviperineology 2008; 27: 102.

- Petros PE, Swash M. Correction of abnormal geometry and dysfunction by suspensory ligament reconstruction gives insights into mechanisms for anorectal angle formation. Pelviperineology 2008; 27:103-104.
- Petros PE, Swash M. Role of puborectalis muscle in anal continence- comments on original 4D pelvic ultrasound data from Chantarasorn & Dietz. Pelviperineology, 2008; 27;105.
- Petros PE, Swash M, Kakulas B. Stress urinary incontinence results from muscle weakness and ligamentous laxity in the pelvic floor. Pelviperineology 2008; 27:107-109.
- Rechberger T, Uldbjerg N & Oxlund H. Connective tissue changes in the cervix during normal pregnancy and pregnancy complicated by a cervical incompetence Obstets & Gynecol. 1988; 71:563-567.
- Petros PE and Skilling PM. Pelvic floor rehabilitation according to the Integral Theory of Female Urinary Incontinence- First report, European J Obstetric & Gynecology and Reproductive Biology 2001; 94: 264-269.
- Petros PE and Skilling PM. The physiological basis of pelvic floor exercises in the treatment of stress urinary incontinence. Br J Obstet Gynaecol 1999;106 :615-616.
- Skilling PM, Petros PE. Synergistic non-surgical management of pelvic floor dysfunction: second report. Int J Urogyne 2004; 15: 106-110.
- Abendstein B, Petros PE, Richardson PA. Ligamentous repair using the Tissue Fixation System confirms a causal link between damaged suspensory ligaments and urinary and fecal incontinence. Pelviperineology 2008; 27: 114-117.
- Sivaslioglu AA, Unlubilgin E, Aydogmus S, Celen E, Dolen I. A Prospective Randomized Comparison of Transobturator Tape and Tissue Fixation System Minisling in the Treatment of Female Stress Urinary Incontinence: 3 Year Results, 2010, J. Pelviperineology (in press).
- Sekiguchi Y, Kinjyo M, Inoue H, Sakata H, and Kubota Y. Outpatient mid urethral tissue fixation system sling for urodynamic stress urinary incontinence, The Journal of Urology 2009; 182:2810-3.
- Petros PE Richardson PA. A 3 year follow-up review of uterine/vault prolapse repair using the TFS minisling. ANZJOG 2009; 49: 439-440.
- Inoue H, Sekiguchi Y, Kohata Y, SatonoY, HishikawaK, TominagaT, and Oobayashi M. Tissue Fixation System (TFS) to repair uterovaginal prolapse with uterine preservation: A preliminary report on perioperative complications and safety J. Obstet. Gynaecol. Res. 2009; 35: 346-353.
- Hocking I. Experimental Study No. 9: Double incontinence, urinary and fecal, cured by surgical reinforcement of the pubourethral ligaments. Pelviperineology 2008; 27:110.
- Petros PE. Severe chronic pelvic pain in women may be caused by ligamentous laxity in the posterior fornix of the vagina, Aust NZ J Obstet Gynaecol. 1996; 36: 351-354.
- Petros PE and Bornstein J. Vulvar vestibulitis may be a referred pain arising from laxity in the uterosacral ligaments-a hypothesis based on 3 prospective case reports. ANZJO&G, 2004; 44: 483-486.
- Bornstein J, Zarfati, D, Petros PEP. Causation of vulvar vestibulitis ANZJOG 2005; 45: 538-541.
- Abendstein B, Brugger BA, Furtschegger A, Rieger M, Petros PE, Role of the uterosacral ligaments in the causation of rectal intussusception, abnormal bowel emptying, and fecal incontinence- a prospective study. Pelviperineology 2008; 27;118-121.
- Petros PE, Richardson PA. Fecal incontinence cure by surgical reinforcement of the pelvic ligaments suggests a connective tissue aetiology. Pelviperineology 2008; 27: 111-113.

Correspondence to:

Professor Peter Petros
14A Osborne Pde - Claremont - WA 6010 - Australia
Tel No : M 61-411 181 731
Fax : 61-89-384 0176
Email: kvinno@highway1.com.au

TFS posterior sling improves overactive bladder, pelvic pain and abnormal emptying, even with minor prolapse.

A prospective urodynamic study

PETER PETROS⁽¹⁾, PETER A. RICHARDSON⁽²⁾

⁽¹⁾ University of Western Australia

⁽²⁾ Gallier's Hospital, Armadale, Western Australia

Abstract: OBJECTIVE To prospectively challenge the Integral Theory's predictions that female patients with even with minor degrees of prolapse, and who have a symptomatic overactive bladder (urgency, nocturia and frequency), are surgically curable with uterosacral ligament repair. METHODS The study group comprised 67 patients with >2nd degree prolapse, with a subgroup of 27 symptomatic patients with only 1st degree prolapse. All patients were assessed pre and post-operatively by questionnaire, 24-hr urinary diary, transperineal ultrasound, urodynamics, cough stress and 24-hr pad test. Uterine/apical prolapse were repaired as a day case using the TFS. The TFS ('Tissue Fixation System') comprises an adjustable polypropylene 'mini sling' applied entirely per vagina, and which can be accurately tightened to reinforce loose or damaged pelvic ligaments. RESULTS: At median 9 months' review, the percentage improvement rate in pre-operative dysfunctions for the total group is expressed as a percentage, with 1st degree in parenthesis: urinary frequency >10/day 63% (63%); nocturia >2/night 83% (76%); urge-incontinence >2/day 78% (76%); abnormal emptying, 73% (73%); pelvic pain, 86% (82%) fecal incontinence, 87% (100%). CONCLUSIONS: The posterior TFS sling is a promising minisling technique which appears to address symptoms such as urgency, nocturia, frequency, abnormal bladder emptying, and fecal incontinence, even in patients with minimal uterovaginal prolapse.

Key words: TFS; Integral Theory; urge incontinence; overactive bladder; nocturia; pelvic pain; fecal incontinence.

INTRODUCTION

In the 1993 publication of the Integral Theory of Female Urinary Incontinence, the "posterior fornix syndrome" (posterior zone, figure 1) was described. It comprised symptoms of frequency, urgency, nocturia, pelvic pain, and abnormal bladder emptying.¹ Causation of this grouping of symptoms was attributed to laxity in the uterosacral ligaments (USL). According to this Theory,¹ the anatomical rationale for symptom causation was that lax posterior ligaments prevented the posterior muscle forces from stretching the vaginal membrane to support the bladder base stretch receptors, "trampoline analogy", fig. 1. Fundamental to this mechanism is the Theory's interpretation of "Overactive Bladder" (OAB) as a prematurely activated, but otherwise normal micturition reflex. This was urodynamically demonstrated in 1993.² Significant improvement in such "posterior fornix" symptoms in patients with 2nd degree or greater prolapse following reinforcement of USLs with a posterior sling operation has been reported previously.^{3,4} More recently, a less invasive posterior sling using the Tissue Fixation System (TFS) was described,⁵ fig. 2. The TFS allows precise tensioning of ligaments and fascia, consistent with the trampoline concept, fig. 1. There were 2 aims to this study. The primary aim was to challenge the theory's prediction¹ that even a 1st degree prolapse could cause major symptoms of urgency, nocturia and abnormal emptying. Twenty-eight patients fitted this description. A secondary aim was to test the efficacy of the new TFS sling in curing these conditions.

PATIENTS AND METHODS

Ethics Committee and Dept of Surgery Royal Perth Hospital approvals were obtained prior to the study.

Pre-operative assessment

All patients completed a 24 hour urinary diary, and a self-administered questionnaire which was completed at home in the patient's own time.⁶ A cough stress test, and 24 hour pad test⁶ were also administered. Symptoms derived from the questionnaire were ticked off in a diagnostic algorithm,

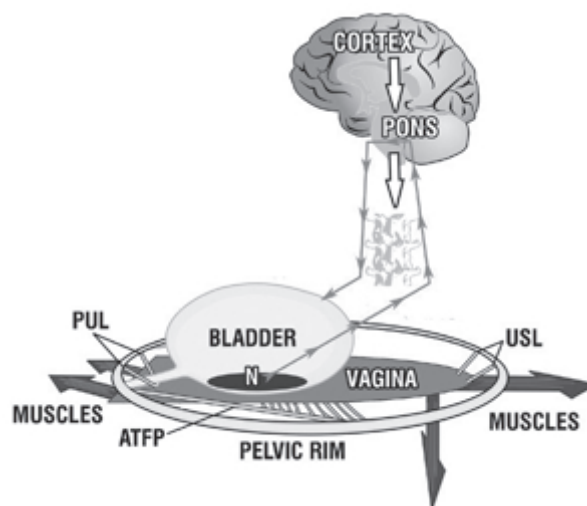


Fig. 1. – The Trampoline Analogy for OAB. Schematic representation. Muscle forces contract against the suspensory ligaments ("trampoline springs") to stretch the vaginal membrane. Even damage to one ligament may prevent the trampoline membrane from stretching. A lax vaginal membrane may not be able to support sensitive stretch receptors "N", so that these activate the micturition reflex prematurely. The patient senses this as urgency and frequency, and at night, nocturia. Minor damage may cause urgency, as this symptom is neurologically determined. Uterosacral ligaments (USL); pubourethral ligaments (PUL); Arcus Tendineus Fascia Pelvis (ATFP).

indicating the zone of connective tissue damage, anterior, middle, posterior. In this classification,⁷ the anterior zone extends from the external urethral meatus to bladder neck, the middle zone 4 from bladder neck to cervix or hysterectomy scar, and the posterior zone from apex to perineal body. Only patients with posterior zone defects were included in the study.

Inclusion/exclusion criteria

There were no exclusion criteria. The principal inclusion criterion for surgery was patients with 2 or more symptoms

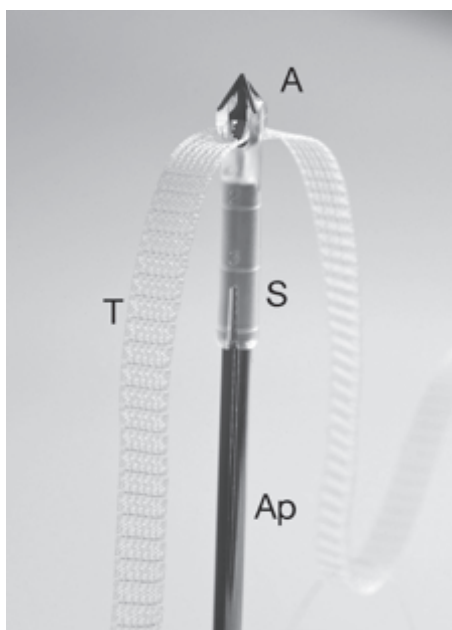


Fig. 2. – The Tissue Fixation System – a tensioned minisling. This is a photograph of the TFS anchor “A”, which sits in a saddle “S”, on an applicator “Ap”. T is a monofilament macropore polypropylene tape.

of urgency, frequency, nocturia, abnormal emptying or pelvic pain. Of the 67 patients who underwent surgery, 28 had only 1st degree prolapse, plus symptoms such as urgency, nocturia or pelvic pain. Without symptoms, none of these patients would normally have been considered for surgery. The criteria for symptomatic improvement post-operatively are detailed below: nocturia: change in patients having >2 episodes per night; abnormal emptying: self-assessed improvement >80%, using a 0-100 scale expressed as a percentage; urge incontinence: change in the number of times a patient wet per day (threshold 2/day); frequency: change in patients having >10 episodes per day; pelvic pain and fecal incontinence: self-assessed improvement >85%, using a 0-100 scale expressed as a percentage; otherwise objective measures such as pad weights and residual urine measured by catheter were used.

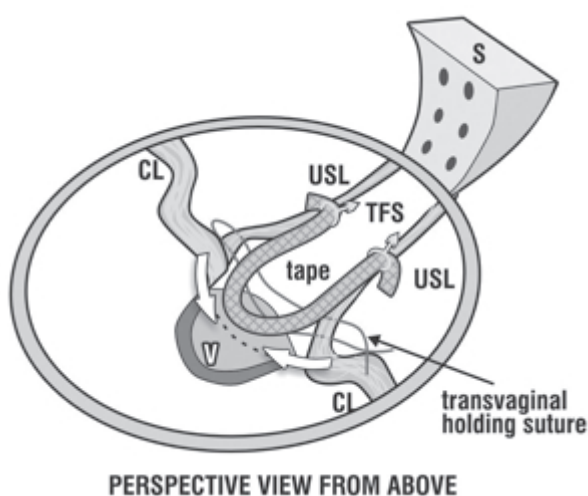


Fig. 3. – Posterior TFS sling. Perspective: View from above. The TFS anchors were inserted into the Uterosacral Ligaments (USL), and tightened to reduce apical or uterine prolapse. The arrows indicate that the remnants of USL and also the cardinal ligaments (CL) need to be approximated if the apex is wide, so as to prevent enterocele formation. Figure from Pelviperineology, by permission.

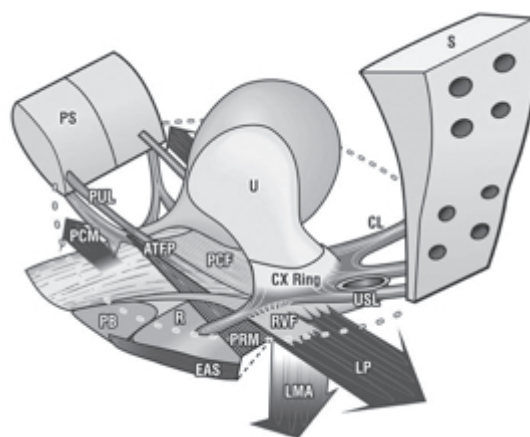


Fig. 4. – In its simplest form, anorectal closure occurs when the backward muscle forces LP (levator plate) and LMA (longitudinal muscle of the anus)¹⁵ stretch the rectum like a rubber tube, around an anus anchored by m.puborectalis (PRM) contraction. On relaxation of PRM, LP/LMA vectors open out the anal canal for evacuation to occur (broken lines). The vector forces, LP/LMA contract against the uterosacral ligaments (USL). If USLs are loose, the closure mechanism is invalidated, and fecal incontinence may result. Figure from Pelviperineology, by permission.

Objective assessment

Vaginal examination,⁷ involved inspection for damage to perineal body, posterior vaginal wall (rectovaginal fascia), and for the degree of prolapse of the vaginal vault or uterus. Transperineal ultrasound was performed by PP with a Toshiba 3.5 Mhz curvilinear probe to check organ position at rest and straining. Urodynamic testing was performed with a Neomedix System using Gaeltec microtransducers to assess for maximal urethral closure pressure, flow, residual urine, and ‘overactive bladder’. The patients were monitored at 6 weeks, and at 3 monthly intervals thereafter using a 24 hour urinary diary, structured self-administered questionnaire, cough stress test, 24 hour pad test, transperineal ultrasound, and urodynamic investigation. Residual urine was assessed by catheter after the patient had voided.

Surgical technique

The posterior TFS sling consists of two polypropylene soft tissue anchors through which is inserted an adjustable polypropylene tape, fig. 2. A transverse full thickness vaginal incision was made 1cm below the hysterectomy scar, or cervical ring. The uterosacral ligament was identified with Allis forceps. A 4-5 cm channel was dissected immediately lateral to the uterosacral ligaments. Using a special applicator, the TFS anchors were inserted into the uterosacral ligaments, fig. 3. The tape was tightened via a one-way system at the base to reduce apical or uterine prolapse, figure 3. Coexisting rectocele was repaired in 5 in 18 patients without vaginal tissue excision.

The halfway classification system of Baden & Walker was used to classify apical or uterine prolapse: first degree descent to halfway along the posterior vaginal wall ($n = 28$), second degree almost to the introitus ($n = 20$), third degree to 2 cm beyond the introitus ($n = 17$), and fourth degree total eversion ($n = 2$).

RESULTS

A total of 67 posterior TFS operations were performed. The median age of the women was 65 years (range 35–87). Median parity was 3 (range 0–8), and median weight was 71 kg (range 38–117 kg). Of the 67 patients, 28 had only 1st degree prolapse, and 39 had 2nd degree or greater prolapse.

TABLE 1. – Symptom Outcome - 67 patients.

	Symptom change with surgery			% cure in brackets	
	Frequency >10/Day	Nocturia >2/night	Urge incontinence >2/Day	Abnormal emptying	Pelvic pain
Fecal Incontinence	n=23 (87%)	n=47 (83%)	n=36 (78%)	n=53 (73%)	n=46 (86%)
	P<0.005	P<0.005	P<0.005	P<0.005	P<0.005

TABLE 2. – Symptom Outcome - 1st degree vault/uterine prolapse (n=28).

	Symptom change with surgery			% cure in brackets	
	Frequency >10/Day	Nocturia >2/night	Urge incontinence >2/Day	Abnormal emptying	Pelvic pain
Fecal Incontinence	n=8 (100%)	n=17 (76%)	n=17 (76%)	n=19 (73%)	n=18 (82%)

TABLE 3. – Pre-operative urodynamic “Overactive Bladder”

Patient	1	2	3	4	5	6	7	8
Pre-op 24 hr pad test (gm)	7	14.3	6.5	272	522	910	2100	644
Post-op 24 hr pad test (gm)	0	0	0	70	20	13	*1980	720

*asterisk indicates detrusor instability post-operatively also

The mean number of previous incontinence or vaginal repair operations was 1.6 per patient (range 0–6 operations). Only 15 patients had not had prior incontinence or vaginal surgery. Forty patients (56%) had undergone prior hysterectomy.

Mean hospital stay was 1.5 days (1–3 days). One patient was lost to follow-up.

The median post-operative review time was 9 months. The operation results are summarized in Tables I-III. Because the indication for surgery in the 28 patients with major symptoms but only 1st degree prolapse is likely to be highly controversial, the results are presented separately in Table II. For similar reasons, the surgical results for patients with pre-operative urodynamic ‘Overactive Bladder’ are presented separately in Table III. There was one recurrence of prolapse.

Severe urge incontinence

Seventeen patients had severe urge incontinence (UI), with a mean loss of 215gm/24 hour pad test (range 20 gm-644 gm). Post-operatively, 10 of these 17 patients stated they were >95% cured with a mean 24 hour loss of 6gm (range 0- 12gm). The results were significant (p=<0.05, Student’s 2 tailed t test). In the other 7 patients from this group of 17 with OAB who were not considered cured of their symptoms, mean 24 hour loss reduced from 320 gm (range 25- 388gm.) to 223 gm (range 35-720 gm), 4 of these 7 patients were cured of nocturia, 3 of daytime frequency, and 6 of other symptoms such as fecal incontinence, pelvic pain and abnormal emptying.

Urodynamically diagnosed Overactive Bladder (OAB) with significant urine loss

Fifty eight patients underwent urodynamic testing pre-operatively, and 55 postoperatively. There were 8 cases of ‘overactive bladder’, ‘OAB’, as defined by the International Continence Society⁸ associated with significant urine loss, Table III. Five of these 8 patients considered themselves more than 95% cured, and a sixth more than 80% cured

(mean change from 288gm –17gm). Two reported no improvement at all.

Abnormal emptying and residual urine

A residual urine >50ml (50-600 ml) was seen in 6 out of 29 patients. In this group, the mean reduction of residual urine was from 271ml preoperatively to 53ml post-operatively (p<0.005). One patient who self-catheterized 4 times daily pre-operatively, was restored to normal emptying. Mean emptying time for this group (n=29) decreased from mean 41 seconds (12-130 secs) to 31 seconds. (7-130 secs) (p <0.005). There was no significant change in peak flow (41ml/sec pre-operatively to 37ml/sec post-operatively).

Prolapse repair

There was one failure of vault prolapse repair which required reoperation.

In another patient, one half of the sling was found in the vagina covered by a large granuloma, with no vault prolapse, and no posterior zone symptoms, figure 1. The prolapsed part of the sling was excised and the vagina sutured. Symptom cure was maintained.

DISCUSSION

At least in the short term, the posterior TFS sling appears to improve symptoms of urge-incontinence, frequency, nocturia, pelvic pain and voiding problems, similarly to previous methods, uterosacral ligament repair,¹ posterior IVS,^{3,4,9} sacrocolpopexy.¹⁰

Whereas all previous reports concerned patients with at least 2nd degree prolapse, 28 of our patients had only 1st degree prolapse. We attribute the effectiveness of the TFS in such 1st degree patients to its ability to tension the vaginal membrane through its one way tensioning system, supporting the stretch receptors according to the “Trampoline Analogy”. The stretch receptors “N” fig. 1 predicted by the theory,¹ and on which this explanation is based, are consistent with the recently described Transient Receptor Potential channels, “TRPs” which are found in the bladder epithelium.¹¹ These function as stretch, volume and pain receptors.¹¹

“Overactive Bladder”

Significant improvement in 10/17 patients with severe urge incontinence, and 6/8 patients with symptomatic “Overactive Bladder” in this study, accords with the explanation of OAB as a normal micturition reflex² prematurely activated by a lax vaginal membrane, fig1. Neuman⁹ also found that “overactive bladder” symptoms in non-neurological patient with uterine/apical prolapse may be potentially curable surgically. In a study of 140 patients who had a posterior sling operation (“Posterior IVS”-PIVS), Neuman et al⁹ reported troublesome bladder overactivity symptoms in 90 of the patients, reduced postoperatively to 9 patients, a 90% cure rate.

Pelvic pain

With regard to symptomatic improvement in pelvic pain, it is proposed that competent connective tissue in the uterosacral ligaments provides intrinsic support to the unmyelinated nerve endings which they contain.⁷ Lax ligaments “sag” due to the action of the force of gravity. The nerves are activated, and this is perceived as ‘dragging’ lower abdominal pain.⁷

Even patients considered as gross failures in one area (e.g., urge incontinence) had cures in other symptoms (e.g., fecal incontinence, stress incontinence, nocturia, frequency). This suggests a complex synergistic interaction of structures which we can describe, but not explain.

Fecal incontinence

Utilizing pre and postoperative evacuating proctograms, Abendstein¹² reported cure of fecal incontinence, obstructive defecation, pelvic pain, and xray proven anterior rectal wall intussusception. Abendstein proposed that the uterosacral ligament supports the anterior rectal wall much like the apex of a tent. The mechanism proposed for cure of fecal incontinence also involves the uterosacral ligaments.¹³ The longitudinal muscle of the anus (LMA) and levator plate (LP) vectors stretch the rectum around an anus anchored by forward contraction of the puborectalis muscle (PRM), figure 4. Laxity in the uterosacral ligaments (USL), the anchoring point of LMA, may inactivate this closure mechanism causing fecal incontinence.¹³ In a study similar to that of Abendstein, it was demonstrated that in patients with fecal incontinence, abnormal anorectal pressures, delayed pudendal nerve conduction times, and thinned internal anal sphincters had no negative impact on the results of surgery.¹⁴ Fecal incontinence was cured in 83% of patients by repair of the uterosacral and/or pubourethral ligaments.

CONCLUSIONS

The posterior TFS sling is a promising minisling technique which appears to address symptoms such as urgency, nocturia, frequency, abnormal emptying, and fecal incontinence, even in patients with minimal uterovaginal prolapse.

REFERENCES

1. Petros PE, Ulmsten U. An Integral Theory and its Method for Diagnosis and Management of Female Urinary Incontinence. *Scand J Urol Nephrol.* 1993; 27 (Suppl. No 153, 1-93.
2. Petros PE & Ulmsten U. Bladder instability in women: A premature activation of the micturition reflex. *Neurourology and Urodynamics* 1993;12: 235-239.
3. Petros PE. New ambulatory surgical methods using an anatomical classification of urinary dysfunction improve stress, urge and abnormal emptying. *Int Urogynecol J.* 1997; 8:270-7.
4. Farnsworth BN. Posterior intravaginal slingplasty (infracoccygeal sacropexy) for severe posthysterectomy vaginal vault prolapse, a preliminary report on efficacy and safety. *Int Urogynecol J.* 2002; 13:4-8.
- 5.- Petros PEP, Richardson PA, The midurethral TFS sling- a 'micro-method' for cure of stress incontinence- preliminary report AANZJOG; 2005; 45: 372-375.
6. Petros PEP, Appendix , in *The Female Pelvic Floor, Function, Dysfunction and Management, according to the Integral Theory*, 2nd edition, Springer Heidelberg: 2006; 194-199.
7. Petros PEP, Ch 2-4, *Dynamic Anatomy, Diagnosis of Connective Tissue damage, Surgery, in The Female Pelvic Floor, Function, Dysfunction and Management, according to the Integral Theory*, 2nd edition, Springer Heidelberg. 2006; 48-138.
8. Abrams P, Blaivas J, Stanton S and Andersen J. Standardisation of Terminology of Lower Urinary Tract Function. *Scand J. Urol Nephrol.*, 1988; Suppl.No 114, 1- 25.
9. Neuman M, Lavy Y, Posterior Intra-Vaginal Slingplasty (PIVS) for the treatment of vaginal apex prolapse: medium term results of the 140 operations with a novel procedure. *Eur J Obstet Gynecol Reprod Biol.* 2008;140:230-3.
10. Pilsgaard K, Mouritsen L. Follow-up after repair of vaginal vault prolapse with abdominal colposacropexy. *Acta Obstet Gynecol Scand.* 1999; 78:66-70.
11. Everaerts W, Gevaert T, Nilius B, De Ridder D, On the Origin of Bladder Sensing: Tr(i)ps in urology, *Nerourol. Urodynam.* 2008; 27:264-273.
12. Abendstein B, Brugger BA, Furtschegger A, Rieger M . Role of the uterosacral ligaments in the causation of rectal intussusception, abnormal bowel emptying, and fecal incontinence-a prospective study. *Pelviperineology*, 2008; 27: 118-121.
13. Petros PE, Swash M The Musculoelastic Theory of anorectal function and dysfunction, *J. Pelviperineology.* 2008; 27: 89-93.
14. Petros PE, Richardson PA Fecal incontinence cure by surgical reinforcement of the pelvic ligaments suggests a connective tissue aetiology. *Pelviperineology* 2008; 27:111-113.
15. Macchi V, Porzionato A, Stecco C, Benettazzo F, Stecco A, Parenti A, Dodi G, De Caro R, Histo-topographic study of the longitudinal anal muscle. *Pelviperineology.* 2007; 26: 30-32.

Correspondence to:

Professor Peter Petros
14A Osborne Pde - Claremont
WA 6010 - Australia
Tel No : M 61-411 181 731
Fax : 61-89-384 0176
E-mail: kvinno@highway1.com.au

A prospective randomized controlled trial of the transobturator tape and tissue fixation system minisling in 80 patient with stress urinary incontinence - 3 year results

A. AKIN SIVASLIOGLU⁽¹⁾, EYLEM UNLUBILGIN⁽²⁾
SERPIL AYDOGMUS⁽¹⁾, EMINE CELEN⁽¹⁾, ISMAIL DOLEN⁽²⁾

⁽¹⁾ Ankara Atatürk Education and Research Hospital, Clinic of Gynecology and Obstetrics, Urogynecology Division, Turkey

⁽²⁾ Ankara Zubeyde Hanım Women's and Maternity Teaching and Research Hospital, Clinic of Urogynecology, Turkey

Abstract: INTRODUCTION: We aimed to perform a randomised controlled trial (RCT) comparing the efficiency of transobturator tape (TOT) operation against an adjustable minisling, the tissue fixation system (TFS), in the treatment of urodynamically proven stress urinary incontinence. METHODS: The trial comprised 80 patients with urodynamically proven stress urinary incontinence. The patients were randomly allocated to either TOT group (group I) or TFS group (group II). Total follow period was 36 months. The objective cure rates in TFS group and TOT group were 90% and 84%, respectively, and the difference was statistically significant ($p < 0.05$). Operation time: 5 ± 1 min in TFS group, 12 ± 1 in TFS group ($p < 0.05$). Postoperative groin pain was significantly high in TOT group (12 patients). Both operations had positive effects on the quality of life (QoL) measures.

CONCLUSION: The TFS showed better objective outcomes in comparison to TOT.

Key words: Minisling, tissue fixation system, transobturator tape

INTRODUCTION

In 1990 Petros & Ulmsten described a prototype intravaginal slingplasty operation, later known as the "TVT", which was based on their "Integral Theory"¹. A Mersilene tape was inserted below the midurethra, exiting unattached through the lower abdominal muscles. Post-operative xrays demonstrated no change in the position of bladder neck in patients cured of their SI, thereby invalidating the pressure transmission theory². This method was revolutionary in that it was a minimally invasive day-care operation, with minimal pain and no significant post-operative urinary retention. However, scattered reports of small bowel and external iliac artery perforations, albeit infrequent, were major causes of concern, inviting calls for zero tolerance for such surgery³. Delorme's transobturator (TOT) approach to the midurethral sling in 2001 significantly decreased such complications with an almost equivalent cure rate⁴. However, the TOT was subject to its own major complications, such as obturator nerve and artery damage, groin pain, even bladder perforation. Though infrequent, these complications were cause for concern. In 2005, the 1st midurethral minisling sling, the Tissue Fixation System (TFS) was described in a preliminary report⁵. A polypropylene sling was inserted below the midurethra entirely per vaginam, without entry to the retropubic or obturator space, without the need for cystoscopy, and with minimal post-operative pain.

The Urogynecology clinic of Ankara Etlik Zubeyde Hanım Women's and Maternity Research Hospital, Turkey performed the TFS minisling soon after the first report in 2005⁶.

Our aim was to compare the efficacy of the TFS and TOT in a prospective randomized control study (RCT) in a group of patients who had urodynamically proven SUI.

MATERIALS AND METHODS

This single blind prospective randomized controlled trial was carried out in the urogynecology clinic of Ankara Etlik Zubeyde Hanım Women's and Maternity Training and Research Hospital, Turkey. All operations were undertaken between September 2005-September 2006. The study comprised 80 patients with only urodynamically proven stress urinary incontinence cases. The cases were randomly

allocated for TOT (group I) or TFS operation (group II) according to a computer generated programme. Each group consisted of 40 patients. Two patients in TOT group and 1 patient in TFS group lost follow up and these patient were not included in the study. The study flow chart has been given in figure 1.

The patients were evaluated with a full clinical history, a validated incontinence impact questionnaire 7 (IIQ 7), pelvic and urogynecologic examination, pelvic ultrasound, cough stress pad test (CSPT) and urodynamics before and after the operations.

Supine cough stress pad test (CSPT).

A preweighed pad was placed on the vulva. The patient coughed 10 times with a full bladder, the pad was reweighed and the increased amount is noticed as leaked urine. A urine loss greater than 1 gm was regarded as positive for stress incontinence (SI), and a loss less than 1 gm as a negative result (no SI).

Inclusion criteria were 1) patients with genuine stress incontinence (GSI) with a Valsalva leak point pressure (VLPP) less than 60 cm H₂O⁷, 2) patients treated surgically for the first time for stress urinary incontinence, 3) patients who failed to respond to conservative management as physiotherapy or drugs.

Exclusion criteria were 1) overflow incontinence, 2) neurological lesions, 3) overactive bladder, 4) transient causes of urinary incontinence such as urinary tract infection, 5) pure urge incontinence, 6) mixed incontinence, 7) patients with previous surgery for the correction of urinary incontinence.

All patients participated to the study after informed consents had been taken and the local ethics committee of the hospital accepted the study.

All operations were performed by the first author after the accomplishment of 10 previous TFS surgeries for learning curve. The author already had a wide experience in TOT incontinence surgery.

Surgery

Surgery was performed in the lithotomy position, with legs placed in stirrups. All patients received preoperative antibiotic prophylaxis, 1 gm intravenous cephazolin. The standard "outside in" method was used for the TOT, with

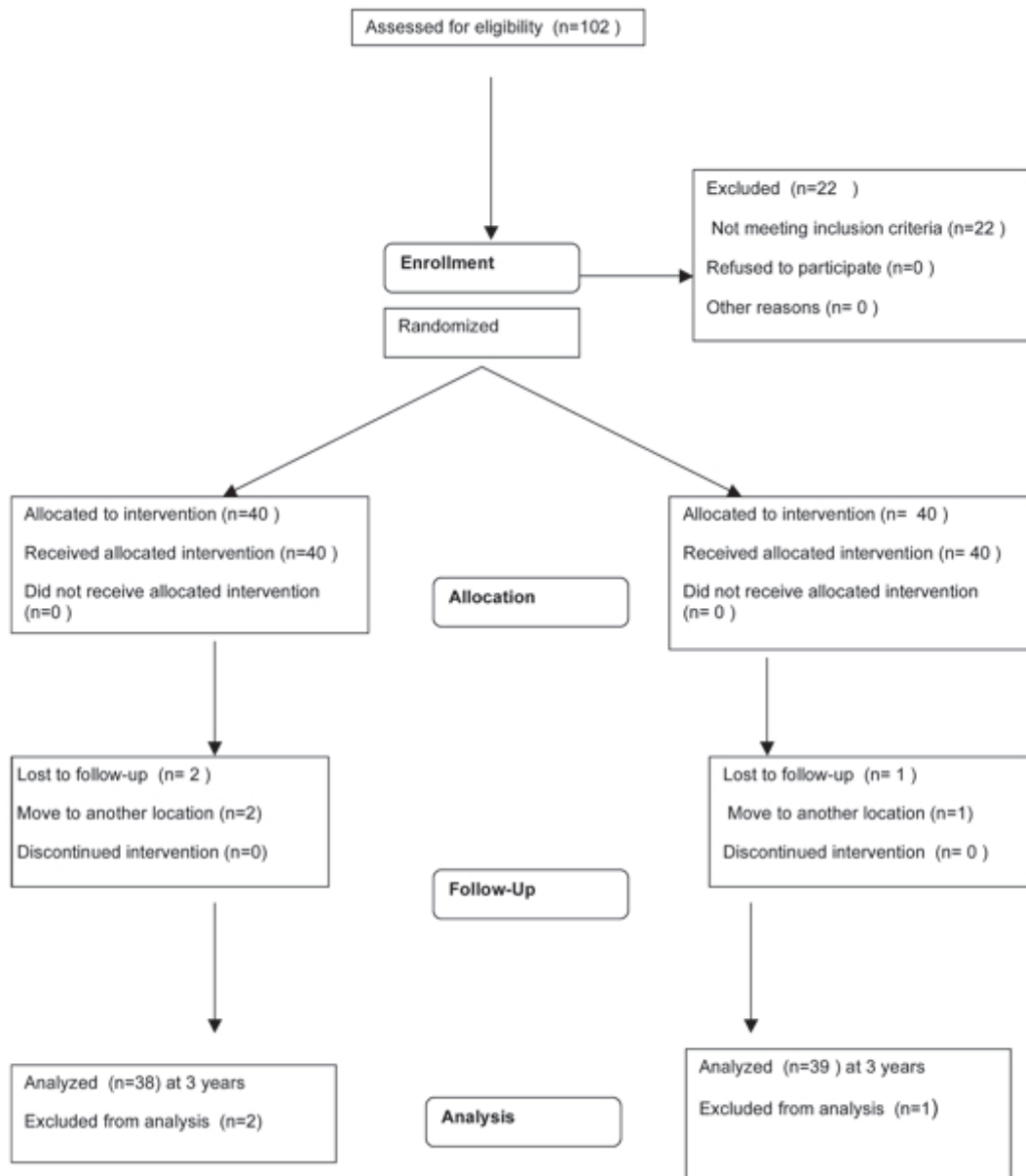


Fig. 1. – Study flow chart.

the tape inserted at the level of the clitoris. The TFS (TFS Surgical Adelaide SA) consists of two anchors attached to an adjustable sling (fig.2). It consists of an 11mm X 4mm anchor with 4 prongs, with a one-way trapdoor at its base which allows tightening of the laterally displaced fascia. The tape is macroporous, non-stretch, 7.5 mm wide, individually knitted from 80 micron monofilament threads.

Technique of TFS

A small channel was made between the vagina and urethra to perforate the urogenital diaphragm (perineal membrane), exactly like the first part of a TVT. The anchors were inserted into the inferior surface of the pubovaginalis muscles, immediately behind the urogenital diaphragm (fig. 3). The tape was tightened over an 18 gauge rigid Foley catheter until it touched, but did not indent, the urethra, fig. 2. The TOT also had a non-stretch 10 mm wide monofilament tape, and was performed with a standard “outside in” protocol.

The patients were reevaluated at 2 weeks, 3 months, 6 months, 1 year, 2 years and at 3 years. The postoperative assessment was done by a senior surgeon of the urogynecology clinic who did not take part in the operations. The first author was not involved in the follow up process.

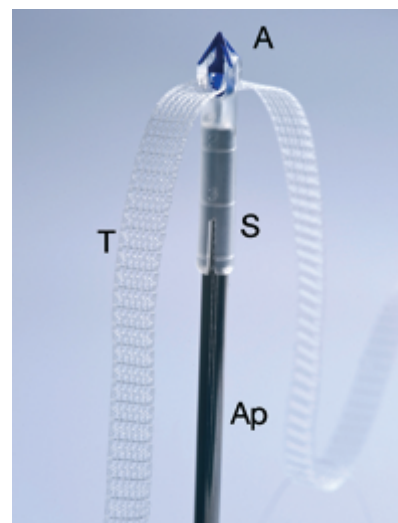


Fig. 2. – The polypropylene anchor (A) is held in a saddle (S) on an applicator (Ap). A macroporous polypropylene tape (T) is threaded through the base of the anchor to provide a one way tightening system.

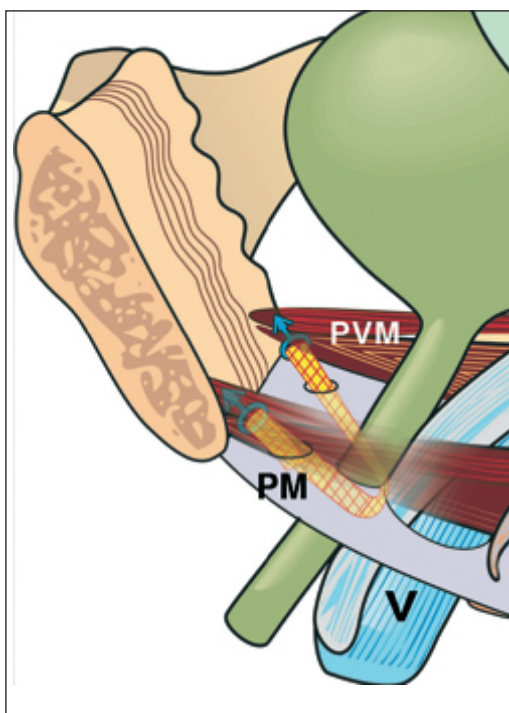


Fig. 3. – The TFS midurethral sling. The sling is inserted just behind the perineal membrane (PM) into the undersurface of the pubovaginalis muscle (pubococcygeus and puborectalis), below the Space of Retzius.

Our primary outcome measure was objective cure rate after 3 years of antiincontinence surgery. Secondary outcome measures were duration of procedures, postoperative comfort of the patients (e.g groin pain) and quality of life (OoL) scores.

If the CSPT was negative after the operation and the patient reported the restoration of urinary continence, then it was regarded as “objective cure”. If the patient reported the restoration of urinary incontinence but the supine cough stress test was positive, then it was regarded as “subjective cure”. If no change in the incontinence complaint after the operation then it was regarded as “failure”

Total follow period was 36 months (36± 1 month).

TABLE 1. – Patient characteristics.

Variable	TOT n=38	TFS n=39	p value
Age	51.5 ±12.5	54 ±13.6	0.6
Body mass index	29.6 ± 2.7	28.7±3.1	0.7
Parity	2.5±1.7	2.7±1.3	0.4
Postmenopausal	27 (71%)	29(74%)	0.3
Hormone replacemet therapy	5 (13%)	7(18%)	0.6
Duration of SUI (in years)	4.7±1.3	5.1± 0.3	0.5

Mean±standard deviation and n (%)

TABLE 2. – Operation duration, intra and postoperative complications

Variable	TOT n=38	TFS n=39	p value
Duration of procedure(min)	12±1	5±1	0.001
Bladder injury	0	0	Not applicable
Bleeding exceeding 100 ml.	0	0	Not applicable
Urinary retention	2 (5%)	0	0.3
Postop groin pain	12 (31.5%)	0	0.04
Anchor displacement	0	1 (2.5%)	Not applicable

Mean ± standard deviation and n (%)

To have 80% power to detect this difference and to limit the chance of type I error to 5%, the number of patients for each group was estimated to be 36. We decided to add approximately 10% to this concerning loss to follow up. Therefore, the total sample size was calculated to be 80 patients (40 in each arm) (α=0.1).

All the data were recorded using standard forms. We used SPSS 11.5 (Statistical Package for Social Sciences) for Windows for statistical analysis. We gave the results as mean±standard deviation and as numbers and percents. The Student’s t test and Fischer Exact test were used where appropriate.

For all comparisons, p < 0.05 was considered statistically significant.

RESULTS

The groups were similar in terms of age, body mass index, parity, menopausal status, hormone replacement therapy, and the duration of SUI (Table 1).

The analysis of the data showed that the duration of the operation was significantly shorter in the TFS group (5±1 min) compared to the TOT group (12±1min, p < 0.001) (Table 2). No intraoperative complications such as bladder injury or/and bleeding exceeding 100 ml were seen. However, there were 2 urinary retentions in TOT group. In addition postoperative groin pain was significantly high in TOT group (12 patients) (Table 2).

During the preoperative assessment period, the VLPP (cystometry) and cough stress pad tests were carried out. Both tests were also carried out at the 3 years follow up. There were no statistically significant difference between groups in terms of preoperative and postoperative CSPT values (Table 3). Whereas, there were statistically significant difference within groups in terms of preoperative and postoperative CSPT values (Table 4).

TABLE 3. – Pre and postoperative assessment of and CSPT in both groups.

Variable	TOT n=38	TFS n=39	p value
Preop. CSPT (gr)	67±24	75±14	0.7
Postop CSPT (gr)	0.46±0.5	0.75±0.2	0.4

TABLE 4. – Pre and postoperative assessment of CSPT within groups

	Preoperative	Postoperative	p value
TOT Group			
CSPT(gm)	67±24	0.46±0.5	0.0002
TFS Group			
CSPT(gm)	75±14	0.75±0.2	0.0001

TABLE 5. – Cure rates after the operations

Variable	TOT n=38	TFS n=39	p value
Objective cure rate	84% (32 cases)	90% (35)	0.036
Subjective cure rate	5% (2 cases)	2% (1)	0.812
Failure	11% (4 cases)	8% (3)	0.674

TABLE 6. – Pre and postoperative QoL(mean of scores) comparisons within groups

	Preoperative	Postoperative	p value
TOT Group			
Mean of QoL	14±7	4±1	0.006
TFS Group			
Mean of QoL	15±6	3±1	0.005

For analysis of cure rates at the end of 3 years, 38 patients were available for the TOT group and 39 patients were available for the TFS group (fig. 1). The objective cure rate, subjective cure rate and failure rate in TFS group were 90% (35 cases), 2% (1 case) and 8% (3 cases), respectively. The objective cure rate, subjective cure rate and failure rate in TOT group were 84% (32 cases), 5% (2 cases), and 11% (4 cases), respectively (Table 5). There was statistically significant difference between groups in terms of objective cure rate ($p>0.05$).

There were no statistically significant difference between groups in terms of the mean of the preoperative QoL scores ($p>0.05$). However, statistically significant differences were obtained when the preoperative and postoperative mean of QoL scores were compared within groups ($p<0.05$) (Table 6). The mean of the QoL scores have improved in both of the groups.

The total follow up period was 36 ± 1 months.

TOT group complications

Urinary retentions were resolved with a 3 days long catheterization. Postoperative groin pain lasted 2 weeks in 9 patients. Two patients needed anti-inflammatory medications and their complaint stopped within 1 month. One patient refused any intervention for her groin pain and at 3 years follow up she reported that she had been feeling a nasty pain sometimes (particularly in long distance walking) but she did not want any intervention.

TFS group complications

Anchor displacement in the left side was observed in 1 patient at her 1 year control. The anchor was removed under local anesthesia and the patient remained continent.

There were no tape erosions in either group.

DISCUSSION

As far as we know, this is the first study comparing a minisling with a more conventional anti-incontinence operation, the TOT. The objective cure rate in TFS group was higher than the TOT group and the difference was statistically significant ($p<0.05$). In addition the TFS was significantly superior with regard to the secondary outcome measures. The TOT group had a significant incidence of groin pain (31%), higher urinary retention (5%), and longer operating time (12 minutes vs 5 minutes).

A major concern in planning this study was to ensure equivalence in the surgical protocols, and to remove as much bias as possible. Our methodology aimed to narrow these variables. All the operations were performed by the same surgeon who was experienced in both the TOT and the TFS midurethral sling operations. The populations were similar. A non-stretch tape was used in both operations which were all performed under spinal anesthesia. Evaluation of the operated patients was performed by an independent observer and it was based on objective criteria, weighed loss by means of cough pad tests. Another concern was whether a learning curve of 10 was sufficient training for the TFS. The results indicate that 10 was a sufficient number.

The anatomical restoration of the TFS is almost identical to that of the TVT. The TFS is inserted retropubically in a vertical position, exactly the same axis as the TVT. Unlike the TVT, however, the TFS at all times remains below the space of Retzius. Post-operative ultrasound studies indicate that

it is very close to the origin of the pubourethral ligament^{8,9}, which it seeks to reinforce. The anatomical studies of Zacharin demonstrate a vertically disposed pubourethral ligament¹⁰. On the other hand Scherlitz et al.'s study suggest that TOT may be inferior to the TVT in the treatment of stress urinary incontinence¹¹. The study showed 14 of 67 patients (21%) in the TVT group had stress incontinence demonstrated during repeat urodynamic assessment compared with 32 of 71 (45%) in the TOT group ($p<0.05$). They concluded that retropubic TVT is a more effective operation than the transobturator tape sling in women with urodynamic stress incontinence.

QoL scores have improved after the operations. Both operation types had good effects on the QoL measures.

In our study; the TFS showed better objective outcomes in comparison to TOT, hence; low complication rate, high postoperative compliance with TFS and the ease of TFS technique herald that TFS deserves wide utilization. However; more randomized studies with larger samples are needed to corroborate these findings.

REFERENCES

- Petros PE, Ulmsten UI. An integral theory of female urinary incontinence. *Acta Obstet Gynecol Scand Suppl.* 1990;153: 7-31.
- Enhörning G. Simultaneous recording of intravesical and intra-urethral pressure. *Acta Chir Scand.* 1961; 276: 1-67
- Ostergard DR. The epochs and ethics of incontinence surgery: is the direction forward or backwards? *Int. Urogynecol J.* 2002; 13:1-3
- Delorme E. Transobturator urethral suspension: mini-invasive procedure in the treatment of stress urinary incontinence in women. *Prog Urol.* 2001;11: 1306-13.
- Petros PE, Richardson PA. Midurethral Tissue Fixation System (TFS) sling for cure of stress incontinence—3 year results. *Int. Urogynecol J* 2008;19:869-871.
- Sivaslioglu AA. Re:Midurethral tissue fixation system sling ANZJOG 2006;Oct 46(5):464-5
- McGuire EJ, Fitzpatrick CC, Wan J, et al. Clinical assessment of urethral sphincter function. *J Urol* 1993; 150 (5 Pt 1):1452–1454.
- Petros PE, Von Kinsky B. Anchoring the midurethra restores bladder neck anatomy and continence. *Lancet* 1999; 354:997-99813
- Petros PE & Ulmsten U. An Integral Theory and its Method, for the Diagnosis and Management of female urinary incontinence, *Scandinavian Journal of Urology and Nephrology.* 1993; Vol 27 Supplement No 153 – 1-93.
- Zacharin RF. A suspensory mechanism of the female urethra. *Journal of Anatomy.* 1963; 97:423-427.
- Schierlitz L, Dwyer PL, Rosamilia A, Murray C, Thomas E, De Souza A, Lim YN, Hiscock R. Effectiveness of tension-free vaginal tape compared with transobturator tape in women with stress urinary incontinence and intrinsic sphincter deficiency: A randomised trial. *Obstet Gynecol.* 2008; 112:1253-61

Correspondence to:

Assoc. Prof. Dr. A. Akin Sivaslioglu
 Ümit Mahallesi
 2543. Sokak No:11/1
 Cayyolu/Ankara/Turkey
 Mobile number: 0090-532-2770618
 E-mail: akinsivaslioglu@gmail.com
 Conflict of interest: None

Cure of haemorrhoids following a TFS posterior sling and TFS perineal body repair - a case report

GIANCARLO PARADISI⁽¹⁾, PETER PETROS⁽²⁾

⁽¹⁾ Department of Obstetrics and Gynecology, Università Cattolica del Sacro Cuore, Rome, Italy,

⁽²⁾ University of Western Australia

Summary: Cure of 3rd degree prolapse, cystocele, rectocele and a bleeding haemorrhoids is reported following total pelvic floor reconstruction with TFS tensioned minisling surgery. This case illustrates the importance of a holistic approach to pelvic organ disorders, repairing the organ's structural components, rather than traumatic excision of organ parts

CASE REPORT

Mrs FA, aged 43 years, para3, BMI 22, presented with a feeling of heaviness, a uterus extruding from the vagina, and a history of haemorrhoids and bleeding for several years. She had regular periods with slight menstrual loss, normal ovaries, uterus and endometrium on ultrasound examination. There was no history or symptom of urinary dysfunction. Urodynamic testing indicated normal cystometry, normal urine flow, normal cough stress test at 400 ml, and a maximal urethral closure pressure of 156cm H2O.

On clinical examination, prolapse according to the Baden Walker Score was Cystocele II°,

Urethrocele II-III° with urethral hypermobility, Hysterocele III°, Rectocele I° with a thin bulging. POPQ Score (ICS) was : 3Aa, 3C, 1Bp

Assessment of ligamentous damage with 'simulated operations' in the OR

Allis forceps applied 2cm superolaterally to the cervix, in the position of the cardinal ligaments and when approximated, restored the cystocele entirely, indicating that a cardinal ligament TFS would be sufficient. Application and approximation of Allis forceps to the vagina 2cm posterolateral to the cervix totally restored the uterine prolapse. The perineum was extremely lax, and the bulge created by digital stretching anteriorly was equivalent to a 3rd degree prolapse. Approximation of the laterally displaced perineal bodies significantly reduced the rectocele.

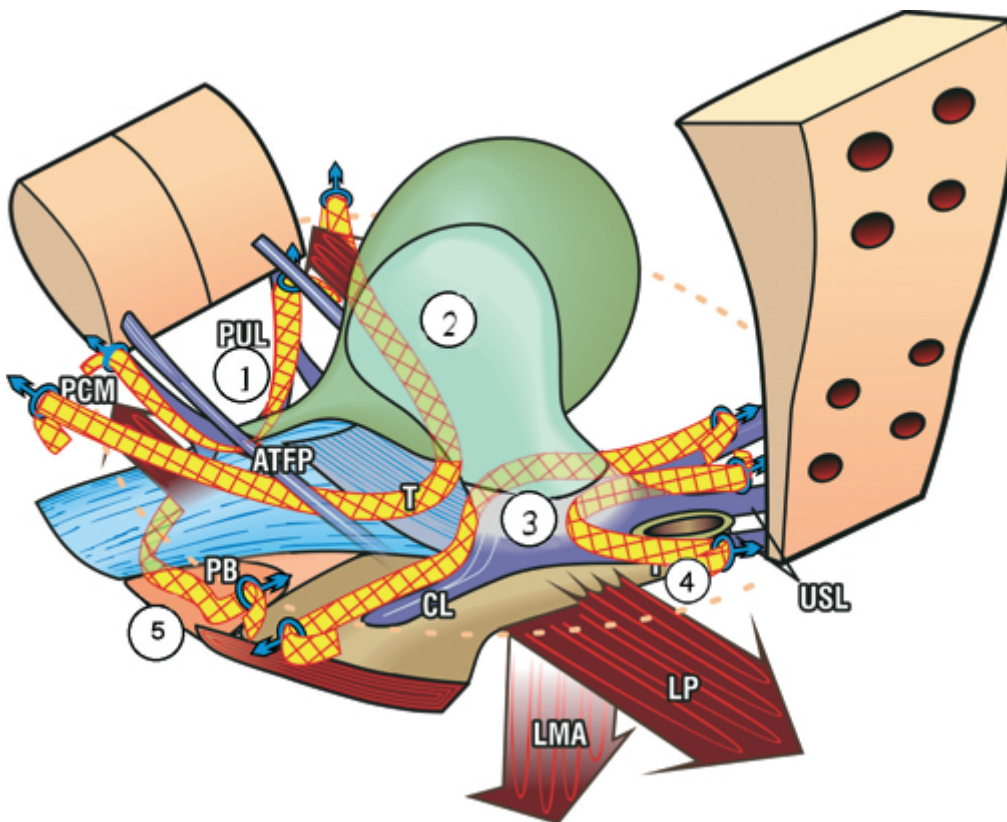


Fig. 1. – The sites of TFS minisling reconstruction. This is a 3D view of the pelvic organs and ligaments from above and behind. The numbers signify which structures are supported by the TFS tapes. 1 TFS midurethral sling (pubourethral ligament); 2 TFS U-Sling (ATFP and pubocervical fascia); 3 TFS high cystocele repair (cardinal ligament cervical ring); 4 TFS uterine prolapse/apical repair (uterosacral ligaments); 5 TFS perineal body repair (m.deep transversus perinei).

Surgery

The uterine prolapse, cystocele and rectocele were repaired entirely by precise application of the TFS tapes in the position of the damaged ligaments, Nos 4,3&5, in fig1, without tissue excision, as described previously^{1,2}. The surgical operations were all performed by the first author, some for the first time, with the assistance of the 2nd author. Total operating time including discussion, and ‘simulated operations’ to assess which ligaments were damaged was 150 minutes. Total blood loss was 200ml. At the end of the operation, a deep normal axial restoration of anatomy was noted for the anterior vaginal wall, uterus, and posterior vaginal wall, with complete disappearance of cystocele and rectocele. The postoperative changes to the perineal anatomy are self-evident, figs 2&3.

DISCUSSION

This case emphasizes the need for a holistic view of pelvic floor dysfunctions. We were able to cure the haemorrhoids as part of a total pelvic floor reconstruction. “*restoration of form (structure) leads to restoration of function*’.”- Integral Theory³. This case also sheds light on a wider issue, the futility of painful and sometimes hazardous excision of major segments of an organ, in this case rectum, when a minor, less damaging procedure not only is enough, but also restores other dysfunctions such as hemorrhoids.

We attribute hemorrhoid cure to upward and backward stretching of the anterior wall of rectum by the posterior sling, a restoration which also eliminates the varicosities and venous return of rectal wall veins which we believe are the ultimate cause of hemorrhoid formation. Using pre

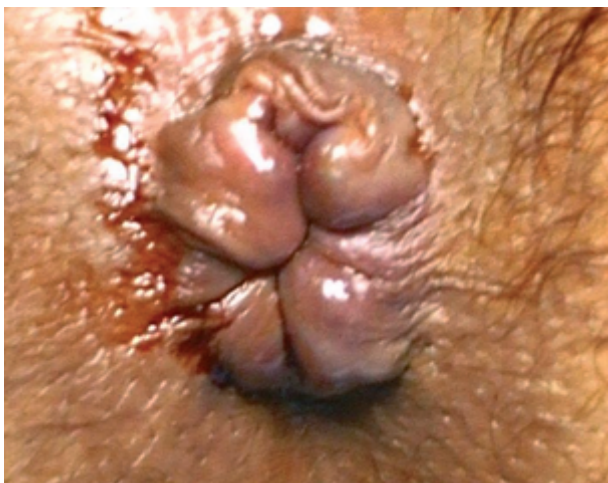

Fig. 2 – Haemorrhoids pre-operative.

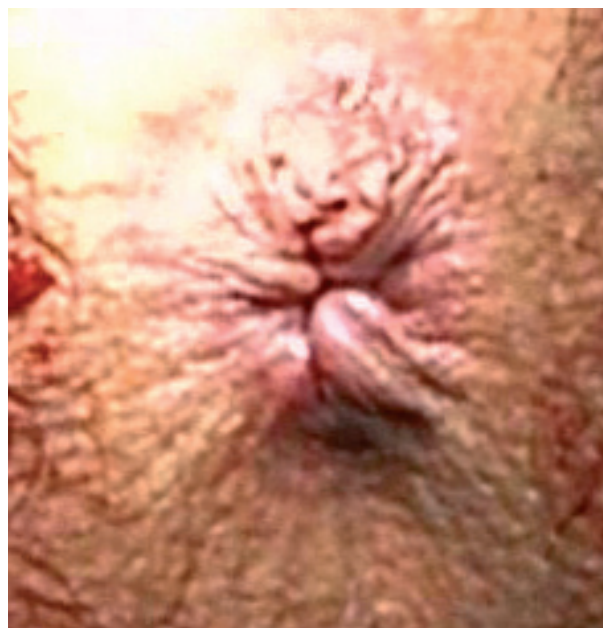

Fig. 3 – Haemorrhoids post-operative. There was minimal pain, and the patient was discharged on the second post-operative day.

and postoperative evacuating proctograms, Abenstein et al.⁴ demonstrated cure of anterior rectal wall intussusception with a posterior sling, but did not report cure of hemorrhoids..

The concept of ‘simulated operations’ in effect brings together laterally displaced structures in real time. This manoeuvre diminishes the herniation, and restores muscle tension on the structures, allowing the surgeon to more accurately decide which structures to repair.

REFERENCES

1. Petros PEP, Chapter 4, Surgery, in “The female Pelvic Floor”, 2nd Edition, Springer Heidelberg, 2006, pp 112-159.
2. Petros PE Richardson PA. A 3 year follow-up review of uterine/vault prolapse repair using the TFS minisling. RANZJOG 2009; 49; 4. 439-440 (2).
3. Petros PEP, Chapter 1, Overview, in “The female Pelvic Floor”, 2nd Edition, Springer Heidelberg, 2006, p 7.
4. Abendstein B, Petros P. E. P, Richardson P. A., Goeschen K, Doder D. The surgical anatomy of rectocele and anterior rectal wall intussusception. Int Urogynecol. J 2008; 19: 513-7.

Correspondence to:

Email addresses:

giancarlo.paradisi@tin.it - kvinno@highway1.com.au

Website: www.integraltheory.org