

# The TFS minisling restores major pelvic organ prolapse and symptoms in aged Japanese women by repairing damaged suspensory ligaments – 12 - 48 month data

HIROMI INOUE<sup>1</sup>, YUTAKA KOHATA<sup>1</sup>, YUKI SEKIGUCHI<sup>2</sup>, TUYOSHI KUSAKA<sup>1</sup>, TAKANORI FUKUDA<sup>1</sup>, MIKA MONNMA<sup>1</sup>

<sup>1</sup> Shonan Kamakura General Hospital - Gynecology

<sup>2</sup> Yokohama Luna Clinic - Urology

**Background:** Ageing of Japan's population has brought increases in pelvic organ prolapse (POP) and symptoms, creating problems for patient QOL, the health system, the community and government cost.

**Objective:** To assess effectiveness of the Tissue Fixation System (TFS) in curing POP and symptoms of nocturia, urgency, frequency, chronic pelvic pain, fecal incontinence by suspensory ligament repair as predicted by the Integral Theory System.

**Design, Setting, and Participants:** a tertiary pelvic floor referral centre. Prospective observational study: 278 aged females (mean 69.6years), referred for primary POP repairs January 2009 - December 2012; initial 12 month and 4 year follow-up of original cohort.

**Inclusion criteria:** 3rd or 4th degree uterine/vaginal prolapse (POPQ classification).

**Exclusion criteria:** serious comorbid conditions.

**Intervention(s):** Damaged structures, ATFP, cardinal, uterosacral ligaments and perineal body were identified and repaired by an adjustable TFS tape attached to soft tissue anchors applying the same neoligament principle used in the TVT operation.

**Outcome Measurements and Statistical Analysis:** Follow-up: 12 months (n = 278), then yearly. 50/68 initial cohort reviewed at 4 years. Statistics: Lower and upper 95% confidence for observed relative frequencies of POP and symptoms were calculated for observed cure rates of 80%, 75% and 60% respectively (p < 0.05 Binomial Tests).

**Surgical failure:** any compartment prolapse for that patient at or beyond stage 2, (POPQ classification).

**Results:** Mean hospital stay: 0.7 days (0-7); mean return to normal activities: 2.2 days.

**Surgical cure rate** for POP (n = 278): 91.2% at 12 months, with a 10% fall at 48 months for original cohort (n = 68) to 84% (n = 50).

**Symptom cure rate** at 12 months 278 patients: nocturia (n = 86) 72.1%; daytime frequency (n = 132) 90.1%; urgency (n = 133) 93.2%; chronic pelvic pain (n = 56) 93%; fecal incontinence (n = 52) 88.5%. **Complications** There were two early cases of ileus because of intraperitoneal placement of the tape, attributed to incorrect technique. Erosion rate (all TFS placements) 3.0% Excluding the perineal body tapes, the erosion rate was 9/989 = 1.1%.

**Limitations** 18 absent patients from the 4 year follow-up.

**Conclusions:** The minimal nature and high cure rate of bladder and bowel symptoms may offer hope for reduction of admissions to Nursing Homes in the future. However, large multicenter more robust comparative studies will be required to more fully assess this method before such hopes can be justified.

**Key words:** TFS; POP; Nursing homes; Cystocele repair; Perineal body repair; Rectocele repair; Uterine prolapse repair; Adjustable minisling.

## INTRODUCTION

The Japanese female population is ageing rapidly. In September 2013, there were 17.59 million women aged 65 and older, an increase of 7.6% in 4 years.<sup>1</sup> Consequently, more Japanese women are developing pelvic organ prolapse (POP) and troubling symptoms such as urgency, nocturia, chronic pelvic pain, bladder emptying problems, causing major problems for patient QOL, the health system the community and government cost. Collateral health problems create a concomitant demand for minimally invasive operations to safely correct the prolapses. The TFS (Tissue Fixation System),<sup>2,4</sup> fig. 1, is a less invasive evolution of the TVT operation;<sup>5</sup> like the TVT, a short narrow strip of tape provokes the host tissues to create an artificial collagenous neoligament,<sup>6</sup> to reinforce the 5 supporting structures of the pelvic organs, pubourethral, arcus tendineus fascia pelvis (ATFP), cardinal (CL), uterosacral ligaments (USL) and perineal body (PB).

The TFS was introduced to Japan in 2006 at the 13th Annual Meeting of the Neurogenic Bladder Society of Japan and the first live surgery of TFS in Japan was performed in September 2006 under the aegis of the Japanese Society for Pelvic Floor Medicine.

In a previous work,<sup>7</sup> we described our preliminary assessment of this method, including initial POP and symptom cure, analysis of the learning curve (short) and surgical complications (few).

The primary aim of this work was to report our experience of using TFS for POP over 4 years and 278 patients. A secondary aim was to track the fate of pelvic symptoms, urgency, frequency, nocturia, chronic pelvic pain and fecal incontinence.

## MATERIALS AND METHODS

This was a prospective observational study. We used validated questionnaires<sup>8</sup> and ICIQ SF to assess symptoms, vaginal examination to directly identify the sites of ligament repair, according to specific anatomical criteria set down for clinical diagnosis of damaged ligaments.<sup>9</sup>

The TFS (TFS Surgical, Adelaide South Australia) consists of an applicator, a non-stretch tape attached to two soft tissue anchors with an adjustable mechanism at the base, fig1. A non-stretch lightweight non-stretch type 1 macropore monofilament polypropylene mesh tape was used. The TFS sling operations were variously applied at up to 5 main sites, figures 2-4. We calculate that the total length of implant was 5-8cm for each tape.

**Anterior wall support for cystocele repair, fig. 2** The U-Sling supports the distal vaginal wall; it repairs the lateral defect by re-attaching the prolapsed vaginal wall to the ATFP near its origin behind the pubic bone immediately above the pubourethral ligament and there is growing evidence that it may restore dislocated pubovisceral muscles also (9a). The cardinal ligament repairs the high or trans-




Figure 1. – The TFS system for creation of artificial collagenous neoligaments for POP and USI cure. Applicator (AP) and anchor (A). T=lightweight macropore monofilament tape. At the base of ‘A’ is a system which allows one-way directional tensioning of the tape. (Reproduced with the permission of TFS Surgical)

verse defect. It re-attaches the prolapsed pubocervical fascia to the cervical ring, shortens the cardinal ligament and re-attaches the displaced ATFP onto the side wall.

*Apical support for uterine/apical prolapse, fig. 2.* The cardinal TFS sling re-attaches the uterus or apex laterally to the fascia of the side wall skeleton. The uterosacral TFS attaches it posteriorly to the pre-sacral fascia at S3 level.

*Posterior vaginal and anterior rectal wall support, figures 2&3*

The uterosacral TFS attaches the posterior cervical ring posteriorly to the pre-sacral fascia at S3 level. Because it passes by the lateral wall of the rectum, it, too, is re-attached, constituting a transvaginal rectopexy. At the level of the introitus, the reconstituted perineal body supports 50% of the posterior vaginal wall<sup>10</sup> and the anus.<sup>11,12</sup>

*Urinary stress incontinence* It is the policy of our department not to perform USI surgery concomitantly with POP surgery. There were 6 exceptions made in this study.

#### TFS SURGICAL TECHNIQUE

The surgical technique uses the same technique for all the TFS operations. The vagina is incised. Bladder, enterocele or rectum are dissected as required. The ligament is identified. A tunnel is made with Metzenbaum scissors. The applicator is inserted into the tunnel. The anchor is released. The application is repeated on the contralateral side and the tape is adjusted until a resistance is felt. This indicates return of muscle tone in the muscles which act on that ligament. The tape is cut and the vagina is closed.

The prolapse was staged according to the ICS POPQ classification.<sup>13,14</sup>

This study was approved by the Ethics Committees of the Kamakura General Hospital in 2006. Written informed con-

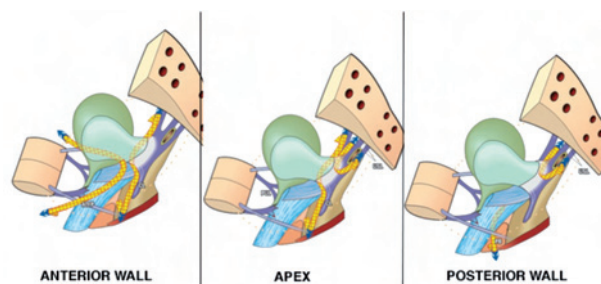


Figure 2. – TFS Surgery for POP The anchor is positioned along the ligament and tape adjusted to remove looseness. This lifts the organ back into its non-prolapsed position. The tape reinforces the ligaments and stretches the anterior and posterior vaginal wall like ropes stretching a tent. By strengthening the ligaments, the TFS also restores the muscle forces which support, open and close the organs, on the basis that the ligaments are the effective insertion points of the pelvic muscles. (Reproduced with the permission of Professor Peter Petros)

sent was obtained from all patients. The principles of the Helsinki Declaration (2008) were followed.

#### RESULTS

Operations using the TFS anchor system were performed on 278 women, mean age 69.6 years (36-89), between January 2009 to December 2012 inclusive. Mean parity was 2.2 (range 0-6). Mean body index was 24.2 (range 15.1-39.8). All patients had stage 3 or 4 pelvic organ prolapse according to the Pelvic Organ Prolapse Quantification (POPQ) standard scoring system. The results are summarized in Tables 1&2.

A total of 989 tapes were used in 278 patients (mean 3.5 tapes per patient).

There were 272 U slings for lateral/central anterior vaginal wall defects, 243 posterior slings (USL-sling) of the uterosacral ligaments, 264 Cervical slings for cardinal ligament defects, 204 perineal body slings for defect of the perineal body and 6 pubourethral slings for SUI (ISD) were performed.

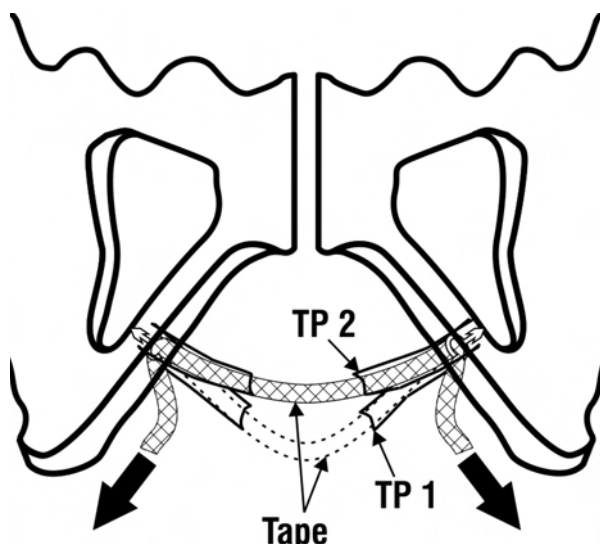


Figure 3. – Perineal body (PB) TFS sling The anchors penetrate the deep transversus perinei which inserts exactly at the junction of the upper 2/3 and lower 1/3 and the tape is tightened. In patients with descending perineal syndrome, this action elevates the prolapsed perineal body from position TP1 to TP2. (Reproduced with the permission of Professor Peter Petros)

Mean operation time was 89.4 minutes (range 39-190). The time for insertion of a TFS sling varied between 15-25 minutes per ligament. Mean estimated total blood loss per patient was 74ml (range 5-378ml). Mean hospitalization after operation was 0.7 days (range 4 hours to 3 days), with 42% of patients discharged on the same day. Mean days return to usual life was 2.2 days (range 1-10 days). Mean no of tapes per patient 3.5 (range 1-5).

We defined surgical failure as any prolapse in any compartment of the patient at or beyond stage 2 according to the ICS POPQ classification, even, if in patients undergoing multiple TFS surgeries, other compartments remained intact. On this basis, surgical cure rate for POP was 91.2% at 12 months. The 12 month cure rate for the original cohort was largely maintained, with only a 10% fall at 48 months, from 91.2% (n = 68) to 84% (n = 50).

There were no intraoperative complications and no bladder or bowel perforations. However, there were two longer term post-operative complication, ileus due to tape in abdominal cavity and adhesion of the mesentery and USL mesh tape, 3 and 15 months after operation and treated operatively by laparotomy and adhesiolysis. In case 1, omentum was dissected from the tape. In case 2, between small

bowel and tape. Both patients recovered well without prolapse recurrence. This complication occurred in the 1st cohort of patients. It was attributed to faulty surgical technique and resulted in change in technique, ensuring the tape was extraperitoneal at all times. There have been no further episodes of this complication in the subsequent 209 patients.

Of 989 tapes inserted over a 12-48 month period (2009-2012), 30 tapes of 29 patients were rejected or eroded and partial excision of meshes was performed in all patients as an outpatient procedure. However, this figure included a disproportionate number of perineal body slings. Including the 1st cohort, the rate of tape rejection or erosions was 0.4% in the AFTP U-slings (1/272), 1.5% in Cardinal/Cervical ring slings (4/264), 1.6% in posterior slings (USL-sling) (4/243), and 10.3% in perineal body (PB) slings (21/204), respectively. Rejection rates for PB slings were 21.6% in 2009, 4.3% in 2010-11 and 2.6 % in 2012. There was no rejection of midurethral slings (n = 6) and all 6 patients were cured. The total rate of rejection or erosions in 989 tapes including the perineal body tapes was 30/989 (3.0%). Excluding the perineal body tapes, the erosion rate for the other tapes was 9/785 = 1.1%.

TABLE 1. – Lower and upper 95 % confidence intervals for the observed relative frequencies of Prolapse, Urgency, Nocturia, Day time frequency, Dragging pain and Fecal incontinence. Parallely the results of testing the hypothesis Ho: P ≤ p0 vs H1: p > p0 have entered.

Variable	N	No of cured	observed cure rate (%)	95 %-lower CI	96 %-upper CI	Test results Ho: p ≤ p0 vs. H1: p > p0
Prolapse	278	257	92.10	0.891	0.952	*
Urgency	133	124	93.20	0.879	0.971	*
Nocturia	86	62	72.10	0.597	0.809	/
Day time frequency	132	120	90.10	0.935	0.999	*
Dragging pain	56	52	92.90	0.862	0.998	*
Fecal incontinence	52	46	88.50	0.798	0.977	#

\*, # and / means significant p-values when p0 is setting equal to 0.80, 0.75 and 0.60, respectively. With other words these symbols depict that the observed cure rates are significantly higher than 0.80, 0.75 and 0.60 respectively (p < 0.05; Binomial Tests)

TABLE 2. – Lower and upper 95% confidence intervals for the observed relative frequencies of Prolapse, Urgency, Nocturia, Day time frequency, Dragging pain and Fecal incontinence after certain time intervals with the test results by testing Ho: Ps p0 vs H2: p > p0.

Time after TFS	Cure of prolapse	Cure of urgency	Cure of nocturia	Cure of day time frequency	Cure of dragging pain	Cure of dysuria	Cure of fecal incontinence
12mths observed cure rate (in %)	62/68 91.2%	30/31 96.8%	17/18 94.4%	30/32 93.8%	13/14 92.9%	35/38 92.1%	16/18 88.9%
95 % (lower CI; upper CI)	0.877 0.946	0.936 0.999	0.890 0.998	0.895 0.980	0.860 0.997	0.877 0.965	0.815 0.963
Test results of Ho: p ≤ 0.80 vs. H1: p > 0.80	*	*	#	*	/	*	/
24mths observed cure rate (in %)	57/65 87.7%	25/30 83.3%	11/17 64.7%	26/29 89.7%	14/15 93.3%	26/28 92.9%	12/15 80%
95 % (lower CI; upper CI)	0.836 0.918	0.765 0.901	0.531 0.763	0.840 0.953	0.869 0.998	0.880 0.977	0.697 0.903
Test results of Ho: p ≤ 0.80 vs. H1: p > 0.80	*	/	ns	/	/	#	ns
36mths observed cure rate (in %)	48/58 82.7%	23/24 95.8%	14/23 60.9%	27/30 90.0%	9/10 0.900	25/26 96.2%	6/7 85.7%
95 % (lower CI; upper CI)	0.778 0.877	0.918 0.999	0.507 0.710	0.845 0.955	0.805 0.995	0.924 0.999	0.725 0.969
Test results of Ho: p ≤ 0.80 vs. H1: p > 0.80	/	*	ns	#	/	*	ns (7)
48mths observed cure rate (in %)	42/50 84%	18/20 90.0%	8/17 47.1%	13/19 68.4%	6/6 1.000	22/23 95.6%	5/5 100%
95 % (lower CI; upper CI)	0.788 0.892	0.833 0.967	0.350 0.592	0.578 0.791	1.000 1.000	0.914 0.999	1.000 1.000
Test results of Ho: p ≤ 0.80 vs. H1: p > 0.80	/	/	ns	ns	/(*)	*	ns (7)

\*, # and / means significant p-values when p0 is setting equal to 0.80, 0.75 and 0.60, respectively. With other words these symbols depict that the observed cure rates are significantly higher than 0.80, 0.75 and 0.60 respectively (p < 0.05; Binomial Tests) Note: Yellow marked field in table 2 means that we have to pay attention in the interpretation of significances, because for these fields the corresponding sample sizes are too small.



## DISCUSSION

This is the first longer term study of a minisling system applied to POP. Our opinion, based on 12 and 48 month data, mean age of the patients (69.6 years), is that the TFS is a safe and effective method for POP reconstruction especially applicable to the old and frail because of its minimal invasiveness. It is known that urinary and fecal incontinence are responsible for more than 50% of female admissions to Nursing Homes. The continued effectiveness of the TFS as regards POP, bladder and bowel symptom cure at 4 years encourages us to predict that this method may well be the key to solving the looming societal, health and economic problems associated with caring for older populations.

The TFS is a very different technique to the large POP mesh kits inserted behind the vagina in DeLancey level 2. Large mesh sheets inserted at level 2 glue the organs to the vagina, inhibiting independent organ movement, thus facilitating erosion, dyspareunia and perhaps organ dysfunction. The TFS is a direct evolution of the TVT, works much like the TVT and has similar erosion rates. It is applied directly onto damaged ligaments which lie outside the vaginal wall at DeLancey levels 1&3. The one-way sling tightens lax ligaments and fascia. Our experience is that if the anchors are correctly positioned, this method has a low incidence of erosion and causes minimal organ adherence. The antero-posterior elasticity required for normal organ function and symptom cure at Level 2 is largely maintained.

The TFS method allows 'real-time' visualization as the restitution of the pelvic floor anatomy proceeds. For example, there is a sudden deepening of the sulcus after the TFS cardinal tape is tightened, rapid elevation of a prolapsed uterus with the USL sling, elevation of distal vagina on tightening the ATFP U-Sling, disappearance of low rectocele and perineocele on tightening the perineal body sling, with concomitant correction of the "descending perineal syndrome".

Based on operating time and blood loss, we estimated the learning curve in a previous publication<sup>7</sup> to be 5 cases. The 4 year data which was inclusive of learning curve, appears to substantiate this view. However, there are important subtleties in the technique which may lead to problems, for example, two cases of ileus and high initial erosion rates with the perineal body TFS.

The two patients who presented with ileus-type symptoms post-operatively were from the 1st cohort. We attributed this to a fault in technique: we did not take sufficient care to dissect and close the enterocele, or to angle the applicator from medial to lateral during the tape insertion, so as to avoid the peritoneal cavity. We have not experienced any further ileus complications.

The first improvement in erosion rate followed when we changed the position of the anchors from inside the perineal body to behind the insertion point of deep transverse perinei at the junction of the upper 2/3 and lower 1/3 of the descending pubic ramus. The 2<sup>nd</sup> improvement was changing from one layer closure to a two layer closure and washing with sterile normal saline 100ml before closure. Following this, the rate of tape rejection or erosions in perineal body slings was improved, from 21.6% in 2009, to 4.3% in 2010 and 2011 to 2.6% in 2012.

We have not experienced any of the problems reported by Atherton *et al.*,<sup>15</sup> 5 case reports out of 1012 inserted tapes.<sup>16</sup> The complications were mainly anchor slippage consequent upon excessive tissue reaction to the multifilament tape in use at the time.<sup>16</sup> No such problems have occurred in 989 implants using the lightweight macropore type 1 tape.

The high improvement rate in symptoms of nocturia, urgency chronic pelvic pain and fecal were consistent with the predictions of the diagnostic system we used to place the

tapes.<sup>9</sup> We consider this to be an important finding, as the estimated annual cost of hospitalizations for hip fracture in the EU-15 countries due to severe nocturia alone is approximately  $\square$  billion p.a.<sup>17</sup> Chronic pelvic pain is another disabling condition which occurs in up to 20% of women<sup>18</sup> and is considered incurable.<sup>19</sup> Furthermore, it is generally acknowledged that >50% of admissions to Nursing Homes is due to urinary or fecal incontinence. This method offers hope that some of these admissions may, in the future, be prevented with major benefits for patient QOL and the public purse.

Cure of non-sphincteric fecal incontinence (FI) was an affirmation of a previous study by Abendstein *et al.*,<sup>20</sup> who attributed their FI cure to restoration of competent PUL and USL ligaments.

The perineal body data supports the study of Wagenlehner for cure of patients who require manually assisted defecation<sup>12</sup> for descending perineal syndrome. The laterally displaced perineal bodies are elevated and positioned medially, thereby preventing extrusion of the rectocele, fig. 3, and restoring normal defecation.

We are uncertain as to the final mechanisms for restoration of such widely diverse symptoms. According to,<sup>9</sup> the one-way sling tightens lax ligaments and fascia, thereby restoring the action of muscles which contract against these structures to open and close the urethra and anorectum and to support nerve bundles in the uterosacral ligaments in patients with chronic pain.

## CONCLUSIONS

The TFS procedures apply the same neoligament method as the TVT to repair other ligaments besides the pubourethral. This method appears to deliver good results for POP and symptoms, with low mesh reactions once the technique is properly learnt. It has the potential to provide at least a partial answer to the twin dilemmas confronting POP repair today, poor results from native tissue repair and problems using large mesh sheets. The minimal nature and high cure rate of bladder and bowel symptoms may offer hope for reduction of admissions to Nursing Homes in the future. However, large multicenter more robust comparative studies will be required to more fully assess this method before such hopes can be justified.

## REFERENCES

1. <http://www.stat.go.jp/index.htm> Ministry of Internal Affairs and Communications
2. Petros PEP, Richardson PA The TFS posterior sling for repair of uterine/vault prolapse-a preliminary report. Aust N Z J Obstet Gynaecol, 2005; 45: 372-375.
3. Petros PEP, Richardson PA The TFS posterior sling for repair of uterine/vault prolapse-a preliminary report. Aust N Z J Obstet Gynaecol, 2005; 45: 376-379.
4. Petros PEP, Richardson PA, Goeschen K and Abendstein B, The Tissue Fixation System (TFS) provides a new structural method for cystocele repair- a preliminary report. Aust N Z J Obstet Gynaecol, 2006; 46: 474-478.
5. Ulmsten U, Henriksson L, Johnson P, and Varhos G An ambulatory surgical procedure under local anesthesia for treatment of female urinary incontinence, Int Urogynecol J Pelvic Floor Dysfunct.; 1996; 7: 81-86.
6. Petros PE & Ulmsten U, Papadimitriou J, The Autogenic Neoligament procedure: A technique for planned formation of an artificial neo-ligament. Acta Obstetrica et Gynecologica Scandinavica, Supplement 1990; 153, 69, 43-51.
7. Inoue H, Sekiguchi Y, Kohata Y *et al.* Tissue Fixation System (TFS) to repair uterovaginal prolapse with uterine preservation: a preliminary report on perioperative complications and safety. J Obstet Gynaecol Res 2009; 35 (2): 346-353.

8. Wagenlehner FM, Fröhlich O, Bschiepfer T, Weidner W, Perletti G: The Integral Theory system Questionnaire: An anatomically directed questionnaire to determine pelvic floor dysfunctions in women. *World J Urol* 2013; 31: 747-753.
9. Petros PEP, Chapter 3 Diagnosis of Connective Tissue Damage, in *The Female Pelvic Floor, Function, Dysfunction and Management According to the Integral Theory*, Petros PEP, Springer Heidelberg, 2008; 77-117.
- 9a A hypothesis for urinary stream divergence in the female: unilateral dislocation of the pubovisceral muscle Kay U. Scheffler, Peter E. Petros, Oliver W. Hakenberg *Pelvipiperineology* 2014; 33: 10-13.
10. Abendstein B, Petros P. E. P, Richardson P. A. Goeschen K, Doderer D. The surgical anatomy of rectocele and anterior rectal wall intussusception. *Int Urogynecol J* 2008.19, 5; 513-7.
11. Wagenlehner F. M. E., Del Amo E, G. A. Santoro GA and P. Petros, Live anatomy of the perineal body in patients with third-degree rectocele. *Colorectal Disease*, 2013; 15: 1416-1422.
12. Wagenlehner<sup>1</sup>, F. M. E, Del Amo<sup>2</sup>, E., Santoro<sup>3,\*</sup> G. A, Petros<sup>4</sup> P., Perineal body repair in patients with third degree rectocele: a critical analysis of the tissue fixation system, *Colorectal Disease*, Article first published online: 2013; 21 NOV DOI: 10.1111/codi.12453.
13. Bump RC, Mattiasson A, Bo K *et al.* The standardization of terminology of female pelvic organ prolapse and pelvic floor dysfunction. *Am J Obstet Gynecol* 1996; 175: 10-17.
14. Gin-Den ChenMD, Soo-Cheen NgMD Updated definition of female pelvic organ prolapse. *Incont Pelvic Floor Dysfunct* 2007; 1 (4): 121-124.
15. Atherton MJ, Daborn JP, Tsokos N *et al.*; Complications associated with tissue anchor migration after vaginal surgery using the tissue fixation system – a case series. *Aust N Z J Obstet Gynaecol* 2012; 52 (1): 83-86.
16. Petros PEP and Richardson PA The basic science of TFS minisling complications. *Aust N Z J Obstet Gynaecol*, 2012; 52 (1): 83-86.
17. Holm-Larsen T. The economic impact of nocturia *Neurourol. Urodynam.* 2014; 33: S15-S18.
18. Breivik H<sup>1</sup>, Collett B, Ventafridda V, Cohen R, Gallacher D., Survey of chronic pain in Europe: prevalence, impact on daily life, and treatment. *Eur J Pain.* 2006; 10: 287-333. Epub 2005 Aug 10.
19. Stones W, Cheong YC, Howard FM Interventions for treating chronic pelvic pain in women, *Cochrane review*, 2007.
20. Abendstein B, Petros PE, Richardson PA Ligamentous repair using the Tissue Fixation System confirms a causal link between damaged suspensory ligaments and urinary and fecal incontinence. *J. Pelvipiperineology*, 2008; 27; 114-117.

No conflict of interest for any of the Authors.

Correspondence to:

Hiromi Inoue  
E-mail: inoue@shonan.kamakuza.or.jp

ERRATA CORRIGE

In the article published by in *Pelvipiperineology* 2014; 33: 90-92 (P. Petros. Non-linearity, a dilemma and opportunity for clinical research in urogynecology) the correct Figure 2 and its legend are as follows:

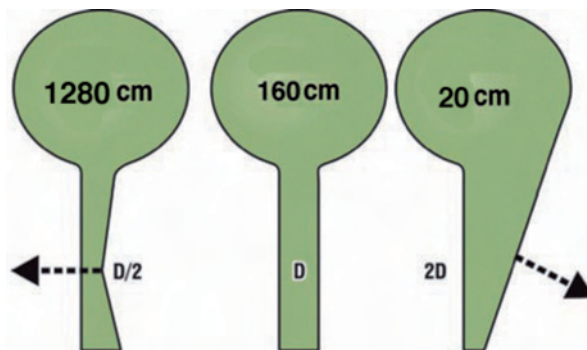


Figure 2. - The non-linear relationship of urethral resistance to continence and micturition (for non-laminar flow). Resting closed (middle figure): 160cm H<sub>2</sub>O is a nominal pressure for leakage at diameter D. For closure (continence) (left figure); if the forward vector can close the diameter to D/2, resistance to flow increases by the 5th power of the radius. The head of pressure required for leakage increases almost to 1280 cm H<sub>2</sub>O. For opening (micturition) (right figure); if the backward vectors can open the diameter to 2D, resistance to flow decreases by the 5th power of the radius. The head of pressure required for leakage decreases to almost 20cm H<sub>2</sub>O.