

Study No. 11: Ligamentous repair using the Tissue Fixation System confirms a causal link between damaged suspensory ligaments and urinary and fecal incontinence

BURGHARD ABENDSTEIN (*) - PETER PETROS (**) - PETER RICHARDSON (***)

(*) Dept of Obstetrics and Gynaecology, Hall, Austria, (**) Royal Perth Hospital, University of Western Australia,

(***) Gallier's Hospital, Armadale, Western Australia

Abstract: AIM. The aims of this study were: 1. To test the efficacy of a less invasive method (TFS) for tape implantation in patients with vaginal prolapse, urinary and fecal incontinence; 2. To test the contribution of ATFP/cardinal and their attached fascia (cystocoele repair), if any, to causation of fecal incontinence. **PATIENTS AND METHODS.** Eighty-one patients, mean age 60.1, mean weight 69 kg (43-112 kg), mean 2.0 previous pelvic operations, underwent 154 site specific operations in the 3 zones of the vagina as primary procedures using the Tissue Fixation System (TFS). The site of operation(s) was determined by reference to a pictorial diagnostic algorithm: pubourethral ligaments, n=43; ATFP, cardinal ligaments, (cystocoele) n = 39; uterosacral ligaments (apical prolapse), n = 72. The patients were assessed with a 24 hour urinary diary, structured questionnaire, transperineal ultrasound, urodynamics, cough stress test, and 24 hour pad test, pre and post-operatively at mean 12 months (6-18 months). **RESULTS.** Symptom improvement was as follows: fecal incontinence (n = 33) 88%, stress incontinence (n = 43) 89%, urgency and nocturia (n = 50) 80%. **CONCLUSIONS.** Both urinary and fecal incontinence (FI) symptoms were simultaneously cured, indicating a causal link. Repair of ATFP and cardinal ligament defects (cystocoele) did not produce a significantly higher cure rate for FI to that achieved by repairing just the anterior and/or posterior suspensory ligaments in studies No 9 & 10, indicating perhaps, the primacy of anterior and/or posterior suspensory ligaments in FI control.

Key words: TFS sling; Prolapse; Stress incontinence; Nocturia; Pelvic pain; Fecal incontinence; Integral Theory.

INTRODUCTION

In 1990 the concept of using a plastic tape to create artificial neoligaments ('tension-free tapes') was introduced.^{1, 2} We have reported how reinforcement of the pubourethral ligament (Study No. 9, this issue) and pubourethral/uterosacral ligaments with anterior/posterior "tension-free" slings successfully improved bladder and bowel symptoms. In 2005 the TFS (Tissue Fixation System) (Fig. 1) was introduced as a safer, less invasive method for inserting plastic slings for use in patients with stress incontinence,³ vaginal prolapse⁴ and cystocoele. Though the principle of artificial neoligament formation² is identical for the "tension-free" and TFS systems, there are important differences. All "tension-free" slings enter vaginally and exit more distally via the skin. The TFS sling is positioned entirely per vaginam. It can be accurately tensioned, and it can be used to repair damaged connective tissue structures in the pelvic floor not accessible to the "tension-free" system, in particular, the pubocervical and rectovaginal fascia, cardinal ligaments, and Arcus Tendineus Fascia Pelvis.

The aims of this study were

1. To test the efficacy of the less invasive TFS method for tape implantation in patients with vaginal prolapse, urinary and fecal incontinence.

2. To examine the contribution, if any, of middle zone fascial defect (cystocoele repair) to fecal incontinence.

Ethics Committee approval was obtained from the Royal Perth Hospital for these operations.

PATIENTS, MATERIALS AND METHODS

Eighty-one patients, mean age 65 (range 35-87), parity 2.7 (range 0-8) weight 69 kg (43-112kg) mean age 60.1 years, (33-88) parity 2.6 (0-8) had one or more surgeries performed simultaneously. Mean number of previous pelvic floor operations (including hysterectomy) was 2.0 per patient (range 0-10 operations). Only 23 patients had not had prior surgery. Forty-four patients (54%) had undergone prior hysterectomy. A single shot antibiotic consisting of amoxicillin and clavulanic acid was given intravenously on induction

of anaesthesia in all operations. In 12 (14.8%) of patients, the operations were performed under local anaesthesia/sedation.

Pre-operative assessment. The patients completed a structured questionnaire, 24 hour urinary diary, cough stress test, and 24 hour pad test. The symptoms were checked against the diagnostic algorithm (Fig. 2) to indicate the zone of connective tissue damage, anterior, middle, posterior. Vaginal examination,⁶ involved inspection for damage to 9 potential structures (Fig. 2). Transperineal ultrasound and urodynamic testing were also performed. In some patients with urinary urge symptoms, the office technique of "simulated operations"^{6,7} was used to achieve a more accurate diagnosis, as laxity in any zone (Fig. 3) may cause stress or urge symptoms.

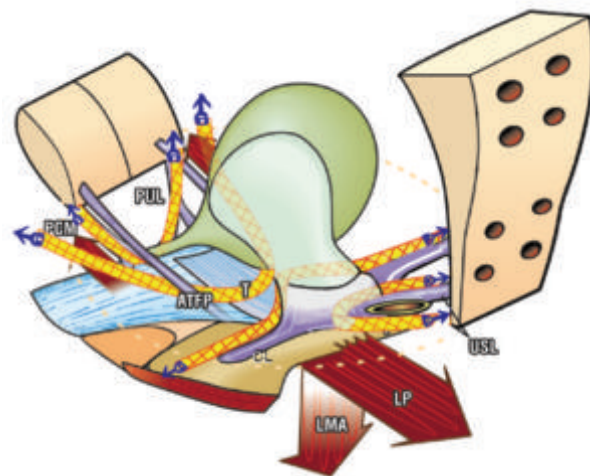


Fig. 1. – TFS anchor. The polypropylene tape is applied under direct vision, using the anchor to fix it adjacent to the damaged ligament or fascia: pubourethral (PUL), arcus tendineus fascia pelvis (ATFP), cardinal ligament (CL), uterosacral (USL). A one-way tightening mechanism at the base of the anchor tensions the tape to restore optimal length, and therefore function, of the damaged structure.

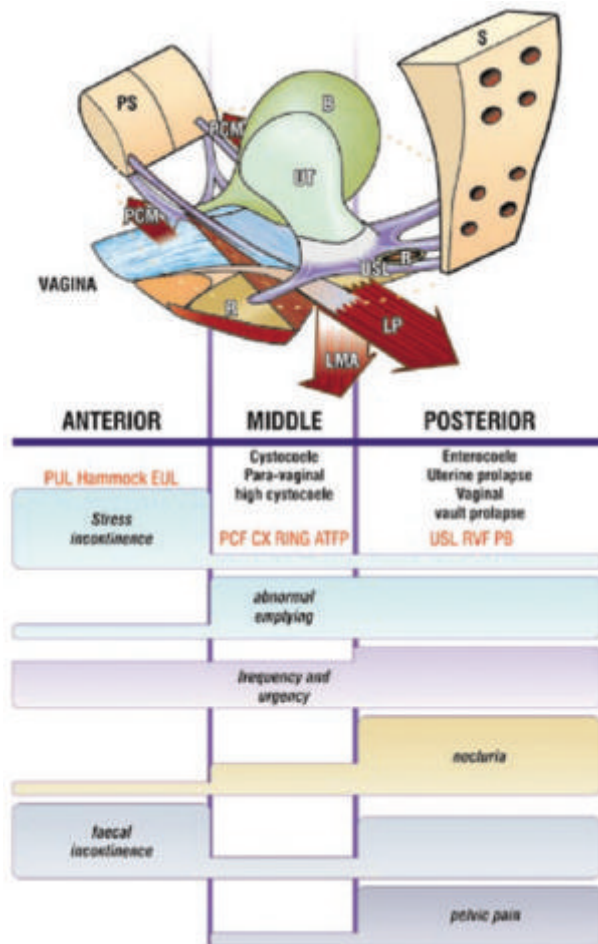


Fig. 2. – The Pictorial Diagnostic Algorithm was used to determine where the TFS tapes were to be applied. The algorithm summarizes the relationships between connective tissue damage in the three zones and symptoms. The size of the bar gives an approximate indication of the prevalence (probability) of the symptom. Connective tissue structures in each zone may cause prolapse and abnormal symptoms.

The patients were monitored at 6 weeks, and at 3 monthly intervals thereafter using a 24 hour urinary diary, structured questionnaire, cough stress test, 24 hour pad test, transperineal ultrasound and, where possible, urodynamic investigation.

Criteria for symptomatic improvement post-operatively were: stress incontinence: no urine loss during 10 coughs with a full bladder; nocturia: <2 episodes per night; urge incontinence (UI): self-assessed improvement expressed as a VAS percentage; faecal incontinence (FI) :>80% VAS improvement. The threshold for FI diagnosis was one soiling /day.

The anterior TFS sling operation (n = 43). The surgical technique for the anterior TFS sling³ is almost identical to that for the “tension-free tape” operation, except that the anchors insert on the under surface of the pelvic muscles (Fig. 3), and the tape is tightened via a one-way trapdoor at the anchor base.

Operation. Midline incision to midurethra; vagina dissected off the urethra; penetration of the urogenital diaphragm to a depth of 1 cm by the TFS applicator; release of the TFS anchor; procedure repeated on the contralateral side; tape tensioned over an intraurethral 18G Foley catheter; free ends of tape trimmed; vaginal hammock fascia and the external ligaments tightened with 2-0 Dexon sutures; no cystoscopy. Mean operating time was 5 minutes.

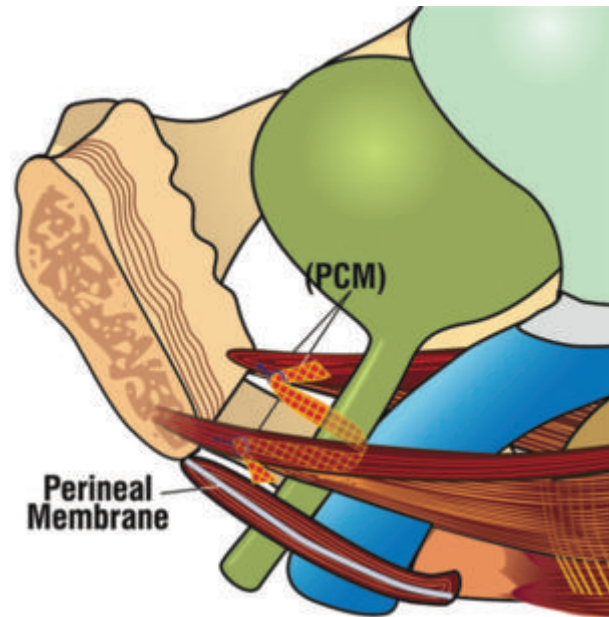


Fig. 3. – Anterior TFS sling. 3D sagittal view. A polypropylene mesh tape sited at midurethra and attached in the pelvic muscles below pubic symphysis (PS) reinforces the pubourethral ligament.

The posterior TFS sling. Primary uterosacral ligament (USL) repair⁴ was undertaken in 72 patients. The posterior TFS sling anchors the apical fascia into the uterosacral ligaments ‘USL’ (Fig. 4), much like a McCall operation.

Operation: Full thickness, 2.5cm transverse incision was made in the vaginal apex, 2 cm below the cervix, or just below the hysterectomy scar; uterosacral ligament remnants grasped with Allis forceps; fine dissecting scissors created a 4-5 cm space adjacent to the USL remnants; applicator inserted into the space; anchor was released and “set” by tugging on the tape; insertion was repeated contralaterally, and tape tightened; tapes trimmed; approximation of rectovaginal fascia as an extra layer to support the tape. Mean operating time 10 minutes.

Rectovaginal fascia and perineal body repair were carried out without any tissue excision. The fascial remnants of the rectocele and perineal body were repaired in 40 patients.

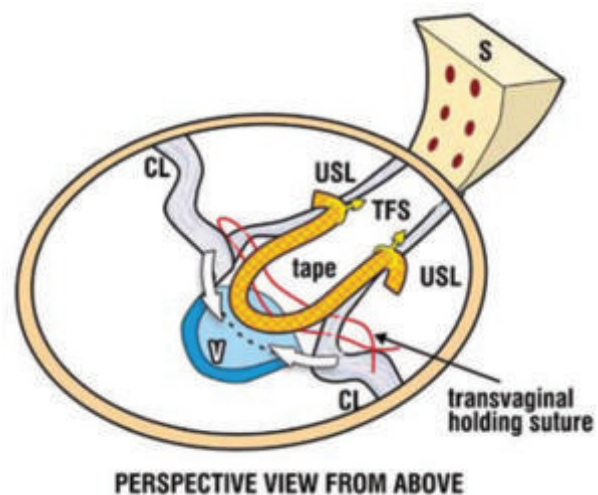


Fig. 4. – Posterior TFS sling. The tape is inserted along the line of the uterosacral ligaments “USL” between USL and vagina “V”. CL=cardinal ligament. The suture approximates the fascia overlying the tapes.

Middle zone repair (cardinal and ATFP ligaments). A different bioengineering principle is applied to that of large mesh. The tapes act like beams of a ceiling, and the vagina like a plaster board to support the prolapsed bladder wall. Unlike large meshes which only create a barrier to an organ herniation, the TFS tapes restore fascial and ligamentous tension by precise tightening of the tape. The correct tension is reached once a resistance is felt. This resistance is probably caused by muscle contraction against the fascia, according to Sturmdorf's 1919 description, "the levator ani is the tensor of the pelvic fascia".⁵

There were 48 primary operations for midzone repair (39 TFS) (Tab. 1).

Standard cystocele repair (n = 9). The vagina was dissected off the bladder without tissue excision and the overly-

TABLE 1. – Structural outcome for primary cystocele/anterior wall repair.

n = 48		
3 rd Degree n = 26		2 nd Degree n = 22
Operation	Patient No	Recurrence
Vaginal repair	9	4
Transverse TFS	22	1
TFS "U" sling	17	1

TABLE 2. – Structural outcome for primary posterior zone repair.

4 th degree: n=4. 3 rd degree: n=18. 2 nd degree: n=20. 1 st degree: n=30			
Operation	Patient No	Recurrence	
Posterior TFS	72	1	

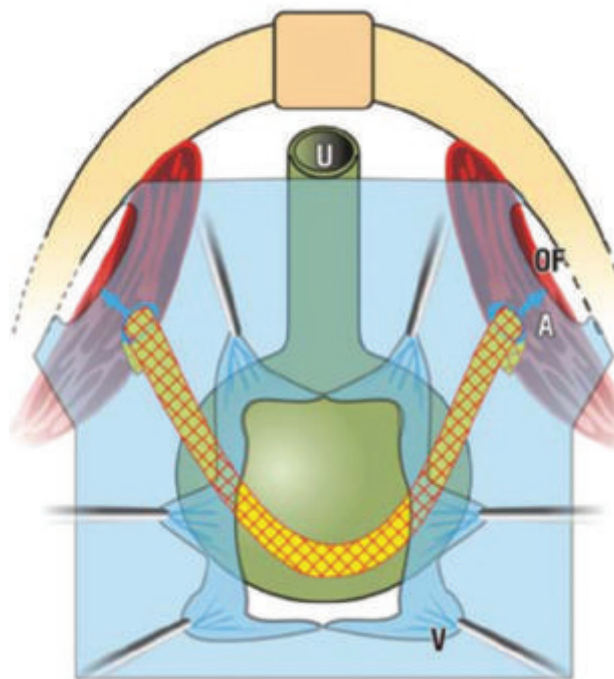


Fig. 5. – TFS "U sling"-View into the anterior vaginal wall. Vagina (V) is dissected off the bladder wall, and stretched laterally. The TFS tape is anchored (A) just medial to the obturator fossa (OF) muscles. Sutures (S) may be used to attach the tape to the vaginal fascia.

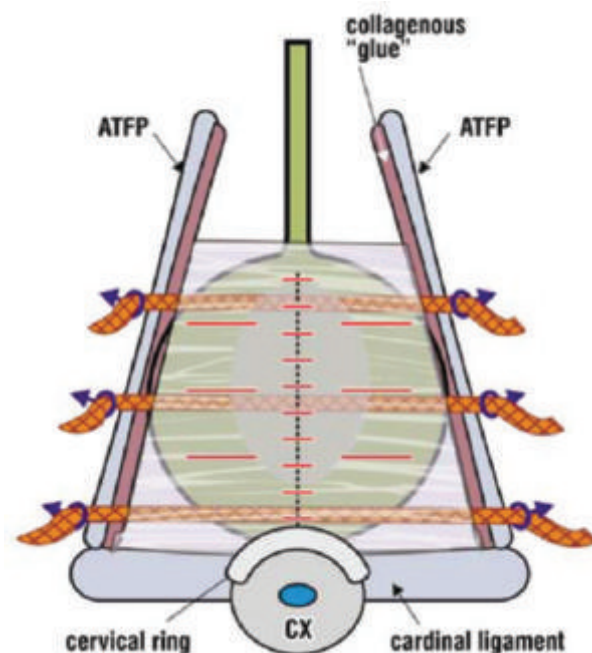


Fig. 6. – Transverse TFS Sling The bladder was dissected from the vaginal wall as laterally as possible. After repair of the fascial fragments, the anchor was attached to the ATFP (Arcus tendineus Fascia Pelvis) or adjoining muscle and tightened. The inferior tape reinforces the cardinal ligament.

ing fascial remnants repaired. This operation was discarded early in the trial because of the poor results (4/9 failures). Subsequently, tapes were used in every instance.

TFS "U sling" (Fig. 5) (total n = 17). The surgical principle was to mimic the arcus tendineus fascia pelvis (ATFP), and to reinforce centrally weakened pubococcygeus fascia. Bladder wall was dissected off the vagina; dissection channel was created to just medial to the obturator fossa; fascial remnants were approximated; TFS was inserted into the channel, the anchor displaced and set. This operation was repeated contralaterally. The tape was tightened just sufficiently to reduce fascial laxity.

Transverse TFS tapes (total n =22). The bladder was dissected off the vagina; the overlying fascial remnants were repaired; one two or three anchors were positioned into the lateral ligamentous tissues (ATFP) as required, and the tapes were tightened (Fig. 6).

RESULTS

General. Eighty-one patients, mean age 60.1 years, underwent 154 TFS operations in the 3 zones of the vagina as primary procedures. These were anterior zone (pubourethral ligament) n = 43, middle zone (ATFP and cardinal ligament) n = 39, posterior zone (uterosacral ligaments) n = 72. Mean hospital stay was 2.5 days (1-10 days). Mean post-operative review time was 12 months (range 6-18).

Post-operative course. In patients who had not undergone perineal body repair, only 2 required opiates post-operatively. Most patients were managed simply with paracetamol. Many patients who had previously undergone "tension-free tape" operations, reported a significant difference in post-operative pain and discomfort, an observation echoed by the recovery room and ward staff. Six patients (7%) developed urinary tract infection within 4 weeks of discharge and these were treated with antibiotics.

There were no cases of post-operative retention, haematoma or infection. All patients passed urine spontaneously.

Structural. Results are summarized in Tables 1 & 2. Two failed cystocele repairs were successfully re-operated with the U-sling TFS. There was one failure of vault prolapse repair, and evidence of rectocele / perineal body recurrence in 4 patients.

Symptomatic. All 33 patients with fecal incontinence had intact external anal sphincters, and were classified as having idiopathic fecal incontinence (FI). Symptomatic improvement >80% was noted in 88% of these patients for FI, 89% for stress incontinence (n = 43), and 80% for urgency and nocturia (n = 50). No erosions or dyspareunia have been reported to date.

DISCUSSION

The improvement rate for fecal incontinence using the TFS was equivalent to that reported for “tension free” anterior and posterior sling surgery (Studies No 9 & 10, this issue), and previously for other pelvic symptoms.⁸⁻¹⁰ This indicates that the TFS can be used as a safer and equally effective substitute for “tension free” sling surgery, especially in the old and infirm.

This study differed from studies No 9 & 10, in that middle zone ligamentous defects (cystocele) were also repaired. This extra operation did not appear to significantly improve the FI cure rate, indicating, perhaps, that the AFTP and cardinal ligaments (Fig. 3), may not be a significant cause of FI.

Even patients considered as gross failures in one area (e.g., urge incontinence) had cures in other areas (e.g., fecal incontinence, stress incontinence, urgency/nocturia). This appears to support the anatomical classification (Fig. 3), whereby some symptoms such as stress incontinence and nocturia may be largely zone specific, while others such as urge incontinence may occur across any zone.

The longer-term efficacy for FI cure by the TFS has not as yet been assessed. Recent data for stress incontinence indicates minimal deterioration at 3 years.¹¹

CONCLUSIONS

The TFS appeared to work as efficiently as the “tension-free tape” slings, but with greater safety and less invasiveness. Therefore it is especially applicable to aged and frail patients. Both urinary and fecal incontinence symptoms were simultaneously cured by suspensory ligament recon-

struction, indicating a causal link. It does not appear likely that the middle zone ligaments, AFTP and cardinal, play a major role in FI control.

REFERENCE

1. Petros PE & Ulmsten U. An Integral Theory of Female Urinary Incontinence, Acta Obstet Gynecol Scand. 1990; Suppl No 153: 1-79.
2. Petros PE, Ulmsten U and Papadimitriou J. The Autogenic Neoligament procedure: A technique for planned formation of an artificial neo-ligament. Acta Obstet Gynecol Scand 1990; 69: Supp. 153: 43-51.
3. Petros PEP, Richardson PA. The midurethral TFS sling - a ‘micro-method’ for cure of stress incontinence - preliminary report. ANZJOG 2005; 45: 372-375.
4. Petros PEP, Richardson PA. The TFS posterior sling for repair of uterine/vault prolapse-a preliminary report. ANZJOG 2005; 45: 376-379.
5. Sturmdorf A. The levator ani muscle. In: Gynoplastic Technology, FA Davis, Philadelphia 1919: 109-114.
6. Petros PEP. The Female Pelvic Floor, Function, Dysfunction and Management, according to the Integral Theory. Springer Heidelberg, Ch 2, 3 & 4, Diagnosis of Connective Tissue damage, Surgery 2004; 14-138.
7. *idem*, Ch 6, Dynamic Mapping with ‘simulated operations: a clinical example, 169-175.
8. Petros PE. New ambulatory surgical methods using an anatomical classification of urinary dysfunction improve stress, urge, and abnormal emptying. Int J Urogynecology 1997; 8: 270-278.
9. Farnsworth BN. Posterior Intravaginal Slingplasty (infracoccygeal sacropexy) for severe posthysterectomy vaginal vault prolapse - a preliminary report. Int J Urogynecol 2002; 13: 4-8.
10. Ulmsten U, Henriksson L, Johnson P, and Varhos G. An ambulatory surgical procedure under local anesthesia for treatment of female urinary incontinence. Int Urogynecol J 1996; 7: 81-86.
11. Petros PE, Richardson PA. Midurethral Tissue Fixation System (TFS) sling for cure of stress incontinence - 3 year results. International J Urogynecology 2008; in press.

Competing Interests: the 2nd author (Petros) has an interest in the IP of the TFS instrument.

Correspondence to:

PETER PETROS

E-mail: kvinno@highway1.com.au