

# The same posterior muscle vectors act to open urethra and anus during micturition and defecation

PETER E. PETROS<sup>1</sup>, MARK B. BUSH<sup>2</sup>

<sup>1</sup> University of NSW, St Vincent's Hospital, Sydney, Australia

<sup>2</sup> School of Mechanical and Chemical Engineering, The University of Western Australia

**Abstract:** The generally accepted mechanism for micturition and defecation is that the pelvic floor muscles relax, detrusor contracts, urine and feces are expelled. To our knowledge, no EMG or imaging proof has ever been offered to validate this mechanism. X-ray and EMG evidence presented here confirms an alternative hypothesis, that only the forward acting pelvic muscles relax prior to micturition, m.pubococcygeus for micturition and m.puborectalis for defecation; prior to detrusor contraction, the same backward acting muscle vectors contract against competent uterosacral ligaments (USL) to open out the posterior urethral wall and anorectal angle. This exponentially decreases the internal resistance to fecal and urine flow. If USLs are loose, this mechanism weakens and the patient may complain of evacuation difficulties for bladder, bowel or both. Shortening and reinforcing the USLs has been demonstrated to reverse this cascade of events to cure the evacuation dysfunctions.

**Key words:** Micturition; Defecation; Pelvic muscle contraction; Frictional resistance.

## BACKGROUND

The generally accepted mechanism for micturition is that the pelvic floor relaxes, detrusor contracts, urine is expelled. To our knowledge, no EMG or imaging proof has ever been offered to validate this mechanism. In their Standardization of terminology report in 2005, The International Continence Society<sup>1</sup> stated that the pelvic floor muscles must relax in order to remove the passive continence mechanisms, thereby favouring normal micturition.

The mechanics of defecation and fecal continence are similarly poorly understood. Valvular theories for continence<sup>2</sup> rely on raised intra-abdominal pressure to force the anterior wall of the rectum downwards to close off the anorectal junction.

An understanding of the mechanisms of normal micturition and defecation is a pre-requisite for understanding organ evacuation dysfunction. One case in point is voiding dysfunction following the Burch colposuspension<sup>3</sup>. Unlike a sling, there is no discrete point of obstruction with the Burch. Using Hegar dilators, urethral stricture is rarely found in surgery naive patients with "outflow obstruction". We believe that the answer to these questions is the exponentially determined urethral resistance which is instantaneously modified by an external striated muscle mechanism first described in 1990<sup>4</sup>. Neither is there any obvious mechanical obstruction in patients with obstructive defecation syndrome (ODS).

## MECHANISM OF MICTURITION AND DEFECATION

This external opening mechanism, since validated with EMG and video x-ray studies<sup>5-7</sup> stretches open the posterior urethral and anal walls (Figs. 1,3) and is in turn dependent on competent suspensory ligaments<sup>4</sup>. The external opening mechanism for the urethra was described as follows: "*immediately prior to commencement of voiding, the forward closure vector (m.pubococcygeus) relaxes; relaxation of m.pubococcygeus releases the closure pressure of the hammock on the posterior urethral wall, thereby freeing the posterior vectors (levator plate and the conjoint longitudinal muscle of the anus) to actively open the urethra prior to*

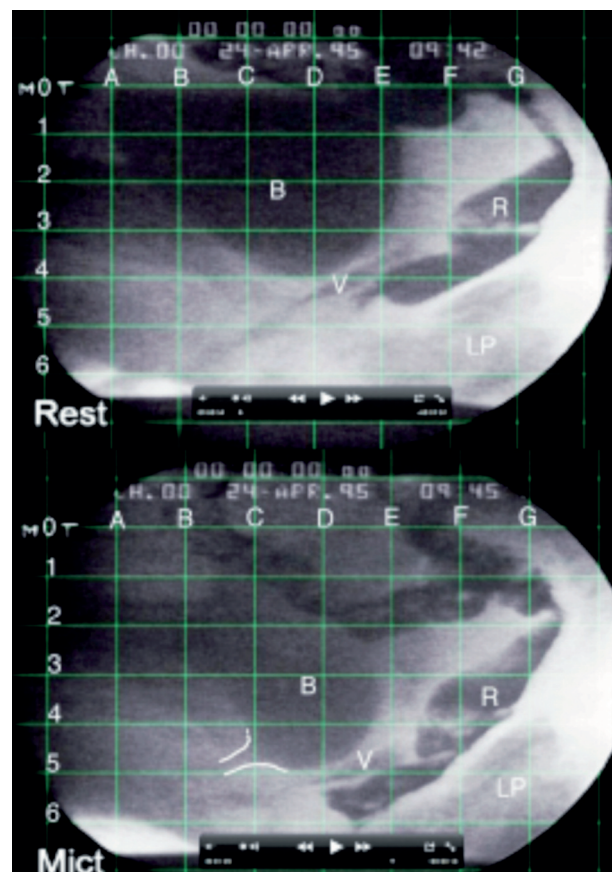


Figure 1. –Active opening of the urethra.

The upper X-ray is at rest. The lower X-ray was taken during micturition. Dye has been injected into bladder 'B', vagina 'V', rectum 'R', levator plate 'LP'. The grid allows direct comparison of organ movement during micturition. LP is seen to insert in to the posterior wall of rectum. *Micturition:* The bladder base, vagina and rectum have been pulled down from level 4 to level 5, apparently by contraction and downward angulation of the levator plate.

*detrusor contraction, exponentially lowering the resistance to flow immediately prior to the expulsive action of the detrusor*"<sup>4</sup>.

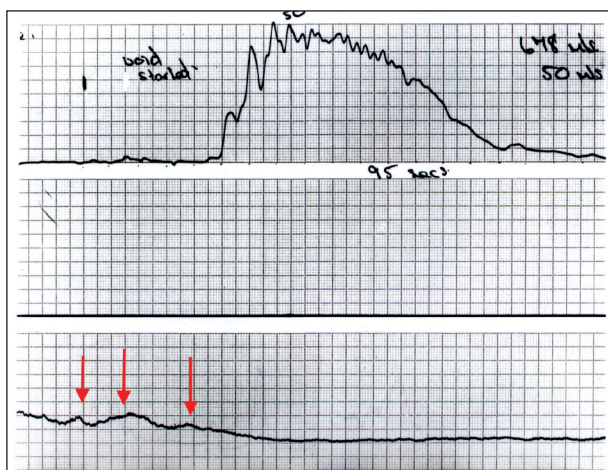


Figure 2. –Active opening of the urethra-normal patient. The EMG probe was placed in the posterior fornix of the vagina. The arrows indicate commencement of muscle contraction in the region of the posterior fornix of vagina well before micturition commences, indicating active opening of the urethra. Note disappearance of muscle activity once flow commences. The reason for this is that urine is incompressible, so while there is urine flow, the urethra remains open.

The pattern of defecation (Figures 3a,3b ) was described as follows<sup>7</sup>:

*“backward movement of the upper part of the anorectum and forward movement of its lower part effectively opened and straightened the anorectal tube to at least double its resting diameter. The rectum emptied in one bowel movement, and feces can be seen moving downwards along the posterior wall of the rectum.”* Fundamental to this mechanism is the prior relaxation of the forward vector, m.puborectalis<sup>7</sup>.

The mechanisms of micturition and defecation are remarkably similar. Both are opened out by the posterior vector forces which act backwards and downwards, levator plate (LP) and longitudinal muscle of the anus (LMA) (Figures 1,3). Both mechanisms require relaxation of a forward retaining vector, m.pubococcygeus for micturition and m.puborectalis for defecation.

An essential consequence of this mechanism is the cascade of events dependent upon the keystone of this mechanism, the uterosacral ligament: the downward opening vector contracts against the uterosacral ligament (USL); in the USL, if the insertion of the downward vector force is loose, the vector forces weaken<sup>8</sup>; the vectors cannot open out the posterior urethral wall or posterior anal wall; the detrusor contracts against an unopened urethra/anus and therefore, a high internal resistance to flow is encountered for both urine and feces; the patient will have bladder/bowel emptying difficulties because of greatly increased resistance to flow<sup>9-10</sup>.

It follows that the cascade of events which leads to these voiding dysfunctions is potentially reversible by surgical strengthening of the uterosacral/cardinal ligament complex by insertion of polypropylene tapes<sup>11</sup>. Studies showed a marked improvement in bladder and bowel evacuation problems following reconstruction of the uterosacral ligaments<sup>11</sup>.

An active mechanism explains the inability of spinal cord patients to micturate spontaneously, and the almost invariable finding of a normal urethra and anus in patients with ‘obstructive evacuation’. The ‘obstruction’ is functional not anatomical, contraction of the detrusor against an anatomically normal, but insufficiently opened urethra/anus.

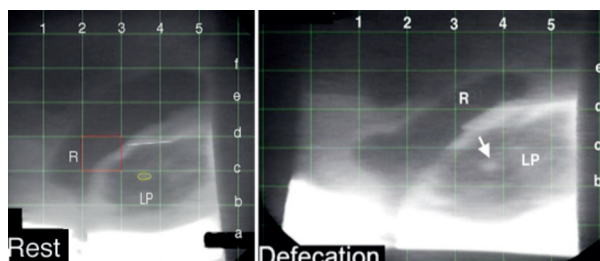


Figure 3. –Proctogram taken from a video of defecation. Radioopaque dye has been injected into the rectum ‘R’ and levator plate ‘LP’.

*At rest:* The rectum “R” is resting on LP with a well-defined anorectal angle (about 110 degrees) situated just above horizontal line ‘c’. Yellow circle is a defect in LP .

*Defecation:* The rectum and anorectal angle have descended to lie just above the horizontal line ‘b’; the anorectal angle has opened to almost 180 degrees; the anterior rectal wall has been pulled forwards beyond the vertical line ‘1’; The anorectum has been opened out very significantly, at least to twice its resting diameter. In the video, the feces appear to run down the posterior wall of rectum. The circular defect in LP, has moved down and back (arrow), consistent with backward/downward opening muscle vector forces actively opening out the anorectum.

DISCLOSURES

No conflicts either author.

Contributions: Figures, Peter Petros. Both authors contributed to analysis of the figures, to their interpretation and the writing of the manuscript.

REFERENCES

- Messelink B, Benson T, Berghmans B et al. Standardization of terminology of pelvic floor muscle function and dysfunction: report from the pelvic floor clinical assessment group of the International Continence Society. *Neurourol Urodyn.* 2005; 24 (4): 374-80.
- Parks AG. Anorectal incontinence. *Proc Royal Soc Med* 1975; 68: 681-90.
- Burch J. Urethrovaginal fixation to Cooper’s ligament for correction of stress incontinence, cystocele & prolapse. *American Journal Obstets & Gynecol.*, 1961; 81; 2, 281.
- Petros PE & Ulmsten U. An Integral Theory of female urinary incontinence. *Acta Obstetricia et Gynecologica Scandinavica*, Supplement 153, 1990; 69; 1-79
- Petros P, Ulmsten U. Role of the pelvic floor in bladder neck opening and closure: I muscle forces. *Int J Urogynecol and Pelvic Floor.* 1997; 8: 74-80.
- Petros P, Ulmsten U. Role of the pelvic floor in bladder neck opening and closure: II vagina. *Int J Urogynecol and Pelvic Floor.* 1997; 8: 69-73.
- Petros P, Swash M, Bush M et al. Defecation 1 – Testing a hypothesis for pelvic striated muscle action to open the anorectum. *Techniques in Coloproctology* 2012 DOI 10.1007/s10151-012-0861-2
- Gordon AM, Huxley AF, Julian FJ. The variation in isometric tension with sarcomere length in vertebrate muscle fibres. *J Physiol.* 1966; 184 (1): 170-92.
- Bush MB, Petros PE, Barrett-Lennard BR. On the flow through the human urethra. *J Biomechanics.* 1997; 30 (9): 967-9.
- Bush M, Petros P, Swash M et al. Defecation 2: Internal anorectal resistance is a critical factor in defecatory disorders. *Techniques in Coloproctology* 2012 DOI 10.1007/s10151-012-0860-3
- Petros PEP, Richardson PA. TFS posterior sling improves overactive bladder, pelvic pain and abnormal emptying, even with minor prolapse – a prospective urodynamic study. *Pelviperrineology* 2010; 29: 52-55.

Correspondence to:

Email pp@kvinno.com - mark.bush@uwa.edu.au