

Editorial

A NEW THEORY OF ANO-RECTAL FUNCTION

This issue of Pelviperineology has been dedicated entirely to a substantive work by Petros, Swash and their collaborators, which explains anorectal function based on a musculo-elastic theory. The concepts are developed from the Integral Theory of Petros and Ulmsten which provides an anatomic explanation for a number of functional disorders of the lower urinary tract in women. Petros has been a colourful and controversial figure since he challenged the basis of our knowledge regarding the bladder and launched the “Tension Free Sling” when he and Ulmsten presented the “intravaginal slingplasty” in 1990.

The suburethral sling in various forms has become the so called “gold standard” for treatment of urinary stress incontinence. Many surgeons are unaware of the scientific basis of the procedure that they perform and others are aware but do not subscribe to the theory. One of the consequences of the publication of the Integral Theory has been the resurgence of interest in the anatomy and physiology of pelvic function with new societies and journals appearing. This has led to increasing awareness by doctors of the shared nature of the anatomy and physiology between the three compartments of the pelvis and renewed interest on the part of urologists, gynaecologists and colorectal surgeons in developing better interventions to address these problems. Whilst colorectal surgeons have long used their own techniques in the treatment of ano-rectal prolapse and faecal incontinence, the emergence of new vaginal surgery procedures has led to new opportunities for collaboration.

We anticipate that this work will create a new controversy and we are pleased to present it in this journal. We know that it will generate an interesting discussion but only time will tell whether these papers will become as influential and groundbreaking as the Integral Theory of urinary incontinence. A number of experts have been asked to comment on this work and the first of their responses is published in this issue. Readers are also invited to submit correspondence concerning this matter for publication in future editions of the journal.

This issue of the journal has been published in time to distribute to attendees at the Pelvic Surgery Congress held in Padua and Venice between September 30th and October 4th. In the next few months we hope to announce increased collaboration with other pelvic societies and an expansion of the Editorial Advisory Board. Pelviperineology will continue to strive to develop a multidisciplinary culture in pelvic floor medicine. We can all learn from each other and we have to try to replace opinion with science as we go forward together.

THE EDITORS

PELVIPERINEOLOGY

A multidisciplinary pelvic floor journal

Pelviperineology is published quarterly. It is distributed to clinicians around the world by various pelvic floor societies. In many areas it is provided to the members of the society thanks to sponsorship by the advertisers in this journal.

SUBSCRIPTIONS: If you are unable to receive the journal through your local pelvic floor society or you wish to be guaranteed delivery of the journal Pelviperineology then subscription to this journal is available by becoming an International Member of AAVIS. The cost of membership is € 75,00 and this includes airmail delivery of Pelviperineology. If you wish to join AAVIS visit our website at www.aavis.org and download a membership application.

The aim of Pelviperineology is to promote an inter-disciplinary approach to the management of pelvic problems and to facilitate medical education in this area. Thanks to the support of our advertisers the journal Pelviperineology is available free of charge on the internet at www.pelviperineology.org The Pelvic Floor Digest is also an important part of this strategy. The PFD can be viewed in full at www.pelvicfloordigest.org while selected excerpts are printed each month in Pelviperineology.

Foreword

A Musculo-Elastic Theory of anorectal function and dysfunction in the female

PETER PETROS^(*) - MICHAEL SWASH^(**)

^(*) Royal Perth Hospital, University of Western Australia

^(**) Dept of Neurology, The Royal London Hospital, London, UK

The Theory states: "Anorectal dysfunction in the female is mainly caused by lax suspensory ligaments inactivating anorectal muscle forces".

FOREWORD

We present a series of 13 works in 2 parts. Part 1 states the Theory, and presents 7 works which test core aspects of the Theory, in particular, the role of the suspensory ligaments and muscle forces. Part 2 directly challenges the Theory with 5 different surgical works which track the fate of anorectal and other pelvic symptoms following repair of specific suspensory ligaments and their related fascia.

In this series of papers, we bring together two apparently divergent concepts for the causation of fecal incontinence in the female, the muscle damage theory, and the ligament/connective tissue damage theory. Data from a blinded muscle biopsy/midurethral sling study provided the key to our theory. It indicated that where there are lax ligaments, there were also histological pattern of muscle damage due to several different mechanisms. The implications of these findings are that (1) Lax ligaments will cause muscle dysfunction by unloading the relevant muscles, as in tenotomy, and (2) This muscle dysfunction is potentially reversible by surgical reinforcement of the damaged ligament, even when there are major changes histologically in the pelvic floor muscles.

HISTORICAL BACKGROUND

In 1990 the Integral Theory of urinary incontinence suggested that stress and urgency both derived from laxity in the vagina or its supporting ligaments.¹ The initial focus was on correcting stress urinary incontinence with a midurethral sling. In 1993 the theory was expanded to include abnormal bladder emptying, nocturia, and pelvic pain,² a consequence of uterovaginal prolapse. These functional problems, including prolapse, were cured or substantially improved after a posterior sling procedure.³ Though the focus at the time was on urinary dysfunction and pelvic pain, repeated voluntary anecdotal statements by patients that their fecal incontinence had also been cured, as well as their stress urinary incontinence by the slingplasty procedure created the impetus for a prospective systematic study. In 1997, simultaneous cure of urinary stress (88%) and idiopathic fecal incontinence (100%) was reported at 6 month review in a group of 25 patients with a midurethral sling.⁴ Three of these patients were nulliparous. Endoanal ultrasound examination by a radiologist skilled in the procedure found that the external anal sphincter appeared of normal thickness and consistency in all these patients, and the internal anal sphincter appeared normal in 72%. Subsequently 6 patients from this group developed uterine prolapse, with recurrence of FI in 3 of those patients. In those 3 patients, the prolapse, and fecal incontinence were cured with a posterior sling. We concluded that the pathogenesis of FI was similar to that suggested for stress urinary incontinence:^{1,2} that is, ligamentous laxity in the suspensory ligaments of the vagina,

disabled the anorectal closure mechanism by impairing the three directional muscle forces, the anterior portion of pubococcygeus (PCM), levator plate (LP), longitudinal muscle of the anus (LMA), that function in concert with the puborectalis muscle (PRM) to close the anorectal angle and so to maintain continence (Fig 1). It had been previously demonstrated,^{1,2,5} that pubococcygeus (PCM) and levator plate (LP) contraction tensed the the pubourethral ligament (PUL) (Fig. 1), and LP and LMA contraction tensed the uterosacral (USL) suspensory ligaments of the vagina (Fig. 1). It was concluded therefore that the sling procedure worked by creating an artificial collagenous neoligament⁶ in the position of PUL and USL (Fig. 1). This restored the three muscle vectors (arrows, Fig. 1) acting against these ligaments, and therefore, facilitated the anorectal closure mechanism and continence.

Though these findings emphasized the role of connective tissue (in particular, collagen) they did not invalidate a role for pelvic muscle damage in the causation of fecal incontinence (FI), as these muscles form an essential and integral part of the anorectal closure mechanism. All striated muscles in the body act against ligaments and the pelvic floor muscles are not exceptional in this regard. The elastic liga-

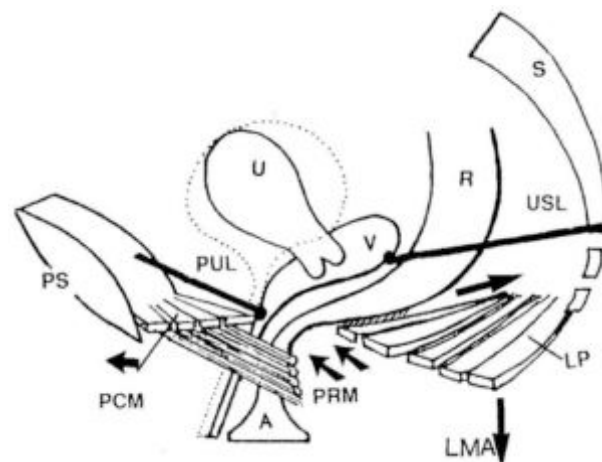


Fig. 1. – Bladder neck and anorectal closure. The same directional muscle forces contract against the suspensory ligaments PUL (pubourethral ligament) and USL (uterosacral) to create bladder neck and anorectal closure. Schematic 3D representation with the anorectal angle in the closed position. The middle part of pubococcygeus muscle has been cut away to reveal the underlying puborectalis muscle (PRM). Arrows=directional muscle forces. PCM= anterior portion of pubococcygeus muscle; LP=levator plate; LMA=longitudinal muscle of the anus; PS=pubic symphysis; S=sacrum; U=uterus; A=anus; V=vagina; R=rectum. The bladder is represented by dotted lines. (Petros,⁴ by permission, Int J Urogynecol).

The Musculo-Elastic Theory of anorectal function and dysfunction

PETER PETROS^(*) - MICHAEL SWASH^(**)

^(*) Royal Perth Hospital, University of Western Australia

^(**) Dept of Neurology, The Royal London Hospital, London, UK

Abstract: The Musculoelastic Theory of anorectal function and dysfunction states “Anorectal dysfunction in the female is mainly caused by lax suspensory ligaments inactivating anorectal muscle forces”. *Anorectal closure.* The rectovaginal fascia inserts into perineal body, levator plate (LP) and the uterosacral ligaments. Contraction of levator plate stiffens rectovaginal fascia and both walls of rectum. Contraction of longitudinal muscle of the anus (LMA) against the uterosacral ligaments stretches the rectum around a contracted puborectalis muscle, to create the anorectal angle and closure. *Defaecation.* Puborectalis relaxes. Posteriorly acting LMA/LP vectors open out the anorectal angle; forward contraction of the pubococcygeus vector stiffens the perineal body, and anterior wall of anus; the rectum empties. *Pathogenesis.* Is similar to that described by the Integral Theory 1 for urinary incontinence: damaged ligaments decrease the force of opening and closure vectors. *Surgery according to this theory.* Reinforcement of damaged ligaments with precisely implanted polypropylene tapes restores structure and function.

Key words: Fecal incontinence; Constipation; Ligament laxity; Connective tissue; Anatomy; Integral Theory.

EXISTING CONCEPTS FOR NORMAL ANORECTAL FUNCTION.

The mechanics of defecation and fecal continence are poorly understood. Valvular theories for continence² rely on raised intra-abdominal pressure to force the anterior wall of the rectum downwards to close off the anorectal junction. Such theories are not consistent with EMG and radiological data which suggest a striated muscle sphincteric mechanism.³ It has been demonstrated that puborectalis and external anal sphincter muscles contract during effort, indicating a role for both in fecal continence.⁴ The internal anal sphincter is also said to be important for feces continence.⁵ The mechanism of defecation is even more poorly understood. According to one description,³ feces enter the anal canal, stimulate stretch receptors and produce the urge to defecate. The internal and external anal sphincters relax, decreasing the pressure within the anus. The rectum contracts and with the assistance of raised intraabdominal pressure (Valsalva) expels the feces. Shafik⁶ suggested an active muscular mechanism for anorectal opening and closure. In his proposal, during straining, the puborectalis, acting as the upper part of a triple loop system, contracts to close off the anal canal. No role is assigned by Shafik for levator plate contraction during anorectal closure. According to Shafik, during defecation, the puborectalis muscle relaxes, the levator plate contracts, and the “suspensory sling” lifts upwards to open out the anorectal canal prior to evacuation by rectal detrusor contraction.

MAJOR EXISTING HYPOTHESES FOR CAUSATION OF FECAL INCONTINENCE (FI)

Major hypotheses advanced for fecal incontinence causation include damage to the external anal sphincter (EAS), stretch-related pudendal nerve damage⁷ and internal anal sphincter (IAS) injury.⁵ These causes are by no means exhaustive. Bharucha,⁸ in a recent review article quoted the following causes: *Anal sphincter weakness Injury:* obstetric trauma; *Related to surgical procedures* (e.g., hemorrhoidectomy internal sphincterotomy, fistulotomy, anorectal infection); *Nontraumatic:* scleroderma, internal sphincter thinning of unknown cause; *Neuropathy stretch injury:* obstetric trauma, diabetes mellitus; *Anatomical disturbances of pelvic floor:* fistula, rectal prolapse, descending perineum syndrome; *Inflammatory conditions:* Crohn’s disease, ulcerative colitis, radiation proctitis; *Central nervous system disease:* dementia, stroke, brain tumors, spinal cord lesions,

multiple system atrophy (Shy Drager’s syndrome), multiple sclerosis; *Diarrhea:* Irritable Bowel Syndrome, postcholecystectomy diarrhea.

The majority of the above “causes” would appear to implicate either the external or internal anal sphincter in causation, or a disturbance of the stretch receptors or their cortical control paths. The Musculo-Elastic Theory concerns mainly the “idiopathic group”.

Like the nerve damage theory,⁷ the Musculo-Elastic Theory attributes bowel and bladder dysfunction to muscle insufficiency. Unlike the nerve damage theory,⁷ such muscle insufficiency is deemed mainly consequent upon laxity of the suspensory ligaments^(*), the effective anchoring points of the closure muscles of urethra and anorectum.

(*) and so it is potentially reversible with ligament repair.

THE COMMON CAUSATIVE RELATIONSHIP BETWEEN ANORECTAL DYSFUNCTION AND OTHER PELVIC SYMPTOMS

In a study published in 1999,⁹ simultaneous cure of urinary stress and idiopathic fecal incontinence was observed in a group of 25 patients following a midurethral sling procedure performed for cure of stress incontinence. This operation created a collagenous pubourethral neoligament; only connective tissue was repaired. Normal internal anal sphincters were found in 72% of these patients, and normal external anal sphincters in 100%.⁹ Three patients from this group subsequently reported recurrence of their fecal incontinence simultaneously with occurrence of vaginal vault prolapse and posterior zone bladder symptoms (Fig. 1). Repair of the prolapse with a posterior sling in the position of the uterosacral ligaments (USL) cured the prolapse, the urinary and the feces incontinence.⁹ Three hypotheses followed naturally from that study.

1. Both pubourethral and uterosacral ligaments were essential for anorectal closure.

2. The same muscles acting against these ligaments for bladder/urethral closure 1 were most likely also involved in anorectal closure.

3. Damaged connective tissue was most likely a major cause of both urinary and idiopathic fecal incontinence, as only connective tissue was repaired.

In the section which follows, we have tried to describe the function and dysfunction of the anorectum in a way which can be tested directly for truth or falsity.¹⁰

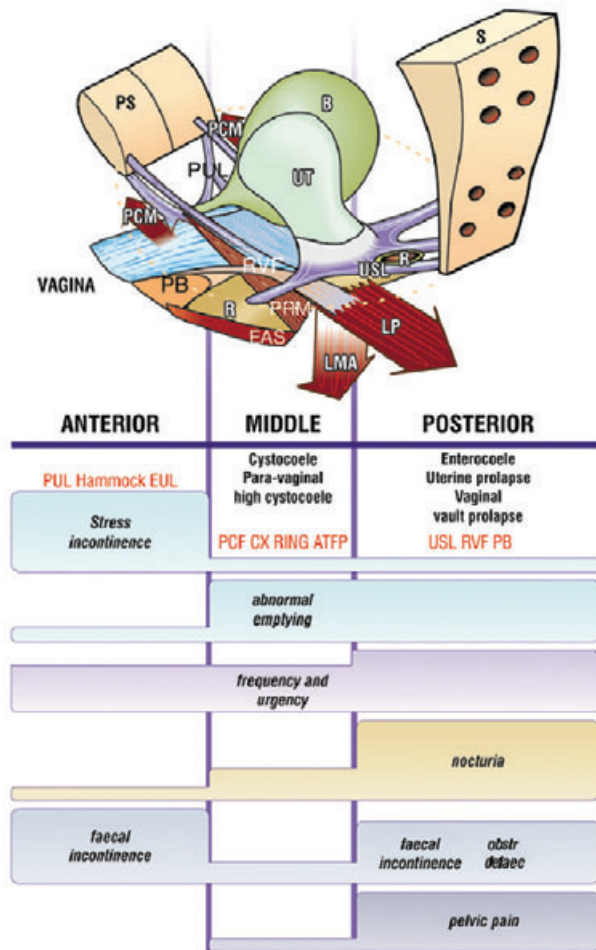


Fig. 1. – The Pictorial Diagnostic Algorithm summarizes the relationships between structural damage in the three zones and urinary and fecal symptoms. The size of the bar gives an approximate indication of the prevalence (probability) of the symptom. The same connective tissue structures in each zone (red lettering) may cause prolapse and abnormal symptoms. *Anterior zone*: External urethral meatus to bladder neck; *Middle zone*: bladder neck to cervix; *Posterior zone*: vaginal apex, posterior vaginal wall and perineal body. R = rectum; RVF = rectovaginal fascia; PB = perineal body; PRM = m. puborectalis; LP = m. levator plate; LMA = m. longitudinal muscle of the anus; PCM = m. pubococcygeus; PUL = pubourethral ligament; USL = uterosacral ligament.

THE DYNAMIC ANATOMY OF ANORECTAL FUNCTION AND DYSFUNCTION ACCORDING TO THE MUSCULO-ELASTIC THEORY

According to this theory, co-ordinated muscle forces acting against competent suspensory ligaments selectively open or close the anorectal tube. It is damage to these ligaments and their fascial attachments which cause continence and evacuation problems.

THE KEY LIGAMENTS OF THE PELVIC FLOOR (Figs. 2, 3)

The Pubourethral Ligament (PUL)

The pubourethral ligament (PUL) originates from the lower end of the posterior surface of the pubic symphysis, and descends like a fan to insert medially into the midurethra and laterally into the pubococcygeus muscle.^{11, 12} PUL is the effective anchoring point for m. pubococcygeus and levator plate.

The Arcus Tendineus Fascia Pelvis (ATFP)

The ATFP arises just superior to the pubourethral ligament (PUL), and inserts into the ischial spine. The vagina is suspended across the ATFPs. The muscle forces (arrows, Fig. 3), tension the ATFP and vagina.

The Uterosacral (USL) and Cardinal Ligaments

The uterosacral ligaments (USL) suspend the cervix and apex of the vagina. USL is the effective anchoring point for the longitudinal muscle of the anus ‘LMA’^{13, 14} and through its attachments to the rectovaginal fascia, levator plate ‘LP’ (Fig. 3). The cardinal ligaments ‘CL’, insert into the anterior portion of cervical ring, and they attach the cervix laterally to the pelvic wall.

The perineal body (PB) is approximately 4 cm long, and it occupies half the posterior vaginal wall. Its components are similar to ligaments, collagen, elastin, smooth muscle blood vessels nerves, but it also has striated muscle, being attached to all the superficial and deep perineal muscles.

THE MUSCLES OF THE PELVIC FLOOR (Figs 2,3)

There are 3 layers of muscles (Fig. 2).

Upper layer. The anterior part of pubococcygeus muscle (PCM) inserts into the lateral part of the distal vagina, and contracts forwards against PUL and the perineal body (PB).¹ The levator plate complex (LP) inserts into the posterior wall of the rectum, and it stretches the organs backwards. It acts against PUL, USL, and PB (Fig. 3).

Middle layer. The longitudinal muscle of the anus (LMA) connects levator plate, pubococcygeus and puborectalis to the external anal sphincter.^{13, 14} It creates a downward vector, which acts against USL, (Fig 3).¹ The puborectalis muscle (PRM) originates just medially to PCM. It is closely applied to the lateral walls of the rectum and inserts into its posterior wall. As well as its pivotal role in anorectal closure, the puborectalis muscle is the voluntary muscle activated during ‘squeezing’ when it elevates the whole levator plate (LP) and also, rectum, vagina and bladder (see X rays, study No 1, in this issue).

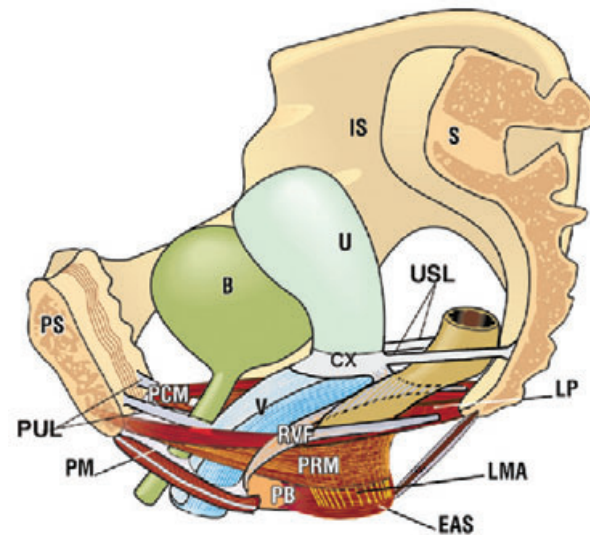


Fig. 2. – Muscles and ligaments of the pelvic floor 3D schematic sagittal view, ano-rectum closed. *Organs*: B = bladder; R = rectum; V = vagina; U = uterus; *Ligaments and fascia*: pubourethral ligament (PUL); uterosacral ligament (USL); PB = perineal body; RVF = rectovaginal fascia; Cardinal ligament (not shown) attached to anterior part of cervical ring (CX). *Muscles upper layer*: PCM = anterior portion of m. pubococcygeus; LP = levator plate; *middle layer*: LMA = longitudinal muscle of the anus; PRM = m. puborectalis; *lower (anchoring) layer*: EAS = external anal sphincter; PM = muscles of the perineal membrane.

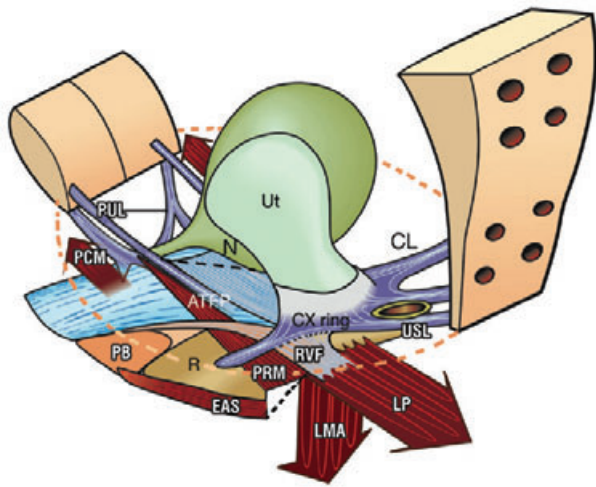


Fig. 3. – The related dynamics of anorectal and bladder closure and opening, pathogenesis and surgery. Arrows denote directional muscle forces. ATFP = arcus tendineus fascia pelvis; CL = cardinal ligament; circular broken lines = pelvic brim; *Anorectal closure*. The rectovaginal fascia (RVF) inserts into perineal body (PB), levator plate (LP) and the uterosacral ligaments (USL). Contraction of LP stiffens RVF and both walls of rectum. Contraction of LMA (longitudinal muscle of the anus) against USL stretches the rectum around puborectalis muscle (PRM), to create the anorectal angle and closure. *Defaecation*. PRM relaxes. LMA/LP vectors open out the anorectal angle (broken lines); pubococcygeus (PCM) vector stiffens PB and anterior wall of anus; rectum (R) empties. *Urethral/bladder neck closure*. The forward vector (PCM) closes urethra from behind; LP/LMA vectors rotate bladder around pubourethral ligaments (PUL) to close off bladder neck. *Micturition*. Forward vector (PCM) relaxes. Posterior vectors (LP/LMA) stretch open posterior urethral wall (broken lines). Bladder contracts. *Pathogenesis*. Damaged ligaments decrease the force of opening and closure vectors for urethra and anus. *Surgery according to this theory*. Reinforcement of damaged ligaments with implanted polypropylene tapes, Fig. 5.

Lower (anchoring) layer. The perineal body is the key anchoring point for contraction of bulbocavernosus and the external anal sphincter (EAS). The deep transverse perinei stabilizes the perineal body laterally. As well as being a sphincter in its own right, the EAS is the tensor of the perineal body and principal insertion point of the longitudinal muscle of the anus. The bulbocavernosus stretches and anchors the perineal body. Between EAS and the coccyx is the postanal plate, a tendinous structure which also contains striated muscle. It is proposed that the internal anal sphincter's role is limited to creating water and air-tight closure.

A new dynamic musculoelastic sphincter for anorectal closure (Fig. 3). The backward/downward muscle forces ('LP/LMA' arrows) stretch the rectum and rectovaginal fascia (RVF) around a contracted puborectalis muscle (PRM) to create the anorectal angle, and anorectal closure. Contraction of the forward force ('PCM' arrow) and perineal membrane muscles, tension and stabilize the perineal body (PB) and anterior wall of anus. Contraction of the external anal sphincter (EAS) creates a firm anchoring point for LMA, constricts the lower end of the anal canal, and tensions the perineal body. A similar mechanism closes urethra and bladder neck (Fig. 3).

Opening (defecation). With reference to Fig. 3, PRM relaxes. Anorectal stretch and volume receptors initiate a defecation reflex. Levator plate (LP) contraction stretches the posterior rectal wall backwards to full extension against the perineal body, and uterosacral ligament (USL). LMA (downward vector) contracts against the uterosacral ligament 'USL', to open out the tensioned posterior wall and

anorectal angle (broken lines, Fig. 3). Forward contraction by pubococcygeus 'PCM' 'splints' the perineal body and anterior anal wall to convert the anus to a semi-rigid tube. This "semi-rigidity" allows the posterior anal wall to be firmly pulled open, broken lines. This action reduces the internal resistance of the tube, facilitating the expulsion of feces during rectal contraction. A similar mechanism opens out the posterior wall of the urethra during micturition. During defecation, we hypothesize that at least initially, EAS must contract for LMA contraction to open out the anorectal angle (broken lines, Fig. 3). EAS then relaxes once the fecal bolus reaches the lower part of the anus, whereupon LP contraction would stretch the rectum up over the bolus, facilitating evacuation.

HYPOTHESIZED ROLE OF THE PUBORECTALIS IN CONTROL OF THE DEFECACTION REFLEX

Voluntary puborectalis muscle 'PRM' contraction stretches the anus and rectum like a trampoline, to support the feces bolus, relieving its pressure on the stretch receptors. This decreases the afferent stimuli to the cortex, and so prevents the activation of the defecation reflex.

PATHOGENESIS

The role of collagen in anorectal dysfunction. The pelvic muscles contract against pelvic ligaments to open or close the anal canal. The main structural element of the pelvic ligaments is collagen. Collagen may stretch or weaken with age or childbirth (circles, Fig. 4), or it may be congenitally weak.¹⁵ A muscle requires a firm insertion point to contract efficiently. As the suspensory ligaments are the effective insertion points of all three directional forces (arrows, Fig. 3), both closure (continence) and opening (defecation) may be compromised. This explains how FI and "constipation" may co-exist in the same patient. Childbirth may cause dislocation of the collagenous "glue" connecting the mucosa to the anal serosa. Mucosal prolapse or anterior wall intussusception may cause a "motor" type of fecal incontinence

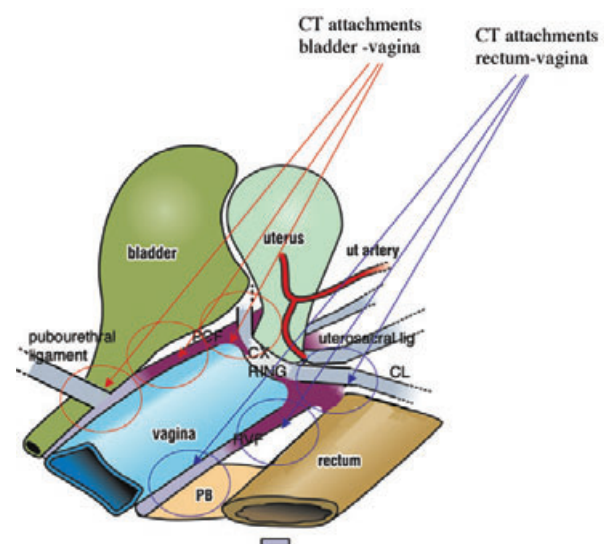


Fig. 4. – Pathogenesis-role of vaginal connective tissue in bladder and anorectal dysfunction. The circles indicate the intimate relationship between the fascia and ligaments ensheathing bladder, vagina and anorectum; also, overdilatation of ligaments and fascia by the fetal head. Red circles: attachment points of ligaments and fascia to vagina and bladder; blue circles, to vagina and rectum. The circles pictorially explain the relationship between birth, urinary and feces dysfunction. CL = cardinal ligament; PB = perineal body.

by causing a constant stimulation of nerve receptors in the anal mucosa.

The effect of age and pregnancy on connective tissue

Age-related degenerations of connective tissue superimposed on childbirth damage explain the late onset of feces incontinence (FI) in most patients. Connective tissue in the pelvis is hormonally sensitive¹⁶ and loses elasticity with age¹⁷ and childbirth. This may explain the incidence of FI during pregnancy (hormonal depolymerization of collagen), after childbirth (connective tissue damage), and in old age (connective tissue degeneration). Cure of nulliparous females by reinforcing the pubourethral ligament with a midurethral polypropylene sling⁹ further supports a connective tissue hypothesis, in this instance, genetic ligamentous laxity. A relationship between genetic connective tissue dysfunction and stress incontinence has been previously described.¹⁵

Fecal incontinence

With reference to Fig. 3, the pubourethral (PUL) and uterosacral (USL) ligaments are the effective anchoring points for backward muscle force, levator plate (LP), and USL for the downward muscle force, longitudinal muscle of the anus (LMA). Laxity in either ligament may invalidate anorectal closure by the 2 directional muscle forces, LP and LMA (arrows, Fig. 3).

Minor degrees of inadequate closure may lead to leakage of wind; greater degrees to liquid or solid feces incontinence. Clearly a severely damaged external anal sphincter muscle may also cause FI. This is a different type of FI to that proposed by this theory, and will not be cured by using implanted tapes to repair damaged suspensory ligaments, Fig. 5. In addition to weakening its direct sphincter effect, a damaged EAS would invalidate the rotation of rectum around anus required to create the anorectal angle and watertight closure.

Bowel emptying disorders

With reference to Fig. 3, laxity in the suspensory ligaments, may weaken the forces stretching open the posterior anorectal wall (downward/backward arrows, 'LP/ LMA'), so the canal may not be fully stretched open during defecation. Laxity or rupture of the rectovaginal fascia (rectocele) or perineal body may also prevent the levator plate from stretching the rectal wall into a semi-rigid structure. Inability to open out the tube may vastly increase the intraluminal resistance to feces evacuation, given that the resistance within a tube varies inversely with the 4th power of the radius, Poiseuille's law. All this may lead to bowel emptying difficulties, which may lead to straining, which may further damage the connective tissue, if not the nerve supply of the organ. The patient interprets this evacuation disorder as "constipation". The feces may bulge into the vaginal cavity. In some instances the patient may need to "manually assist" evacuation by pressure on the perineal body, or the posterior vaginal wall. In this context, the role of the perineal body (PB) is very important. Not only does the PB occupy 50% of the posterior vaginal wall, it is the main anchoring point of the rectovaginal fascia, and therefore, levator plate, (Fig. 3), both critically important for the rectal stretching which precedes evacuation.

Mucosal prolapse and intussusception

With reference to Fig. 4, there is a close interconnection between the uterosacral ligaments and rectovaginal and pre-rectal fascia. The uterosacral ligaments suspend the fascial attachments of vagina and anterior rectal wall. Laxity in the uterosacral ligaments may cause sagging of the anterior

rectal walls. Inability to empty may cause straining, and this, in turn, may cause intussusception of the anterior rectal wall. Abendstein has reported a high rate of surgical cure of anterior rectal intussusception with a posterior polypropylene sling (n = 48) plus repair of rectovaginal fascia and perineal body, validated by post-operative evacuating proctography (Part 2, study No 12).

DIAGNOSIS OF DAMAGED CONNECTIVE TISSUE STRUCTURES

Diagnosis of the site of ligamentous damage is made using the pictorial algorithm (Fig. 1). As fecal incontinence may be caused by connective tissue damage in either the anterior or posterior zone, the presence of associated urinary and other symptoms (Fig. 1), helps designate the zone of damage. The site of damage may be confirmed by vaginal examination. Even minor degrees of damage may cause FI, or other pelvic floor symptoms.

TREATMENT OF DAMAGED CONNECTIVE TISSUE STRUCTURES

Non-surgical Treatment

New pelvic floor exercises adding squatting exercises¹⁸ and more recently, sitting on a rubber "fitball" instead of a chair to strengthen the slow-twitch muscles, have demonstrated an up to 78% improvement in patients with abnormal bowel symptoms such as constipation. The anatomical principle underlying these exercises is that strengthening a muscle also strengthens its ligamentous (or tendinous) insertion points. Clearly such techniques are contraindicated in patients with significant organ prolapse.

Surgical Treatment

Based on the Diagnostic Algorithm (Fig. 1) and clinical examination, polypropylene tapes are inserted to re-inforce damaged ligaments, Fig. 5. In addition to previous data⁹ greater than 80% improvement for patients with FI has been noted by Hocking (Study 9), Petros & Richardson (Studies No10 & 11), and Abendstein (Study No 12).

CONCLUSIONS

The theory predicts that lax ligamentous insertion points may cause suboptimal muscle contraction, and therefore

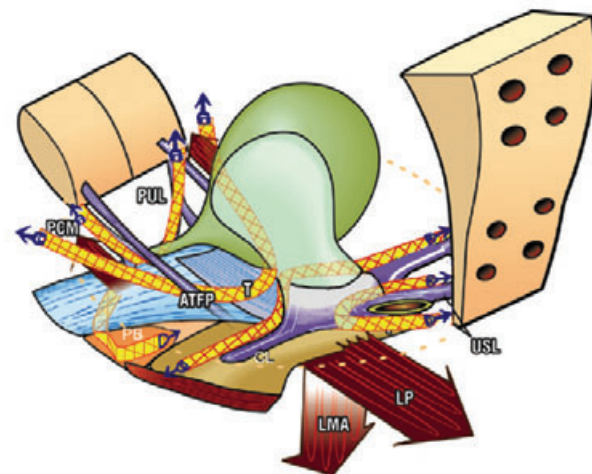


Fig. 5. – Surgical repair of damaged ligaments Polypropylene tapes "T" (in this case with attached soft tissue anchors) may be used to reinforce the main suspensory ligaments, pubourethral (PUL), uterosacral (USL) cardinal (CL) and arcus tendineus fascia pelvis (ATFP).

inability to open or close the anorectal tube. According to Popper's deductive criteria,¹⁰ an essential "next step" in the validation of this theory is the objective demonstration of the directional muscle vector forces, and their ligamentous anchoring points, during anorectal closure and opening (defecation) using X ray video or other dynamic imaging methods; then to directly test the hypothesis prospectively in patients with idiopathic fecal incontinence by surgically implanting polypropylene tapes to reinforce the anterior and posterior suspensory ligaments.

REFERENCES

1. Petros P and Ulmsten U. An Integral Theory and its Method for the Diagnosis and Management of Female Urinary Incontinence, *Scand J Urol Nephrol.*, Vol 27 Supplement No 153 - 1993; 6: 1-93.
2. Parks AG. Anorectal incontinence. *Proc Royal Soc Med* 1975; 68: 681-90.
3. Bartolo DCC, and Macdonald ADH. Fecal continence and defecation. In: *The Pelvic Floor, its functions and disorders.* Eds Pemberton J, Swash M, and Henry MM, WB Saunders, London, 2002; 77-83.
4. Freckner B, Von Euler C. Influence of pudendal block on the function of anal sphincters. *Gut* 1975; 16: 482-489.
5. Sultan AH, Kamm MA, Hudson CN, Thomas JM and Bartram CI. Anal-sphincter disruption during vaginal delivery. *N Eng J Med* 1993; 329: 1905-11.
6. Shafik A. A new concept of the anatomy of the anal sphincter mechanism and the physiology of defecation. *Colo-proctology* IV, 1982; 1: 49-54.
7. Swash M, Henry MM, Snooks SJ. Unifying concept of pelvic floor disorders and incontinence. *Journal of the Royal Society of Medicine* 1985; 78: 906-911.
8. Bharucha AE. Fecal Incontinence. *Gastroenterology* 2003; 124: 1672-1685.
9. Petros PE. Cure of urinary and fecal incontinence by pelvic ligament reconstruction suggests a connective tissue etiology for both. *International Journal of Urogynecology* 1999; 10: 356-360.
10. Popper KR. A Survey of some fundamental problems. Theories. Falsifiability. The problem of the empirical basis. Degrees of testibility. Simplicity. *The Logic of Scientific Discovery.* Unwin, Hyman, London, 1980; 27-146.
11. Zacharin RF. A suspensory mechanism of the female urethra. *Journal of Anatomy* 1963; 97: 423-427.
12. Petros PE. The pubourethral ligaments-an anatomical and histological study in the live patient. *Int J Urogynecology* 1998; 9: 154-157.
13. Courtney H. Anatomy of the pelvic diaphragm and ano-rectal musculature as related to sphincter preservation in ano-rectal surgery. *American Journal Surgery* 1950; 79: 155-173.
14. Macchi V, Porzionato A, Stecco C, Benettazzo F, Stecco A, Parenti A, Dodi G, De Caro R. Histo-topographic study of the longitudinal anal muscle. *Pelviperrineology* 2007; 26: 30-32.
15. Ulmsten U, Ekman G, Giertz G, Malmstrom A. Different biochemical composition of connective tissue in continent and stress incontinent women. *Acta Obstet & Gynecol Scand* 1987; 66: 455-457.
16. Smith P, Heimer G, Norgren A & Ulmsten U. Steroid receptors in pelvic muscles and ligaments in women. *Gynecologic & Obstet Investigations* 1990; 30: 27-30.
17. Yamada H. Aging rate for the strength of human organs and tissues. *Strength of Biological Materials*, Williams & Wilkins Co, Balt. (Ed) Evans FG. 1970; 272-280.
18. Petros PE and Skilling PM. Pelvic floor rehabilitation according to the Integral Theory of Female Urinary Incontinence. First report. *European Journal of Obstetrics & Gynecology and Reproductive Biology* 2001; 94: 264-269.

Competing interests: None.

Correspondence to:
PETER PETROS
E-mail: kvinno@highway1.com.au

Experimental Study No. 1: Directional muscle forces activate anorectal continence and defecation in the female

PETER PETROS^(*) - MICHAEL SWASH^(**)

^(*) Royal Perth Hospital, University of Western Australia

^(**) Dept of Neurology, The Royal London Hospital, London, UK

Abstract: To evaluate the hypothesis that musculoelastic forces acting around the pubourethral ligament (PUL) and uterosacral ligaments (USL) play a critical role in anorectal continence and defecation in the female. X ray video recordings, including evacuating proctograms (n = 15) were made during rest, straining and squeezing in 25 patients with urinary and fecal incontinence (FI), with radio-opaque dye in bladder, vagina, rectum and levator plate. There were 4 control patients. Surface intravaginal EMG recordings were made on separate occasions. During straining, a forward directional force (pubococcygeus) appeared to anchor the perineal body and anterior rectal wall; another forward vector (puborectalis, PRM), appeared to compress the posterior anorectal wall. Posterior vectors (levator plate and m. longitudinal muscle of the anus) stretched the rectum backwards/downwards to create the anorectal angle. During defecation, the observations were consistent with relaxation of PRM, allowing the other three directional muscle forces to actively open out the anterior and posterior walls of the anal outflow tract. All muscle forces except puborectalis appear to act against suspensory ligaments (PUL or USL) in anorectal closure and also, defecation. Compared to normal patients, the vagina and rectum were in quite vertical positions in the FI group, and were not angulated to the horizontal plane on straining. Vectors contracting against suspensory ligaments were demonstrated during anorectal closure and evacuation, consistent with the hypothesis.

Key words: Pelvic muscles; Anorectal closure; Fecal incontinence; Defecation; Connective tissue, Ligaments.

INTRODUCTION

EMG and radiological data suggest a striated muscle sphincteric mechanism¹ acting during fecal continence control. Though puborectalis and external anal sphincter muscles have been demonstrated to contract during effort,² the role of the other pelvic floor muscles has not been elucidated. The mechanism of defecation is also poorly understood. According to one description¹ feces enter the anal canal, stimulate stretch receptors and produce the urge to defecate. The internal and external anal sphincters relax, decreasing the pressure within the anus. The rectum contracts and with the assistance of raised intraabdominal pressure (Valsalva) expels the feces. No role is generally assigned for the other pelvic floor muscles. Shafik³ suggested an active muscular mechanism for anorectal opening and closure: during straining, the puborectalis, acting as the upper part of a triple loop system, contracts to close off the anal canal; during defecation, the puborectalis muscle relaxes, the levator plate contracts, and the "suspensory sling" lifts upwards to open out the anorectal canal prior to evacuation by "rectal detrusor contraction".

This observational study aimed to verify (or not), the directional muscle vectors hypothesized to act during anorectal closure, and also, defaecation. A secondary aim was to identify the hypothesized ligamentous points the vectors act against. Failure to demonstrate these vectors would seriously compromise the Theory.

PATIENTS, MATERIALS AND METHODS

A series of video X-ray studies was performed. Fecal incontinence (FI) was defined as involuntary loss of significant liquid or solid fecal material at least once per day, sufficient to present as a complaint. The diagnosis of idiopathic FI was based on clinical and endoanal ultrasound findings of a normal external anal sphincter (EAS).

X-ray studies of the organs and pelvic muscles at rest and straining

Two groups of patients were studied. The first group of 25 patients had double incontinence, urinary and fecal. Mean age was 60.5 years, range 24-76. Mean parity was 3, range

0-6. The 2nd (control) group comprised 4 patients with no history whatsoever of urinary or fecal dysfunction. Mean age was 46 years (range 29-68), parity 2 (range 1-3). As part of an IVP and cystogram investigation, they agreed to have a levator myogram. This was performed according to the protocols of Berglas and Rubin.⁴ Hard copies were taken during rest, straining, and squeezing. Ethical considerations precluded evacuating proctograms being performed on these 4 patients.

Evacuating proctograms (video)

These were performed in 15 patients with FI. Radio-opaque dye (10 ml) was also inserted into the vagina, Foley catheter balloon, and levator plate. The patients squeezed then strained prior to evacuation. During these x-ray investigations, the estimated radiation dosage did not exceed 9-10 milliSieverts.

Ethics

The levator myoproctogram investigations were carried out with informed consent, under the supervision of the Royal Perth Hospital Ethics Committee, Perth, Western Australia. The tests were ceased at n = 15, when the objectives of the trial, confirmation of the directional forces had been achieved.

EMG

On a separate occasion, simultaneous EMG recordings were taken from the distal vagina and posterior vaginal fornix in FI and control groups using a cylindrical probe during straining and squeezing. The background for this test was as follows: it is generally considered that the pelvic floor relaxes during defecation; straining at stool is a normal part of defecation, and it is said to act by increasing the intraabdominal pressure. The Musculo-Elastic Theory contradicts this view and predicts that during straining, and therefore defecation, the anterior and posterior parts of the pelvic floor contract. The x-ray studies cannot demonstrate muscle contraction. Failure to demonstrate EMG activity in the distal and proximal parts of vagina would seriously compromise the Theory.

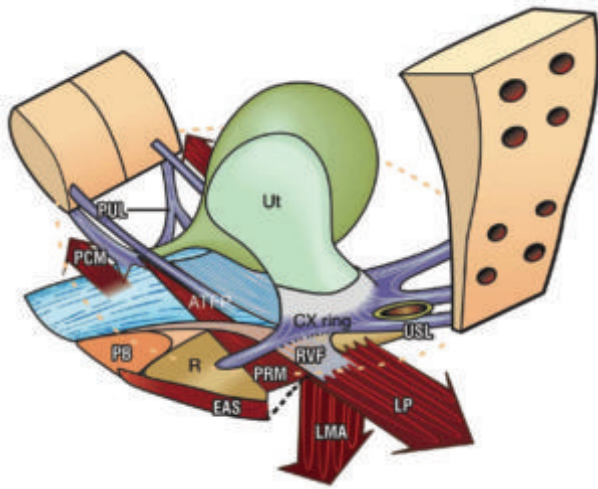


Fig. 1. – The hypothesis: directional muscle forces activate anorectal closure and defecation. 3D schematic view of pelvic structures from above and behind. Broken lines = position of anorectal angle during defecation. *Closure*: Levator plate (LP) stretches the rectum backwards against an anus laterally compressed and anchored by puborectalis (PRM). The rectovaginal fascia (RVF) is stretched backwards by LP against the perineal body (PB). The downward vector LMA (longitudinal muscle of the anus) pulls down the now extended rectum to create the anorectal angle and water-tight closure. *Defecation*: PRM relaxes. LP and LMA open out the anorectal angle. Rectum (R) contracts to evacuate. PUL = pubourethral ligament; USL = uterosacral ligament; EAS = external anal sphincter. m. pubococcygeus (PCM) tensions distal vagina, PB and the anterior anal wall during closure and defecation.

RESULTS

The video-radiological studies (Figs 2-7), confirm the 4 directional movements hypothesized to act in anorectal closure, the 3 in defecation, and the anatomical points against which they act (Fig. 1). There was no difference between the continent and incontinent groups as concerns these directional movements whatever the manoeuvre tested: straining, coughing, and “squeezing”. Qualitative differences, such as apparent laxity of various organ structures were, however, noted. The vagina and rectum appeared to be stretched more tightly during straining in the patients without urinary or fecal incontinence.

X-ray studies of the organs and pelvic muscles at rest and straining

Control group (n = 4). On comparing the resting films (Fig. 2), with the straining films (Fig. 3), four directional forces become evident (arrows). These appear to stretch the vagina and rectum between ‘X’ and ‘Y’, the exact positions of the pubourethral and uterosacral ligaments, much like a trampoline. The perineal body provides anatomical support for more than 50% of the posterior vaginal wall. The perineal body, distal parts of the vagina and midurethra appear to be pulled forwards (forward arrow). There is a distinct indentation of the anal wall, consistent with a force applied from behind, consistent with puborectalis muscle contraction (curved arrow). The rectum and upper part of the vagina are stretched backwards against “X” and downwards against “Y”, arrows (Fig. 3). In addition, the anterior part of the levator plate becomes angulated downwards. These video studies indicated a clear relationship between the downward angulation of levator plate and downward displacement of the vagina and rectum, consistent with the fascial attachments of the organs to these ligaments (Fig. 1). Like an elastic membrane, the rectum was markedly altered in shape and position during pelvic floor or pelvic organ movement. Thus

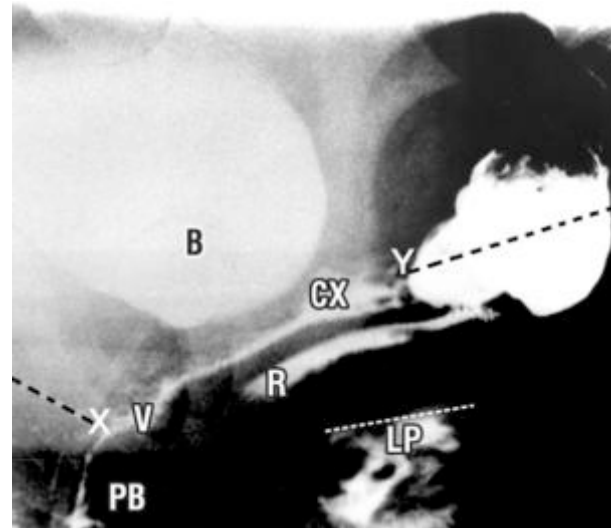


Fig. 2. – Patient continent of urine and feces. Sitting lateral X-Ray, with radio-opaque dye in bladder (B), vagina (V), rectum (R) and levator plate (LP). A white diagonal line represents the superior border of LP. PB = perineal body; R = rectum; CX = cervix; ‘X’ & ‘Y’ = insertion of the pubourethral and uterosacral ligaments (black broken lines).

it was stretched upwards and forwards during “squeezing” (“lifting up”) (as in Fig. 4), but backwards and downwards during straining. Coughing caused an identical, but much faster organ movement than that observed during straining.

During straining, fecal incontinence group (Fig. 6), the same directional muscle forces appear to be acting on the organs as in Fig. 3, anteriorly, posteriorly and inferiorly. Compared to Figs 2 and 3, the angulation of the vagina in the FI group is almost vertical at rest (Fig. 5), and on straining (Fig. 6), a stark contrast to the anorectal angulation obvious in Fig. 3. The perineal body is not nearly as prominent in Fig. 6 as in Fig. 3. Relative to Fig. 5, the posterior wall of the rectum appears to have been pulled forwards to the vertical position during straining (Fig. 6), consistent with contraction of the puborectalis muscle, accentuating the anorectal angle, but not as much as in Fig. 3. Inferiorly,

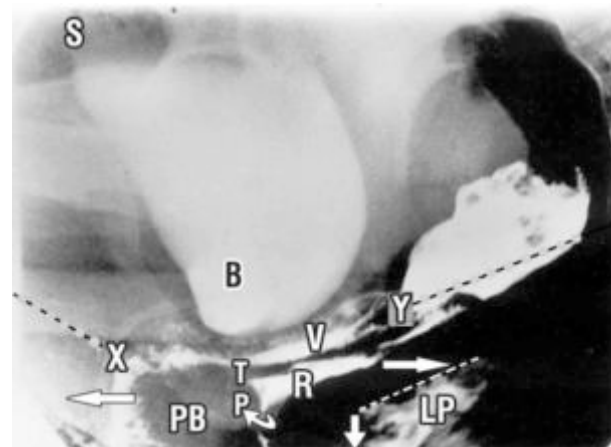


Fig. 3. – Straining, normal patient *anorectal closure* - same patient and labelling as Fig. 2. With reference to Figs. 1 & 2, arrows denote directional movement of the organs; P (curved arrow) = action of m. puborectalis; the forward and backward directional arrows pull against “X” (pubourethral ligament), and the downward arrow against “Y” (uterosacral ligament). The anterior wall of rectum appears to be anchored at “T”, the site of insertion of m. deep transversus perinei. The rectum ‘R’ is stretched backwards and rotated around an anus firmly anchored by m. puborectalis ‘P’.

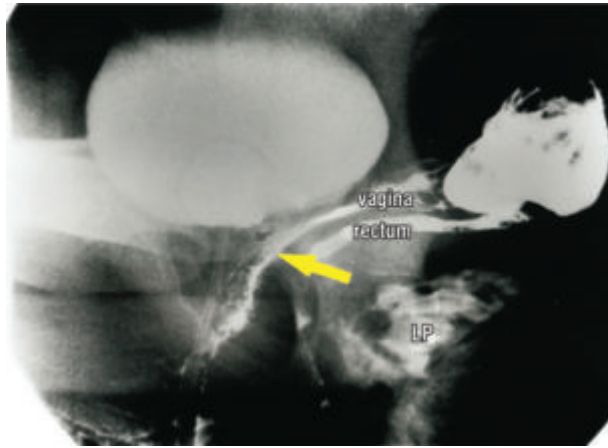


Fig. 4. – Squeezing normal patient same patient and labelling as Fig. 2. Relative to Fig. 2, there is: indentation of bladder base; marked angulation of vagina and rectum; approximation of LP to rectum; upward stretching of levator plate (LP) to the horizontal position; all these movements are consistent with upward contraction of an underlying muscle, m.puborectalis (arrow).

angulation downwards of the anterior border of levator plate (LP) is seen, (downward arrow, Fig. 6), and this is consistent with contraction of the longitudinal muscle of the anus.

During squeezing, fecal incontinence group (Fig. 7). All the organs have been pulled upwards and forwards, as in Fig. 4, apparently by contraction of the puborectalis muscle, PRM, which lies below the levator plate muscles.

During defecation, fecal incontinence group (Fig. 8). The same three directional muscle forces seen during straining, Fig. 3, seem to be acting on the walls of the anus and rectum: the distal vagina is pulled forwards; the rectum and proximal vagina have been pulled backwards; levator plate is angulated downwards; The anus has been opened out, consistent with puborectalis muscle ‘PRM’ relaxation. As in Fig. 6, ‘T’, the insertion of the deep transversus perinei, and ‘X’, the insertion of the pubourethral ligament appear to be acting as firm anchoring points for backward stretching of bladder, vagina and rectum by LP.

Surface EMG activity was noted in the distal vagina and posterior fornix during straining and squeezing.

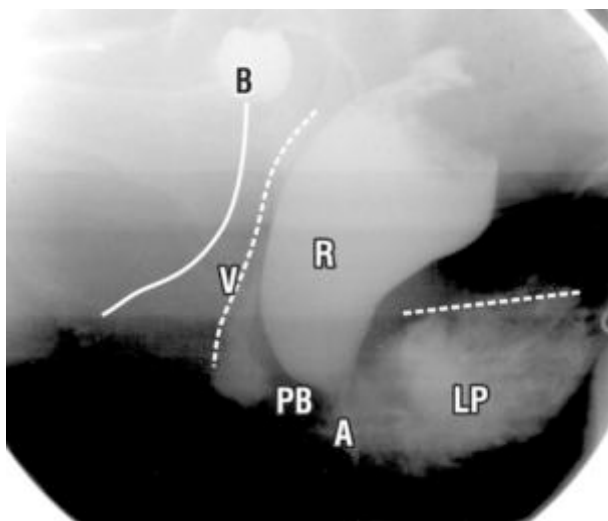


Fig. 5. – Resting position - fecal incontinence patient Sitting position. Labelling as per Fig. 2. A = anus; white broken horizontal line = superior border of LP. Vertical broken lines “V”= vagina; unbroken vertical line = urethra; B = bladder; R = rectum.

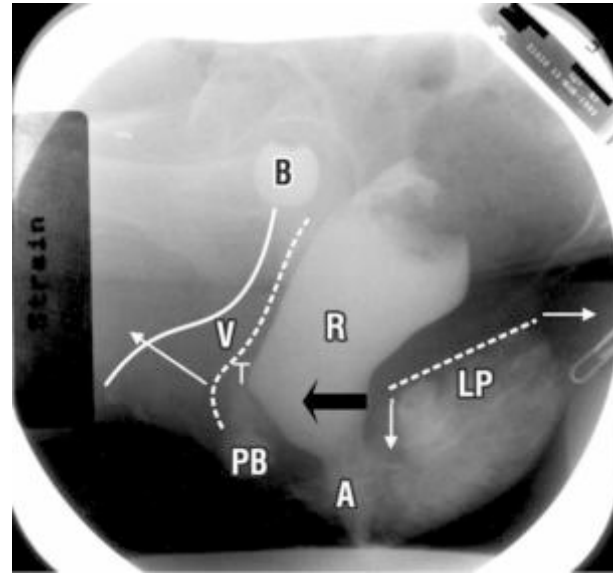


Fig. 6. – “Pre-Evacuation strain” Same patient & labelling as fig 5, sitting position. With reference to the resting state, Fig. 5, note: forward stretching of distal vagina “V”; downward angulation of anterior border of levator plate (LP); the distal part of the posterior rectal wall has become vertical, consistent with forward contraction of puborectalis (black arrow); entry of material into anus “A”, consistent with the diagnosis of fecal incontinence; “pinching” of anterior rectal wall at “T”, consistent with anchoring by m. deep transversus perinei.

DISCUSSION

It is evident on comparing the resting and straining Figs. 2 and 3 (normal) with Figs. 5 and 6 (FI group), that, even during straining, the vagina and rectum are quite vertical in the FI group, and are not stretched to the horizontal plane as in the normal group. We believe that angulation towards the horizontal plane is an essential element for anorectal angle formation, and therefore, ‘airtight’ closure. In a previous study,⁵ inability to angulate below 45 degrees on straining was attributed to lax connective tissue, as there was clear evidence of the directional muscle forces continuing to function in such patients.

The video X-ray studies are consistent with the hypothesis, four directional muscle forces acting during anorectal closure, and three during defecation (Fig. 1). During anorec-

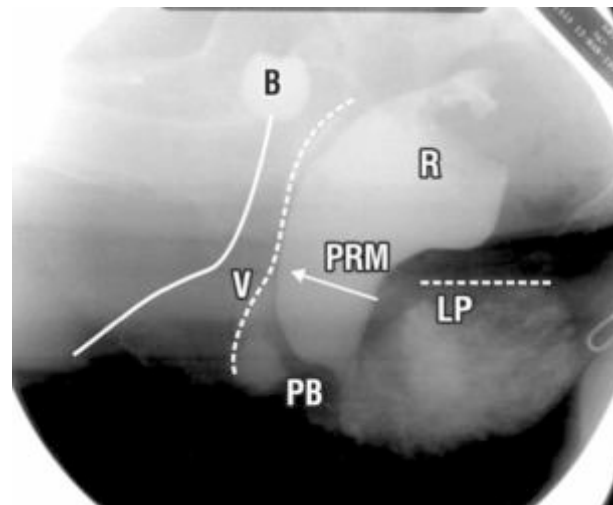


Fig. 7. – Squeeze Same patient as Fig 5, sitting position. All the organs and LP have been pulled upwards and forwards, consistent with contraction of the puborectalis muscle, PRM.

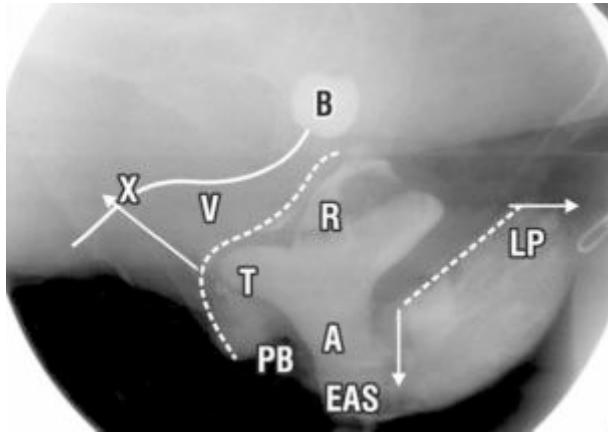


Fig. 8. – Defecation Same patient and labelling as Fig. 5, sitting position. Arrows denote directional movement of the organs consistent with stretching by muscle forces. Note: forward stretching of distal vagina “V”; backward stretching of proximal vagina, bladder (B) and rectum (R); downward angulation of levator plate (LP); marked widening of the anal canal (A); bulge at “T” consistent with anchoring by m. deep transversus perinei. EAS = position of external anal sphincter.

tal closure, and also, defecation, the pubourethral ligaments, uterosacral ligaments and perineal body, appear to be critical anchoring points for rotation and downward displacement of the stretched vagina and rectum (Fig. 1). The straining X-rays are consistent with

a) contraction of puborectalis being a prerequisite for functioning of the musculoelastic sphincter which rotates the rectum around the anus (Fig. 3).

b) The perineal body being anchored by pubococcygeus and deep transversus perinei. The defecation X-rays are consistent with relaxation of puborectalis allowing the other three muscle forces to uninhibitedly stretch and open out the anorectal canal for emptying by rectal contraction. The site of action of the vector forces is consistent with previous anatomical descriptions, pubococcygeus (forwards)⁶ levator plate (backwards)¹⁰ and longitudinal muscle of the anus (downwards).^{7,8}

Recording of EMG activity during straining and squeezing, though not specific for a particular muscle, indicates striated muscle activity consistent with activation of pubococcygeus in the distal vagina, and levator plate, longitudinal muscle of the anus, and puborectalis in the proximal vagina.

There were no differences between normal (Fig. 3) and FI patients (Fig. 6) in the direction of the vector forces during straining. However, entry of feces into the anorectum (Fig. 6) indicates obvious qualitative differences.

The X-ray studies also partly tested Shafik’s theory of normal anorectal function.³ Shafik’s prediction of puborectalis contraction during anal canal closure was validated. Shafik assigned no role for levator plate contraction during anorectal closure. Shafik stated that the rectum is lifted

upwards by the “suspensory sling” to open out the anorectal canal prior to evacuation by rectal detrusor contraction. Contrary to this view, the X-rays demonstrate a backward /downward movement of the rectum, and downward angulation of the anterior lip of levator plate, which seemed to be maintained during evacuation (Fig. 8). Shafik assigned no role for ligaments or connective tissue in his theory, either for function or dysfunction.

CONCLUSIONS

The observations confirm the participation of directional muscle forces acting against pubourethral and uterosacral ligaments during anorectal closure and also, defecation. Prospective surgical reinforcement of these ligaments will be required to test the hypothesis that ligamentous damage is a major cause of idiopathic FI. The results from such operations are described in Part 2.

REFERENCES

1. Bartolo, DCC, and Macdonald ADH. Fecal continence and defecation. In: The Pelvic Floor, Its functions and disorders. Eds Pemberton J, Swash M, and Henry MM. WB Saunders, London, 2002: 77-83.
2. Freckner B, Von Euler C. Influence of pudendal block on the function of anal sphincters. Gut 1975; 16: 482-489.
3. Shafik A. A new concept of the anatomy of the anal sphincter mechanism and the physiology of defecation. Colo-proctology 1982; 4: 49-54.
4. Berglas B, and Rubin IC. Study of the supportive structures of the uterus by levator myography. Surg Gynecol Obst 1953; 97: 677-692.
5. Petros PE. Vault prolapse 1: dynamic supports of the vagina. Int J Urogynecol and pelvic floor 2001; 12: 292-295.
6. Zacharin RF. The suspensory mechanism of the female urethra. Journal of Anatomy 1963; 97: 423-427.
7. Thompson R. The myology of the pelvic floor: a contribution to human and comparative anatomy. As quoted by Zacharin in Pelvic Floor Anatomy and Surgery of Pulsion Enterocoele, Springer-Verlag, Wien, 1985; 18-49.
8. Courtney H. Anatomy of the pelvic diaphragm and ano-rectal musculature as related to sphincter preservation in ano-rectal surgery. American Journal Surgery 1950; 79: 155-173.
9. Macchi V, Porzionato A, Stecco C, Benettazzo F, Stecco A, Parenti A, Dodi G, De Caro R. Histo-topographic study of the longitudinal anal muscle. Pelviperrineology 2007; 26: 30-32.

ACKNOWLEDGEMENTS

To the Dept of Medical Illustrations, and Dr Richard Mendelson, from the Dept of Radiology, Royal Perth Hospital.

Competing interests: None.

Correspondence to:

PETER PETROS

E-mail: kvinno@highway1.com.au

Experimental Study No. 2: A direct test for the role of the pubourethral ligament in anorectal closure

PETER PETROS^(*) - MICHAEL SWASH^(**)

^(*) Royal Perth Hospital, University of Western Australia

^(**) Dept of Neurology, The Royal London Hospital, London, UK

Abstract: Midurethral anchoring controlled solid feces loss during coughing in a patient with a history of stress fecal and urinary incontinence. This experiment demonstrated the importance of an intact pubourethral ligament when both conditions occur simultaneously.

Key words: Stress fecal incontinence; 'Simulated operation'; Pubourethral ligament; Integral theory.

INTRODUCTION

The series of video X-ray photographs (Study No. 1), appeared to support the Theory's prediction of a major role for the pubourethral ligaments in the control of fecal incontinence. A serendipitous presentation of a patient with a history of stress induced fecal incontinence at Royal Perth Hospital Outpatients Gynaecology Clinic allowed this part of the Theory to be tested directly.

METHODS AND RESULTS

A 54 year old patient, para 3, presented with a long history of leaking solid feces on coughing or straining. She discharged a bolus of feces on being asked to cough. This was replaced in her anus, and a sponge-holding forceps was gently pushed upwards onto the vaginal wall, on one side, at the level of the middle part of the urethra ('simulated operation'). Leakage of solid feces during coughing and strain-

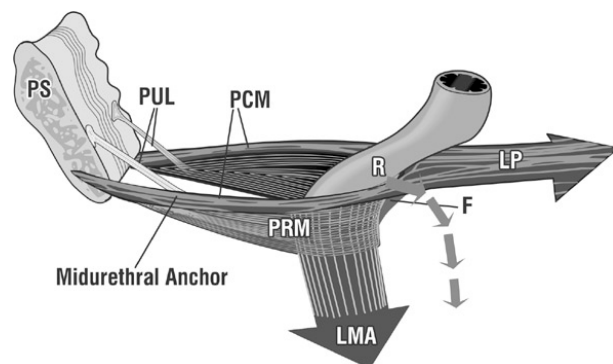


Fig. 1. – Mechanism for restoration of continence with midurethral anchoring. Puborectalis (PRM) stretches the posterior anorectal wall forwards. The pubourethral ligaments (PUL) anchor pubococcygeus muscles (PCM) which fuse posteriorly to form LP (levator plate). PUL laxity will weaken the ability of LP to contract and be tensioned. LP tensioning is a pre-requisite for backward stretching of the rectum (R), and downward rotation around PRM by the longitudinal muscle of the anus (LMA). The small arrows represent the LP/LMA rotational vectors. It is this rotation which assists anorectal closure and forms the anorectal angle. F = fascial attachment of LP to rectal wall.

ing was controlled immediately. On removing the forceps, leakage was noted again on straining. This procedure was repeated several times, and the same results reproduced on each occasion. Subsequently the patient had a midurethral sling operation, and reported total cure of this problem.

DISCUSSION

Robert Zacharin¹ described how the pubourethral ligament inserts into midurethra and the anterior portion of m.pubococcygeus, (PCM, Fig. 1). Both PCMs sweep backwards to form the levator plate (LP), Fig. 1; the levator plate 'LP' is attached to the posterior wall of rectum² by fascia which it tensions and stretches backwards. The levator plate has to be well-tensioned before the longitudinal muscle of the anus (LMA) can pull down its anterior border to effect anorectal closure around a firmly contracted puborectalis muscle (PRM) (see X-ray study, this issue). A lax pubourethral ligament (PUL), would not allow LP to contract sufficiently for LMA to rotate it around PRM for closure. A forceps applied to the site of the pubourethral ligament provides the firm anchoring point needed to restore the maximum contraction required for anorectal closure.

CONCLUSION

Only the Integral Theory's hypothesis, that the pubourethral ligament has an important role in continence control, can explain this observed sequence of events.

REFERENCES

1. Zacharin RF. A suspensory mechanism of the female urethra. *Journal of Anatomy* 1963; 97: 423-427.
2. Courtney H. Anatomy of the pelvic diaphragm and ano-rectal musculature as related to sphincter preservation in ano-rectal surgery. *American Journal Surgery* 1950; 79: 155-173.

Correspondence to:

PETER PETROS

E-mail: kvinno@highway1.com.au

Study No. 3: Reflex contraction of the levator plate increases intra-anal pressure, validating its role in continence

PETER PETROS^(*) - MICHAEL SWASH^(**)

^(*) Royal Perth Hospital, University of Western Australia

^(**) Dept of Neurology, The Royal London Hospital, London, UK

Abstract: Activation of the “vagino-levator reflex” by digital stretching of the vagina, increased intra-anal pressure less in patients with fecal incontinence than those without. This experiment demonstrates that the levator plate has a key role in the fecal continence mechanism.

Key words: Levator plate; Fecal incontinence; Intraanal pressure; Integral theory.

INTRODUCTION

The Musculo-Elastic Theory defines an important role for the levator plate in anorectal closure. The radiological study demonstrated backward movement of the organs on straining. Though this backward movement can only be explained by contraction of the posterior pelvic muscles, this movement may not necessarily be a factor in anorectal closure. The aim of this study was to more precisely define the role of the levator plate (LP) in anorectal closure by measuring the pressure in the anal canal following digital stretching of the distal vagina. The basis for this test was the “vagino-levator reflex” which was previously described by Shafik.¹ Stretching the vagina causes a reflex contraction of the levator plate muscles. As the levator plate is attached to the posterior wall of the rectum, any reflex contraction of the levator muscle should also increase the intra-anal pressure. Furthermore, if this hypothesis were valid, a smaller intra-anal pressure rise would be expected in patients with fecal incontinence, than in those without.

METHODS

Ten women with FI and 10 normal women, matched for age (mean ages 65 and 61.5 yrs), menopause and hormonal status were studied. Two fingers were placed against the anterior wall of vagina at the level of midurethra, and gently stretched upwards towards the pubic bone. Shielded Gaeltec microtransducers placed in the anal canal 3 cm distal from the external anal orifice measured the intra-anal pressure before and after stretching.

RESULTS

This action caused a mean increase in endoanal pressure of 47cm water in the control group, and a mean 30 cm water pressure increase in the FI group. These differences in the

two groups were significant (Student's t test, $p = 0.034$), suggesting less tight anal closure by the directional muscle forces in the FI group.

DISCUSSION

Reflex rise in endoanal pressure following vaginal wall stretching in both the FI and control groups confirms the role of levator plate in anorectal closure, according to the theory. The lower pressure rise in the FI group is consistent with a deficiency in anorectal closure force caused by a weakened muscle contraction. As well as stimulating the “vagino-levator reflex”, pressure at the midurethral point should have caused an equivalent rise in pressure in both groups if the pubourethral ligament was the sole determinant of the incontinence.

The data indicate that a lax pubourethral ligament cannot be the sole determinant of FI.

CONCLUSION

Levator plate action during anorectal closure was confirmed. Other structures besides a firm pubourethral ligament may have an active role in anorectal closure.

REFERENCES

1. Shafik A. Vagino-levator reflex: description of a reflex and its role in sexual performance. *European J Obstet & Gynecol and Reprod Biology* 1995; 60: 161-164.

Correspondence to:

PETER PETROS

E-mail: kvinno@highway1.com.au

Experimental Study No. 4: Abdominal pressure increase during anorectal closure is secondary to striated pelvic muscle contraction

PETER PETROS^(*) - MICHAEL SWASH^(**)

^(*) Royal Perth Hospital, University of Western Australia

^(**) Dept of Neurology, The Royal London Hospital, London, UK

Abstract: Abdominal pressure measurements during squeezing and straining simultaneous with vaginal EMG indicate that anorectal closure is not caused by raised intra-abdominal pressure, but by pelvic muscle contraction.

Key words: Anorectal closure; Raised intra-abdominal pressure; Integral theory.

INTRODUCTION

Though questions have been raised concerning the validity of valvular-type theories for anorectal closure,¹ for many physicians, such theories still have currency, possibly because of their seductive simplicity: raised intra-abdominal pressure presses the rectum down to increase the anorectal angle, and effect closure.² The aims of this study were to measure the abdominal pressures during “squeezing” (which interrupts defecation) and straining (which accelerates defecation). Simultaneous with this, surface cylindrical EMG electrodes were placed in the posterior fornix of vagina to confirm (or not) pelvic muscle contraction during the pressure rise. The Musculoelastic Theory as outlined in paper No. 1, predicts that organ movements are not caused by rise in intra-abdominal pressure. Rather it is pelvic muscle contraction which causes organ stretching and anorectal closure, the rise in intraabdominal pressure being secondary.

METHODS

The pressure and EMG studies were performed in 24 patients with no history of fecal dysfunction. Mean age was 50.5 years (range 29-71), parity 3 (range 1-7). Gaeltec micro-tip transducers were positioned in the bladder to measure the abdominal pressure during straining and also, “squeezing”. Simultaneous EMG recordings were taken from the posterior vaginal fornix using a cylindrical probe. Within this group, 20 patients had urinary incontinence, and 4 were asymptomatic. Separate radiological studies were performed during straining and squeezing on another occasion.

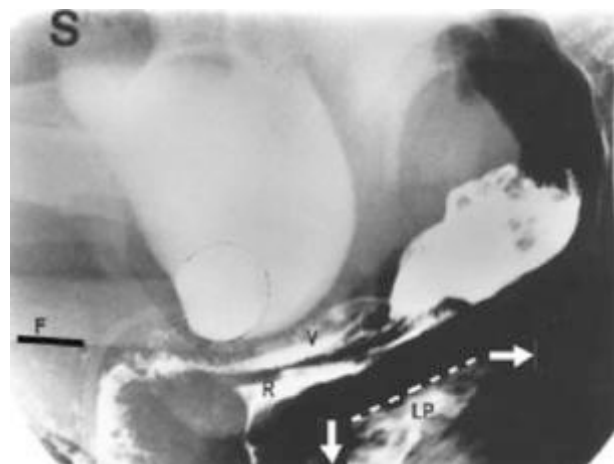


Fig. 1. – Straining X-ray, sitting position. With reference to “F”, lower border of femur, bladder, proximal vagina (V) and rectum (R) are stretched backwards and downwards during straining. Note downward angulation of levator plate (LP).

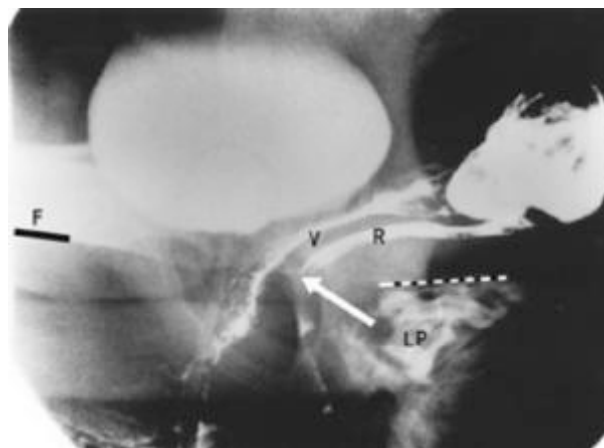


Fig. 2. – “Squeezing” X-ray, sitting position. With reference to “F”, lower border of femur, bladder, proximal vagina (V) and rectum (R) are stretched upwards and forwards. Note horizontal position of levator plate (LP).

RESULTS

Straining (Fig. 1) caused a similar rise in pressure (mean 29.75 cm water, range 0-72 cm) to that for “squeezing” (Fig. 2) (mean 24.5cm water, range 4-92 cm). EMG activity was noted in the posterior fornix of the vagina (the site of the puborectalis and levator plate muscles) both during straining and squeezing (Fig. 3).

DISCUSSION

Raised intra-abdominal pressure, a mainstay of valve-type theories for continence per se is unlikely to be a primary factor in anorectal closure. The bladder, proximal vagina and rectum are stretched backwards and downwards during straining (Fig. 1) and elevated forwards during ‘squeezing’

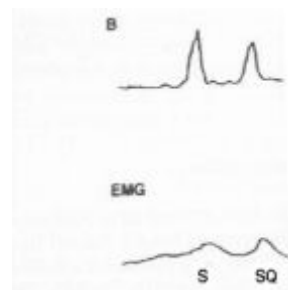


Fig. 3. – Simultaneous bladder and EMG measurements from the posterior vaginal fornix during straining (S) and squeezing (SQ). B = abdominal pressure as recorded in the bladder.

(Fig. 2) yet similar abdominal pressures were recorded. EMG activity simultaneous with pressure rise was recorded (Fig. 3), for both 'squeezing' and straining, indicating that the organ movements observed (Figs. 1, 2) were most likely activated by muscle activity. Furthermore, if raised intra-abdominal pressure were a factor in anorectal closure, straining during defecation, a common event, would immediately cause cessation of emptying, not the acceleration generally observed.

Sturmdorf (1919)³ explained the anatomical basis for our observations of raised intra-abdominal pressure during pelvic floor contraction: "the levator ani is the tensor of the pelvic fascia, the antagonist of the diaphragm and the abdominal muscles, contracting when these opposing muscles contract and relaxing when they relax".

CONCLUSIONS

The results do not support the pressure theory's statement that anorectal intra-abdominal pressure rise is a major factor in maintaining anorectal continence.

REFERENCES

1. Bartolo DCC, and Macdonald ADH. Fecal continence and defecation. In: *The Pelvic Floor, Its functions and disorders*, Eds Pemberton J, Swash M, Henry MM, WB Saunders, London, 2002; 77-83.
2. Parks AG. Anorectal incontinence. *Proc Royal Soc Med* 1975; 68: 681-90.
3. Sturmdorf A. The levator ani muscle. In: *Gynoplastic Technology*, FA Davis, Philadelphia, 1919; 109-114.

Correspondence to:

PETER PETROS

E-mail: kvinno@highway1.com.au

Experimental Study No. 5: A prospective endoanal ultrasound study suggests that internal anal sphincter damage is unlikely to be a major cause of fecal incontinence

PETER PETROS (*) - MICHAEL SWASH (**)

(*) Royal Perth Hospital, University of Western Australia

(**) Dept of Neurology, The Royal London Hospital, London, UK

Abstract: A prospective endoanal ultrasound study in 80 patients with fecal incontinence (FI) normal external anal sphincters found internal anal sphincter (IAS) thinning in only 39% of patients. This experiment indicates that IAS damage is unlikely to be a major cause of FI.

Key words: Fecal incontinence; Internal anal sphincter; Endoanal ultrasound.

INTRODUCTION

The exact role of the internal anal sphincter (IAS) in the maintenance of fecal continence (FI) is not well understood. Controversy exists as to whether a damaged IAS can cause fecal incontinence. Bartolo and Macdonald¹ report an incidence of up to 40% incontinence of feces and flatus in patients who had undergone complete internal sphincterotomy. Endoanal ultrasound studies in 127 patients after vaginal delivery, demonstrated IAS damage in 49 patients.² Sphincteric damage was associated with fecal incontinence (FI) in 10/11 of these patients, implying causation of FI. The number of patients who had IAS and EAS (external anal sphincter) damage was not specified. These data did not fit with one author's (PP) previous experience:³ of 25 patients with idiopathic FI, 72% had normal IAS and some patients had never been pregnant. Furthermore, reports of FI in 7 patients who had never been pregnant⁴ indicate that other factors besides damaged IAS may cause idiopathic FI. The aim of this study was to challenge the internal anal sphincter theory by a prospective review of IAS damage in patients with FI. The fecal incontinence described in this study was of the 'idiopathic' type.

METHODS

There was no patient selection. The mean age of the group (n = 80) was 60.6 years (range 24-88), mean parity 3 (range 0-6). All patients were assessed according to a standard protocol involving a semiquantitative patient-administered questionnaire, urinary diary, 24 hour pad testing, transperineal ultrasound and urodynamics. All the endoanal ultrasound examinations were conducted by a specialist in ultrasonic imaging (JA), using a transrectal Acuson 7 MHz linear array axial sector scanner (focal range 0.5 cm to 8 cm). As this review conforms to the standards established by the NHMRC for ethical quality review, ethics approval was not sought.

RESULTS

Fecal incontinence was defined as involuntary loss of significant liquid or solid material at least once per day. Three patients were nulliparous, and ranged in age from 24 to 88 years. Seventy-eight patients had double incontinence, urinary and fecal, and two had fecal incontinence associated with vaginal prolapse, but no urinary incontinence. Two patients reported repair of a 3rd degree tear during labour, and another had undergone sphincterotomy. At the time of assessment, however, the EAS was intact on direct and ultrasonic assessment in all patients. IAS damage was defined as

complete rupture, or thinning to less than 2 mm thickness in some part of the sphincter. Complete IAS rupture was found in one patient, and damage in a further 30 (total 39%). The rest (61%) had normal IAS. All 3 nulliparous patients had normal IAS and EAS.

DISCUSSION

Only 39% of 80 patients had evidence of any IAS damage. The others had no obvious cause for their FI. Even in Sultan's group of 49 patients with IAS defects, only 11 actually had fecal incontinence (22%), and one had no IAS or EAS damage whatsoever.² Three nulliparous females with normal IAS in our study confirms previous reports of FI in 7 nulliparous patients,⁴ such data being consistent with a congenital connective tissue defect. No alteration in IAS morphology post-operatively was observed on endoanal ultrasound in 3 patients with damaged IAS who were surgically cured of fecal incontinence.³

CONCLUSION

Though our results indicate that internal anal sphincter damage is unlikely to be a major direct cause of idiopathic incontinence, its anatomical position mandates a significant role in continence control. We believe this role is limited to creating airtight and watertight closure.

REFERENCES

1. Bartolo DCC, and Macdonald ADH. Fecal continence and defecation. In: The Pelvic Floor, its functions and disorders. Eds Pemberton J, Swash M, and Henry MM, WB Saunders, London, 2002; 77-83.
2. Sultan AH, Kamm MA, Hudson CN, Thomas JM and Bartram CI. Anal-sphincter disruption during vaginal delivery. N Eng J Med 1993; 329: 1905-11.
3. Petros PE. Cure of urinary and fecal incontinence by pelvic ligament reconstruction suggests a connective tissue etiology for both. International Journal of Urogynecology 1999; 10: 356-360
4. Parks AG, Swash M and Urich H. Sphincter Denervation in ano-rectal incontinence and rectal prolapse. Gut 1977; 18: 656-665.

Correspondence to:

PETER PETROS

E-mail: kvinno@highway1.com.au

Experimental Study No. 6: Correction of abnormal geometry and dysfunction by suspensory ligament reconstruction gives insights into mechanisms for anorectal angle formation

PETER PETROS (*) - MICHAEL SWASH (**)

(*) Royal Perth Hospital, University of Western Australia

(**) Dept of Neurology, The Royal London Hospital, London, UK

Abstract: Normalization of the anorectal angle after fecal incontinence cure by midurethral and posterior sling surgery is consistent with the hypothesis that a normal anorectal angle requires balanced pelvic muscle forces.

Key words: Fecal incontinence; Muscle balance; Obstructed defecation; Anorectal angle; Integral theory.

INTRODUCTION

It is generally believed that raised intra-abdominal pressure presses the rectum down to increase the anorectal angle.¹ Study No. 3 demonstrated that levator plate contraction was a likely factor in anorectal closure, and therefore would have some influence on the shape of the anorectum. In contrast, study No. 4 indicated that increased abdominal pressure *per se* could not be a factor in anorectal closure, and therefore would have little influence on the shape of the anorectum.

This case report appears to support the Theory's concept that the anorectal angle is a resultant of balanced muscle forces acting against competent suspensory ligaments.

CLINICAL PICTURE

The patient was 49 years old, para 3. She presented with difficulty with defecation, fecal incontinence, stress urinary incontinence, nocturia and pelvic pain. The patient had second degree vault prolapse, lax rectovaginal fascia and a very deficient perineal body. Pre-operative ultrasound (Fig. 1) showed an acute anorectal angle at rest, which was only minimally responsive to straining. Defecating proctogram demonstrated an acute anorectal angle similar to that in Fig. 1. There was no rectocele or rectal intussusception. Attempted evacuation was accompanied by straining against an uneffaced ano-rectal angle, with no passage of barium. Digital pressure applied to the perineal body under fluoroscopy appeared to support the anterior vaginal wall, and to straighten out the ano-rectal angle. This resulted in slight opening of the anorectal canal, and the passage of a small amount of rectal content.

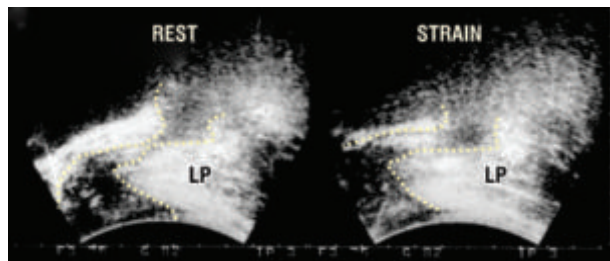


Fig. 1. – Acute anorectal angle at rest and straining. Transperineal ultrasound. Note excessive forward indentation of the posterior rectal wall at rest. On straining, there is no significant change in the ano-rectal angle; the rectum just above the ano-rectal angle appears to be opened out on straining, rather than narrowed as in Fig. 2.

SURGERY

The patient had a posterior polypropylene sling² to reconstruct the uterosacral ligaments, repair of rectovaginal fascia and perineal body for repair of her uterovaginal prolapse. She had an anterior sling to reconstruct the pubourethral ligament for cure of her stress urinary incontinence.¹

RESULTS

The patient was cured of urinary and fecal incontinence and was able to defecate normally. The post-operative transperineal ultrasound examination (Fig. 2), demonstrated a return to normal morphology.

DISCUSSION

It was radiologically demonstrated, in Study No. 2, that the anorectal closure muscles levator plate (LP), longitudinal muscles of the anus (LMA), and puborectalis muscle (PRM), stretch the rectal walls in opposite directions. It is hypothesized:

- (1) That the balance of forward and backward forces determines the shape of the rectum, and anorectal angle.
- (2) That lax pubourethral (PUL) and uterosacral (USL) ligaments will weaken the backward/downward muscle forces, distorting the anorectal angle by unbalanced forward (puborectalis) muscle contraction.

Both LP and LMA (Fig. 3), rely on firm ligamentous insertion points to contract adequately: superiorly, the uterosacral ligaments, 'USL', and inferiorly, external anal sphinc-

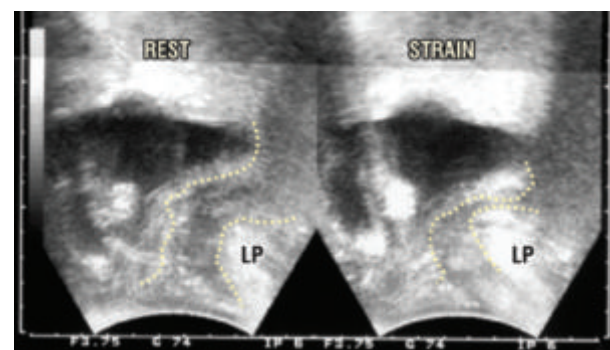


Fig. 2. – Post-operative perineal ultrasound, at rest and straining. Note restoration of normal anatomy. The anorectal angle is now essentially normal at rest. On straining, the rectum narrowed markedly just above the ano-rectal angle, with forward displacement of the anus, and creation of a more acute ano-rectal angle.

ter and perineal body, 'PB' (Fig. 3). This inability to balance the forward contraction of puborectalis muscle (PRM), may explain the acute anorectal angle "A". We explain the use of digital pressure to facilitate evacuation as follows: a

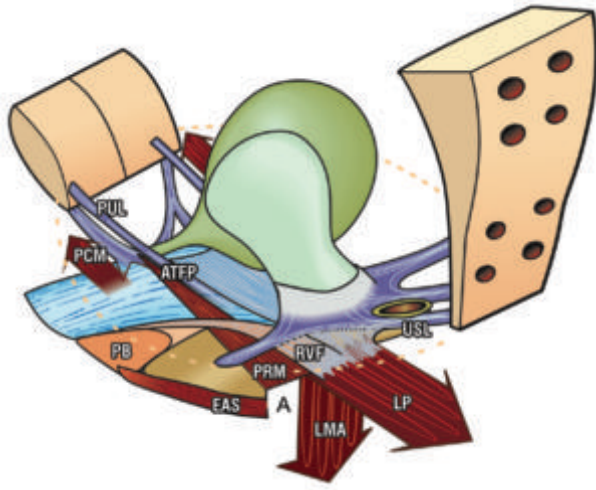


Fig. 3. – Proposed mechanism of an acute anorectal angle. The anorectal angle "A" is formed by balanced backward contraction of levator plate (LP) and longitudinal muscle of the anus (LMA), against forward contraction of m.puborectalis (PRM). PUL and USL laxity will weaken LP/LMA contraction. In relative terms, PRM contracts more strongly. The system becomes unbalanced, and PRM indents the posterior rectal wall, causing an acute anorectal angle. RVF=rectovaginal fascia; PB = perineal body.

lax perineal body will prevent the levator plate from stretching the anterior wall of rectum via a tensioned rectovaginal fascia. This mechanism is a pre-requisite for normal evacuation. Digital pressure on the posterior vaginal wall mimics a firm perineal body, allowing levator plate 'LP', Fig. 3 to stretch the rectovaginal fascia 'RVF' backwards, temporarily restoring the anorectal opening mechanism.

CONCLUSIONS

Cut away from their ligament and muscle supports, the pelvic organs have no shape or strength. Like a rope suspension bridge, the forces stretching the organs against the suspensory ligaments (Fig. 3) must be balanced. Any imbalance may change the geometry, and even function of particular organs. Restoration of normal anorectal geometry and function by surgical reinforcement of the suspensory ligaments and perineal body in this case supports this hypothesis.

REFERENCES

1. Parks AG. Anorectal incontinence. Proc Royal Soc Med 1975; 68: 681-90.
2. Petros PE. New ambulatory surgical methods using an anatomical classification of urinary dysfunction improve stress, urge, and abnormal emptying. Int J Urogynecology 1997; 8: 270-278.

Correspondence to:

PETER PETROS

E-mail: kvinno@highway1.com.au

Study No. 7: Role of puborectalis muscle in anal continence. Comments on original 4D pelvic ultrasound data from Chantarasorn & Dietz

PETER PETROS^(*) - MICHAEL SWASH^(**)

^(*) Royal Perth Hospital, University of Western Australia

^(**) Dept of Neurology, The Royal London Hospital, London, UK

Abstract: External 4D ultrasound data from Chantrasorn and Dietz demonstrating no relationship between fecal incontinence and avulsion of the puborectalis was used to challenge the Theory's prediction of puborectalis function. The results were consistent with the Theory's hypothesis that the role of puborectalis may be more to immobilize the anorectum than create primary closure per se.

Key words: 4D Ultrasound; Puborectalis avulsion; Fecal incontinence.

INTRODUCTION

We report in full, an abstract of important findings by Chantarasorn V, and Dietz HP, with kind permission of Associate Professor Dietz, University of Sydney, Nepean Clinical School. The Abstract quoted was presented at ASUM Auckland 2008 (Australasian Society for Ultrasound in Medicine).

The authors, Chantrasorn and Dietz, found no association between levator ani function and anatomy on the one hand and anal continence on the other hand, indicating that there may be no major role for the puborectalis muscle in anal continence.

Title: How important is the puborectalis muscle for anal continence? by Chantarasorn V and Dietz HP

Objective: The levator ani muscle is believed to play an important role in anal continence. However, to date there is very limited evidence to support this hypothesis. This study was designed to test for an association between puborectalis trauma and ballooning of the levator hiatus on the one hand and anal incontinence on the other hand.

Methods: The records of 401 women who had attended a tertiary urogynecological clinic were reviewed in a retrospective study. The history included questions on feces urgency, soiling, flatus and fecal incontinence. Examination included levator assessment by palpation and 4D pelvic floor ultrasound.

Results: Mean age on presentation was 54 (18-89) years. Median vaginal parity was 2 (0-9). 22% complained of fecal urgency, 16% of fecal incontinence, 16.5% of soiling, and 22.8% of flatus incontinence. 17.7% of patients were diagnosed with levator avulsion, out of which 7.1% were bilateral. Levator avulsion was not associated with fecal incontinence ($P = 0.9$), fecal urgency ($P = 0.9$), or soiling ($P = 0.5$). Flatus incontinence was the only symptom found to be associated with levator trauma; but this association was weak (χ^2 , $P = 0.01$). Hiatal dimensions at rest or on Valsalva were also found not to be associated with symptoms of anal incontinence.

DISCUSSION

The authors, Chantrasorn and Dietz, found no association between puborectalis avulsion and anal continence. These findings run contrary to orthodox thinking, that the puborectalis has a major role in anorectal closure. However, these findings are consistent with the Theory's hypothesis, that puborectalis contraction is only the first part of a more complex closure mechanism: it stabilizes the anorectum for anorectal closure by backward/downward stretching of the rectum by LP/LMA directional forces, (arrows, Fig. 1). Stretching and narrowing exponentially increase resistance in proportion to the 4th power of the radius (Poiseuille's law). Viscosity, friction, length and radius of the viscus (tube) are the major variables, but the radius of the tube is the major factor governing flow rate. It is the reduction in radius that

accounts for the increase in resistance, which prevents outflow of feces.^{1,2} For example, if the rectal tube can be narrowed to half its diameter, the internal resistance to outflow of feces increases by a factor of 16 ($2 \times 2 \times 2 \times 2$). As regards closure, the puborectalis can only compress the anorectum laterally. It cannot provide the stretching and narrowing so essential for the very high resistance required to effect airtight and watertight anorectal closure. Such an action can only be effected by the downward/backward muscle forces 'LP/LMA' (arrows, Fig. 1) stretching the rectum to create a more acute anorectal angle, Fig. 1. According to the theory, forward contraction of the anterior portion of pubococcygeus against the perineal body (Study No. 1), will still provide stabilization of the anterior anal wall permitting sufficient stretching and rotation for closure as in Fig. 1. Such an explanation is consistent with puborectalis avulsion being related to only the mildest form of FI, the flatus incontinence described in Chantrasorn and Dietz's study.

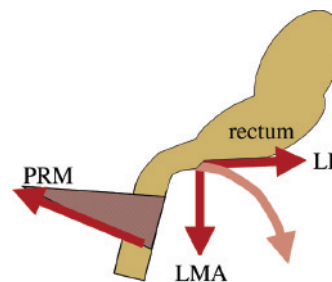


Fig. 1. – The principal closure mechanism for the anorectum is stretching and narrowing of the rectal tube by posterior muscle forces (arrows) acting against an anus immobilized by puborectalis (PRM) contraction. This action increases the resistance to leakage exponentially inversely with the 4th power of the diameter. LP = levator plate; LMA = longitudinal muscle of the anus.

CONCLUSIONS

With regard to Fig. 1, it can be concluded that puborectalis may not, per se, have a major role in anorectal continence. The findings are consistent with the theory's prediction that the role of puborectalis may be principally to anchor the anorectum for watertight closure by the rotational forces exerted by the LP/LMA vectors, which also create the anorectal angle.

REFERENCES

- Petros PE. Internal resistance may be more important for continence than anal wall tension. *Dis Colon Rectum* 2008; 51: 981-2.
- Bush MB, Petros PEP, Barrett-Lennard BR. On the flow through the human urethra. *Biomechanics* 1997; 30: 967-969.

Correspondence to:

PETER PETROS

E-mail: kvinno@highway1.com.au

Summary

The Musculo-Elastic Theory for anorectal function and dysfunction in the female

Part 2: Summary. Surgical proofs of the Theory

PETER PETROS⁽¹⁾ - MICHAEL SWASH⁽²⁾ - BYRON KAKULAS⁽¹⁾ - IAN W. HOCKING⁽³⁾
PETER RICHARDSON⁽⁴⁾ - BURGHARD ABENDSTEIN⁽⁵⁾ - CHRISTINA BRUGGER⁽⁶⁾
ANTON FURTSCHEGGER⁽⁶⁾ - MICHAEL RIEGER⁽⁷⁾

(1) Royal Perth Hospital, University of Western Australia, (2) Dept of Neurology, The Royal London Hospital, London, UK, (3) University of Adelaide, Australia
(4) Galliers Hospital, Armadale West Australia, (5) Dept of Obstetrics and Gynaecology, Hall, Austria, (6) Bezirkskrankenhaus Hall in Tirol, Austria,
(7) Innsbruck University Hospital, Austria

The Theory states: “Anorectal dysfunction in the female is mainly caused by lax suspensory ligaments inactivating anorectal muscle forces”.

In this section, the theory is directly tested by comparing pre and post-operative symptoms, and objective tests such as anorectal manometry, pudendal nerve conduction times, and defecating proctography, following surgical placement of polypropylene tapes in the position of lax suspensory ligaments. The tapes work by creating a linear deposition of collagen to reinforce the damaged ligament. According to the theory, a competent ligament is required to restore the muscle's ability to open or close the anorectum more efficiently. Failure to do so would severely compromise the theory.

Experimental study No. 8 by Petros, Swash and Kakulas. In this histological/surgical study (n = 47), evidence of muscle damage, consistent with that seen in patients with tenotomy, was found in 20/21 multiparous patients with stress urinary incontinence (SUI) and also in 4 older nulliparas. Biopsies were normal in 4 younger nulliparas and one multipara. Fibrous tissue only was found in 17 biopsies. 88% of all patients were cured of their SUI with a midurethral sling. This study indicates that muscle damage may be secondary to ligamentous laxity, and both may be improved by a midurethral sling.

Experimental study No. 9 by Hocking, directly challenges the role of a lax pubourethral ligament in the causation of ‘double incontinence’, stress urinary incontinence and fecal incontinence (FI). It is a prospective clinical study encompassing 62 patients who had ‘double incontinence’, all of whom had intact external anal sphincters. Hocking reported a 92% cure rate for this group of patients, supporting the role of the pubourethral ligaments in maintaining both urinary stress and fecal continence in the female.

Experimental study No. 10 by Petros and Richardson describes 30 patients with idiopathic fecal incontinence who also had a range of bladder and other symptoms attributed to lax uterosacral ligaments. Only 10 patients had SUI. This study also challenged the use of the Pictorial Algorithm as a diagnostic tool for patients with idiopathic FI. Post-operative assessment included anal manometry and pudendal nerve conduction time (PNCT) assessments. Twenty-five patients (83%) reported >85% improvement in their fecal incontinence and other pelvic symptoms. Low mean anal pressure, low squeeze pressure, prolonged pudendal nerve conduction times and thinned internal anal sphincters were not predictors of surgical success or failure, and these parameters did not change significantly after surgery. Only the functional anal length demonstrated a mildly significant improvement post-operatively (p = 0.049).

Experimental study No. 11 by Abendstein, Petros and Richardson, involves a different group of 81 patients with multiple anatomical defects, pubourethral ligament (n = 43), cystocele (n = 39) and uterosacral ligaments (n = 72). These defects were repaired simultaneously using a new ‘minisling’ technique, the TFS (Tissue Fixation System). In these patients the ATRP and cardinal ligaments were repaired in patients with cystocele. The cure rates for FI and bladder symptoms were similar to studies 9 & 10, indicating the important principle was not the actual surgical technique, but repair of the damaged ligaments. It was further concluded that damage to the ATRP and cardinal ligaments was unlikely to be a factor in FI causation.

Experimental study No. 12 by Abendstein et al., prospectively assessed 48 patients who had symptoms of fecal incontinence, obstructed defecation syndrome, uterovaginal prolapse and radiologically diagnosed anterior rectal wall intussusception. Only the uterosacral ligaments, and associated posterior zone structures were repaired. A high cure rate was achieved for ‘obstructed defaecation’, anorectal mucosal and fecal incontinence. Anatomic restoration was proven by post-operative defecography. It was concluded that the competent uterosacral ligaments were a key element in preventing both FI and anterior rectal wall intussusception.

Conclusions. The studies as presented lend support to many of the theory's predictions, sufficient to encourage a new integrated and holistic approach to research into the causation of FI. However, more studies involving selective ligament anchoring (“simulated operations”) during anal manometry, nerve conduction studies and, if possible, during ultrasound or fluoroscopy, may shed more light on the importance of the pelvic ligaments in pelvic floor disorder.

Key words: Integral Theory; Posterior IVS; Fecal incontinence; TFS; Obstructed defecation; Rectal intussusception.

Experimental Study No. 8: Stress urinary incontinence results from muscle weakness and ligamentous laxity in the pelvic floor

PETER PETROS^(*) - MICHAEL SWASH^(**) - BYRON KAKULAS^(*)

^(*) Royal Perth Hospital, University of Western Australia

^(**) Dept of Neurology, The Royal London Hospital, London, UK

Abstract: **AIM.** To assess the roles of muscle damage and of ligamentous laxity in urinary stress incontinence. **PATIENTS AND METHODS.** Muscle biopsies (n = 47) were taken from the anterior portion of pubococcygeus muscle during the "tension-free" midurethral slingplasty procedure, an operation which corrects laxity in the pubourethral ligament. There were 38 multiparas with stress incontinence, and 9 nulliparas with mainly urge and frequency. The biopsies were examined blindly for evidence of muscle damage. Surgical cure was blindly assessed by means of a cough stress pad test. **RESULTS.** The results were correlated only after post-operative assessment. In total, 33 of the 39 patients with stress urinary incontinence were cured. In 17 biopsies of multiparas and in one nullipara the sample consisted only of a fibrous connective tissue scar. Fifteen of these 17 multiparas with stress urinary incontinence were cured postoperatively. Of the 21 biopsies of multiparas containing muscle tissue, 20 showed muscle damage; 18 of these patients were surgically cured; the mean urine loss on cough stress test reduced from 11.3 gm to 0.7 gm. Of the 8 nulliparous patients in this group with muscle tissue in the biopsy, only the biopsies of the four oldest patients showed muscle damage; none lost urine on pre or postoperative pad testing. **CONCLUSIONS.** Muscle and connective tissue damage are linked abnormalities that together lead to pelvic floor dysfunction and incontinence. Correction of ligamentous laxity can cure incontinence, even when there is muscle weakness.

Key words: Incontinence; Muscle damage; Midurethral sling; Tenotomy; Connective tissue; Nullipara.

INTRODUCTION

The cause of "idiopathic" urinary and fecal incontinence is controversial. Based on histological and electrophysiological studies, Swash and colleagues suggested that muscle damage secondary to birth-induced pelvic and perineal nerve damage may cause sphincter and pelvic floor weakness, and so lead to fecal and urinary incontinence.¹⁻³ Smith et al.^{4,5} confirmed these findings, but it was also noted that many patients with genital prolapse, without impaired fecal or urinary continence, also had electrophysiological evidence of damage to the innervation of pelvic floor sphincter muscles.⁴ Sometimes this nerve damage was combined with direct trauma to these muscles.⁶⁻⁸ Nerve damage was also correlated with increased perineal descent,¹³ itself a feature of pelvic floor laxity. More recently, histochemical studies of the superior border of the anterior portion of the pubococcygeus muscle (PCM) indicated no evidence of necessary direct or neurogenic damage to this muscle in patients with stress urinary incontinence.¹⁰ Beginning in 1990, it was reported that creating an artificial pubourethral neoligament^{11,12} achieved a high rate of cure not only in patients with urinary incontinence, but also in fecal incontinence.⁹ Since only connective tissue was repaired by that procedure,⁹ it was concluded that connective tissue damage may have been the major etiological factor. The aim of this prospective study was to consider the relation between muscle damage, whether due to direct injury, or to neurogenic factors, and connective tissue laxity in the pathogenesis of stress urinary incontinence.

PATIENTS AND METHODS

Forty-seven patients, 38 multiparas and 9 nulliparas were studied. Their mean age was 46.8 years (range 18 to 78), and mean parity 1.7 (range 0 to 5). All the patients were assessed pre-operatively and post-operatively at 8 weeks, symptomatically, using a structured questionnaire, and objectively, using a cough stress pad test, (10 coughs in the upright position with a full bladder).

All 47 patients had muscle biopsies taken from the inner inferior surface of the anterior portion of pubococcygeus muscle during the "tension-free" midurethral slingplasty.^{15,16}

This operation creates an artificial pubourethral neoligament, tightening the suburethral vagina by attaching it to underlying ligamentous and muscular structures. As part of this procedure^{12,15} bilateral paraurethral incisions were made in the lateral sulcus of the vagina, for access. The midurethral and muscle reflections of the pubourethral ligaments (PUL) were identified. The lateral reflection of PUL was retracted medially, to reveal the undersurface of the anterior portion of the pubococcygeus muscle (PCM). The muscle biopsies were all taken between the hammock and pubic symphysis insertion points of the PCM by the same surgeon (PP), a distance of approximately 2 cm. The biopsy specimen approximately 0.5 cm x 0.3 cm x 0.2 cm was taken, where possible, from both sides of PCM, and placed in liquid nitrogen.

Histological preparations of these muscle biopsies were examined blindly by MS and BK for evidence of muscle damage. Multiple histological and enzyme histochemical techniques prepared from frozen sections, were used. Standard histological methods included haematoxylin and eosin, ATPase and Gomori stains, and PAS with and without diastase digestion. Enzyme histological methods were used for fibre type distribution studies, including NADH, succinate dehydrogenase, myophosphorylase, phosphofructinase, adenylate deaminase, non-specific esterase, acid and alkaline phosphatase, and cytochrome oxidase.

RESULTS

The 38 multiparas all gave a history of stress incontinence, and this was confirmed by pad testing; mean preoperative loss was 11.3 gm; mean postoperative loss (including failed surgery), was 0.7 gm. Of these 38 multiparas 33 were cured of their stress urinary incontinence following slingplasty. The nulliparous group comprised nine patients with mild symptomatic stress, urgency and frequency, but no stress incontinence demonstrated on cough stress testing. After surgery all nine nulliparas were cured of their stress symptoms, and seven of their urgency and frequency. The clinical results were correlated with the biopsy findings only after the post-operative assessment was available.

Biopsies from 17 patients, 16 multiparas, and one nullipara, revealed connective tissue only, without remaining

muscle fibres. Of the 29 additional biopsies, 21 were from multiparas. Twenty of these biopsies were abnormal, and 18 of these patients were surgically cured. The changes in these 20 abnormal muscle biopsies consisted of partial fibrous tissue replacement of muscle fibres, with increased variation in muscle fibre diameter in the remaining muscle fibres. There were also secondary changes consistent with ongoing muscle damage, such as increased central nucleation, and occasional central cores. A few fibres showed minor subsarcolemmal accumulations of mitochondria. Occasional regenerating fibres were seen. Mild grouped reinnervation of fibre types, involving both Type 1 and Type 2 fibres was seen in some biopsies, but this was not prominent and was difficult to assess because of the marked Type 1 predominance found in all the biopsies of this muscle; a normal feature of pelvic floor muscles.¹⁷ In one biopsy a muscle spindle was found. Four older nulliparous patients, aged 30, 36, 40 and 50 years, had evidence of muscle damage; but the four youngest patients, aged 18 to 28 years, did not. The youngest nullipara had normal histology, but one of these four patients had focal collections of adipose tissue within the endomyrial connective tissue. In half the biopsies, thickened, sometimes dense, collagenous tissue was found covering the under surface of the PCM muscle.

DISCUSSION

Our results demonstrate severe damage to the biopsied PCM muscle, yet the patients were cured by a midurethral sling, a procedure which reinforces the pubourethral ligament. This observation implies a role both of muscle weakness and of ligamentous laxity in the pathogenesis of the functional pelvic floor disorder leading to stress urinary incontinence. Improving ligamentous integrity will enable muscle function to be at least partially restored, even when muscles themselves are damaged and weakened.

The changes present in the muscle biopsies ranged from complete absence of muscle fibres, with replacement by fibrous scar tissue, to less marked changes, consisting of increased variation in muscle fibre size, increased central nucleation and increased connective tissue. Classical myopathic changes were infrequent, and frank neurogenic change was difficult to assess because of Type 2 fibre predominance. In many instances, the changes resembled those described following experimental tenotomy.^{18, 19} Dimpfl et al.²⁰ found increased central nucleation and fibrosis in multiparous women that were more marked on the inferior surface of the muscle, and an increasing frequency of similar changes in nulliparous patients with age. Evidence of neurogenic damage was not found in this muscle. They concluded that ageing and vaginal childbirth lead to histomorphological changes of the pelvic floor muscle that are consistent with changes of myogenic origin. Our data support Dimpfl et al's findings and those of Heit.¹¹ We noted normal findings in one multipara, and in four younger nulliparas, and muscle damage in the four older nulliparas. Heit et al.¹¹ took muscle biopsy specimens from the superior surface of the middle part of the PCM in 13 patients. The decision as to whether or not muscle damage was present was made by comparison of the symptomatic and asymptomatic patients, a method that may have underestimated muscle damage, since it would not take account of pathological changes in the asymptomatic patients. In contrast, our results are based on comparison with normal muscles evaluated in our previously published work.¹⁷

In limb muscles, biopsies taken near the insertion points of normal striated muscles may exhibit central nucleation and fibre splitting, but this was not an issue in our study since we took biopsies from the body of the pubococcy-

geus muscle (PCM). The changes we have found were in the anterior portion of the pubococcygeus muscle, which is innervated by direct branches from the pelvic plexus, rather than from branches of the pudendal nerves. Damage to the latter nerves has been implicated in voluntary sphincter and puborectalis denervation in this functional disorder. The cause of the morphological changes in the PCM muscle in our patients is inevitably a matter of some uncertainty but, at least in part, these changes may result from unloading of the muscle by stretch injury to pelvic floor ligaments, preventing normal force generation in the muscle. The experimental paradigm of muscle unloading is tenotomy, but similar unloading occurs in animals subject to zero gravity, as in space flight. Ohira et al.²¹ have described atrophy of both Type 1 and Type 2 fibres after unloading, including after tenotomy. The changes we have noted in PCM, including a few core structures, are similar to those reported after human tenotomy.^{18, 19} However, the absence of muscle fibres, with fibrous tissue scarring in so many of our biopsies, indicates primary muscle damage, with or without denervation, rather than any secondary effect of muscle unloading.

These findings show that muscle unloading from ligamentous laxity together with muscle damage, whether due to direct injury or to neurogenic damage, are important and related factors in the aetiology of stress urinary incontinence. The striking results of tension-free urethral sling-plasty show that sufficient muscle contractile force can be restored by enhancing ligamentous support, and that there is therefore sufficient functional muscle reserve in these patients. This functional reserve is not utilisable when the ligamentous attachments of the pelvic floor muscles are lax. This finding is consistent with the failure of MRI studies of the pelvic floor to detect abnormal muscle morphometry in patients with urinary incontinence when compared to non-incontinent controls, the major finding being loss of the hammock-like configuration of the vagina.²²

Using 3D and 4D ultrasound in 781 patients, Dietz et al.²³ demonstrated that even with bilateral avulsion of the pubo-visceral muscle (pubococcygeus/puborectalis), there was no greater incidence of urinary or fecal incontinence. Women with levator avulsion defects were, however, twice as likely to show pelvic organ prolapse of stage II or more, compared to those without levator ani injury, mainly due to an increased risk of cystocele and uterine prolapse.

The previously reported finding of delayed pudendal nerve terminal latency in patients with uterovaginal prolapse, without stress incontinence⁶ indicates damage to this nerve innervating the external sphincter and puborectalis muscles, but of insufficient degree to lead to major functional disturbance, that is incontinence. Thus, there are many factors leading to incontinence, including neurogenic muscle damage, ligamentous stretch causing muscle unloading and functional weakness, secondary muscle damage to unloaded muscles, and primary damage to pelvic floor muscles and sphincters during vaginal delivery.

Surgical cure following a midurethral sling procedure in 20/21 patients who had muscle damage and stress incontinence reinforces this conclusion. The midurethral sling-plasty procedure restores the functional deficit caused by connective tissue damage to the pubourethral ligament, a critical component of the urethral and bladder neck closure mechanisms.²⁴ We propose that connective tissue laxity prevents the normal action of the pubococcygeus muscle in urethral closure, as a muscle needs firm insertion points to contract efficiently, and should not be stretched and have lost elasticity. With time, this laxity may also cause changes similar to those seen after tenotomy in limb muscles.^{12, 13, 21}

These arguments suggest the question "What is the effect of damaged muscle on the urethral closure mechanism?". Clearly a damaged muscle must subtract from the efficiency of a musculoelastic mechanism. However, the force required to close the urethra is only a fraction of the force required to support between 10 and 20 Kg of abdominal viscera. This would appear to give the pelvic muscles considerable reserves of strength, a concept reinforced by MRI findings of no gross morphological changes between GSI and control patients.²²

Our finding of muscle damage in the four older nulliparas, but not in the younger nulliparous group, can be attributed to age-related connective tissue laxity in the older group, a well-known phenomenon.²⁵ Symptomatic urinary urge and frequency, usually thought of as neurological in origin, can be initiated following far less connective tissue damage than stress incontinence, which is mechanical in origin.²⁴

CONCLUSION

The abnormalities we have described are consistent with our hypothesis that muscle and connective tissue damage are linked, ligamentous laxity increasing muscle insufficiency, and causing secondary muscle damage in muscles that are often already damaged by childbirth injury due to unloading muscle in a similar way to that which occurs in limb muscles after tenotomy. Furthermore, given the close relationship between urinary incontinence and idiopathic fecal incontinence, we believe our findings most likely apply also to patients with idiopathic fecal incontinence.

REFERENCE

1. Snooks SJ, Swash M. Abnormalities in the innervation of the urethral striated sphincter musculature in incontinence. *Br J Urol* 1984; 56: 401-405.
2. Snooks S J, Badenoch D, Tiptaft R and Swash M. Perineal nerve damage in genuine stress urinary incontinence: an electrophysiological study. *Br J Urol* 1985; 57: 422-426.
3. Snooks SJ, Barnes RPH, Swash M. Damage to the voluntary anal and urinary sphincter musculature in incontinence. *J Neurol Neurosurg Psychiatry* 1984; 47: 1269-1273.
4. Swash M, Henry MM, Snooks SJ. A unifying concept of pelvic floor disorders and incontinence. *J Royal Soc Med* 1985; 78: 906-8.
5. Smith ARB, Hosker G, Warrell DW. The role of partial denervation of the pelvic floor in the aetiology of genito-urinary prolapse and stress incontinence of urine: a neurophysiological study. *Br J Obstet Gynaecol* 1989; 96: 24-28.
6. Smith A, Hosker G, Warrell D. The role of pudendal nerve damage in the aetiology of genuine stress incontinence in women. *Br J Obstet Gynaecol*. 1989; 96: 29-32.
7. Snooks SJ, Henry MM and Swash M. Faecal incontinence due to external anal sphincter division in childbirth is associated with damage to the innervation of the pelvic floor musculature: a double pathology. *Br J Obstet Gynaecol* 1985; 92: 824-828.
8. Snooks SJ, Swash M, Henry MM, Setchell M. Risk factors in childbirth causing damage to the pelvic floor innervation. *Br J Surg* 1985 72 (Suppl): S15-S17.
9. Sultan AH, Kamm MA, Bartram CI, Hudson CN. Anal sphincter trauma during instrumental delivery. *Internat J Gynecol Obstet* 1993; 329:1905-1911

10. Henry M, Parks AG, Swash M. The pelvic floor musculature in the descending perineum syndrome. *Br J Surg* 1982; 69: 470-472.
11. Heit M, Benson T, Russell B, and Brubaker L. Levator ani muscle in women with genitourinary prolapse: indirect assessment by muscle histopathology, *NeuroUrol Urodynamics* 1996; 15: 17-29.
12. Petros PE, Ulmsten U, Papadimitriou J. The autogenic neo-ligament procedure: a technique for planned formation of an artificial neo-ligament. *Acta Obstet Gynaecol Scand* 1990; 69 (Suppl 153): 43-51.
13. Petros PE, Ulmsten U. The combined intravaginal sling and tuck operation; an ambulatory procedure for stress and urge incontinence. *Acta Obstet Gynaecol Scand*. 1990; 69 (Suppl. 153): 53-59.
14. Petros PE. Cure of urinary and faecal incontinence by pelvic ligament reconstruction suggests a connective tissue etiology for both. *Internat J Urogynecol* 1999; 10: 356-360.
15. Petros PE. The intravaginal slingplasty operation; a minimally invasive technique for cure of urinary incontinence in the female. *Austral NZ J Obstet Gynaecol* 1996; 36: 1-9.
16. Ulmsten U, Henricksson L, Johnson P and Varhos G. An ambulatory surgical procedure under local anesthesia for treatment of urinary incontinence. *Internat Urogynecol J* 1996; 7: 81-86.
17. Beersieck F, Parks AG, Swash M. Pathogenesis of idiopathic ano-rectal incontinence; a histometric study of the anal sphincter musculature. *J Neurol Sci* 1979; 42: 111-127.
18. Jamali AA, Afshar P, Abrams RA, Lieber RL. Skeletal response to tenotomy. *Muscle Nerve* 2000; 23: 851-862.
19. Bruce-Gregorios J, Chou SM. Core myofibres and related alterations induced in rat soleus by immobilization in shortened position. *J Neurol Sci* 1984; 63: 267-275.
20. Dimpfl Th, Jaeger Ch, Mueller-Felber, Anthuber C, Hirsch A, Brandmeier R, Schuessler B. Myogenic changes of the levator ani muscle in premenopausal women: the impact of vaginal delivery. *NeuroUrol Urodynamics* 1998; 17: 197-205.
21. Ohira Y, Yoshinaga T, Ohara M, Kawano F, Wang XD, Higo Y et al. Gravitational unloading effects on muscle fiber size, phenotype and myonuclear number. *Cells Tissues Organs* 2006; 182: 129-142
22. Tunn R, Paris S, Fischer W, Hamm B and Kuchinke J. Static magnetic resonance imaging of pelvic floor muscle morphology in women with stress urinary incontinence and pelvic prolapse. *Neuro Urol Urodynamics* 1998; 17: 579-589.
23. Dietz H, Simpson J. Levator trauma is associated with pelvic organ prolapse. *Br J Obstet Gynaecol* 2008; DOI: 10.1111/j.1471-0528.2008.01751.x.
24. Petros PE, Von Kinsky B. Anchoring the midurethra restores bladder neck anatomy and continence. *Lancet* 1999; 354: 997-998.
25. Yamada H. Aging rate for the strength of human organs and tissues. *Strength of biological materials*. In: Evans FG (Ed) Baltimore, Williams & Wilkins 1970; 272-280.

ACKNOWLEDGEMENTS

We thank Drs D. Dasig, V. Fabian and P Panegyris for their assistance with the histology examinations.

Correspondence to:

PETER PETROS
E-mail: kvinno@highway1.com.au

Experimental Study No. 9: Double incontinence, urinary and fecal, cured by surgical reinforcement of the pubourethral ligaments

IAN W. HOCKING

University of Adelaide, Australia

Abstract: AIM. To test a previous observation that patients with double incontinence, stress urinary incontinence and fecal incontinence, may both be cured with a midurethral sling. METHODS. A prospective study. Between September 1999 and February 2007, using the IVS tunneller (Tyco Norwalk CT), the author performed 647 midurethral sling operations in patients with genuine stress incontinence (GSI) (n = 343), mixed stress and urge incontinence (n = 242), and double incontinence, stress and fecal (n = 62). Mean age of the patients was 63 years (range 36-86), and mean parity 3 (range 1-6). Transperineal scanning (n = 575) and urodynamics (n = 509) were performed in the majority of patients. Inclusion criteria: all patients with GSI, mixed and double incontinence. Exclusion criterion: external anal sphincter damage. RESULTS. Post-operative assessment was at 6 weeks, 6 months, then 12 months. GSI (n = 343); Mixed Incontinence (n = 242); fecal incontinence (n = 62). Overall cure rate for stress incontinence was 91%, for the urge component of mixed incontinence 74%, and for the fecal component of double incontinence 92%. Complications included bladder perforation 0.1%, voiding difficulty 4%, haematoma 1.7%, neourgency 3.4%, and tape erosion 1.5%. CONCLUSION. A competent pubourethral ligament appears to be an important component of the fecal continence mechanism, at least as concerns patients with double incontinence, who have no obvious external anal sphincter damage.

Key words: Fecal Incontinence; Stress Incontinence; Pubourethral ligament; Midurethral sling; Integral Theory.

INTRODUCTION

I commenced the "tension-free" midurethral sling operation in 1999, using the Tyco IVS instrument. The background to this study was a previous observation of cure whereby patients with double incontinence, stress and fecal, may both be cured with a midurethral sling.¹ Though the main thrust of my work concerned patients with genuine stress incontinence (GSI) or mixed stress and urge incontinence, I kept specific records of any fecal incontinence (FI) symptoms also.

METHODS

Inclusion criteria were a history of solid or liquid fecal incontinence which during episodes, occurred at least several times a week. The only exclusion criterion was a torn or incompetent external anal sphincter, as diagnosed by rectal examination.

At the 1st visit, all patients had a structured assessment including a self-administered structured questionnaire, vaginal examination, incontinence diary, transperineal ultrasound (n = 575), urodynamics (n = 509), and cough stress pad test which comprised 10 coughs and 10 star jumps, administered with a full bladder. No specific tests were performed for fecal incontinence.

An IVS polypropylene tape was inserted via a retropubic approach in the position of the pubourethral ligaments (PUL) (Fig. 1) using the IVS tunneller (Tyco, Norwalk CT, USA) and the prescribed technique¹ ensuring the tape was closely apposed to the urethra, and tightening the suburethral vaginal hammock.

RESULTS

Mean age of the patients was 63 years (range 36-86), and mean parity 3 (range 1-6). Post-operative assessment was at 6 weeks,

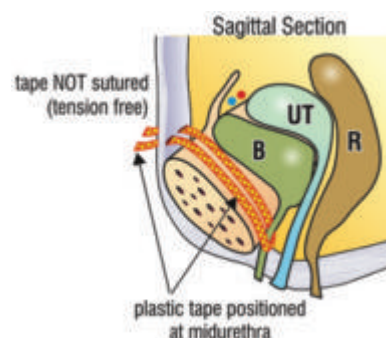


Fig. 1. – 'Tension-free' midurethral tape. A polypropylene tape is positioned exactly at midurethra. This creates a collagenous reaction which re-inforces a lax pubourethral ligament.

TABLE 1. – Results and complications.

IVS Midurethral Sling (n-647)	IVS Midurethral Sling Complications
GSI (n = 343)	Bladder perforation (0.1%)
Cured (91%)	Post-op voiding difficulty (4%)
Cured or improved (95%)	Haematoma (1.7%)
Mixed Incontinence (n = 242)	Neourgency (3.4%)
Urge Cured 74%	Tape erosion/rejection (1.5%)
Urge Cured or improved (81%)	Post-op UTI (6.6%)
Fecal Incontinence (n = 62)	Nerve, bowel injuries (0%)
Improved (92%)	Wound infection (0%)
Patient satisfaction (all operations) (92%)	

6 months, then 12 months. The results on operations performed between Sept 1999 to Feb 2007 are summarized in Table 1: GSI (n = 343); Mixed Incontinence (n = 242); fecal incontinence (n = 62). Overall cure rate for stress incontinence was 91%, for the urge component of mixed incontinence 74%, and for the fecal component of double incontinence 92%. Complications included bladder perforation 0.1%, voiding difficulty 4%, haematoma 1.7%, neourgency 3.4%, and tape erosion 1.5%.

DISCUSSION

This was a clinical observational study comprising 62 patients. The cure rate, > 90%, for both SI and fecal incontinence was similar to that reported previously.¹ It is well established that a competent pubourethral ligament is important for the control of urinary stress incontinence.² This study confirms that a competent pubourethral ligament also appears to be an important component of the fecal continence mechanism, at least as concerns patients with double incontinence, stress and fecal, who have no obvious external anal sphincter damage.

REFERENCE

- Petros PE. Cure of urinary and fecal incontinence by pelvic ligament reconstruction suggests a connective tissue aetiology for both. International Journal of Urogynecology 1999; 10: 356-360.
- Petros PE, Ulmsten U. An Integral Theory of female urinary incontinence. Acta Obstet Gynecol Scand 1990; (Suppl.) 153: 1-79.

Correspondence to:

E-mail: ianhock@bigpond.net.au

Study No. 10: Fecal incontinence cure by surgical reinforcement of the pelvic ligaments suggests a connective tissue aetiology

PETER PETROS^(*) - PETER RICHARDSON^(**)

^(*) Royal Perth Hospital, University of Western Australia

^(**) Galliers Hospital, Armadale WA

Abstract: AIM. To test the hypothesis that the pubourethral and uterosacral suspensory ligaments are an important cause of idiopathic fecal incontinence. METHODS. Thirty patients with urinary and fecal incontinence were tested with pre-operative endoanal ultrasound, pre- and post-operative anorectal manometry and pudendal nerve conduction times. Only 10 had stress incontinence. Polypropylene mesh tapes were inserted in the position of the pubourethral ligament (n = 3), uterosacral ligament (n = 9) and both ligaments (n = 18). Surgery was guided by the same diagnostic algorithm used to manage urinary incontinence (see Fig. 1, Theory paper). RESULTS. All patients were discharged within 24 hours of surgery. Post-operative assessment included anal manometry and pudendal nerve conduction time (PNCT) assessments. Twenty-five patients (83%) reported >85% improvement in their fecal incontinence symptoms. Low mean anal pressure, low squeeze pressure, prolonged pudendal nerve conduction times (n = 15) and thinned internal anal sphincters (n = 13) were not predictors of surgical success or failure, nor did these parameters change significantly with surgery. Only the functional anal length demonstrated a mildly significant improvement post-operatively (p = 0.049). Cure rates varying between 76% and 100% were reported for the various urinary symptoms. CONCLUSION. The results indicate that damaged pelvic ligaments may be an important cause of idiopathic fecal incontinence, possibly by inactivating the anorectal closure muscles.

Key words: Fecal incontinence; PNCT; Urinary incontinence; Connective tissue; Integral Theory.

INTRODUCTION

The cause of idiopathic fecal incontinence (FI) is at present unknown. In 1985 Swash et al. published a unifying theory of urinary and fecal incontinence based on striated muscle damage. This work was inspired by evidence of pudendal nerve damage in many patients with double incontinence (urinary and fecal).¹

In 1993, based on obstetric ultrasound studies, Sultan et al hypothesized a link between damaged internal anal sphincters and fecal incontinence.² Neither of these theories^{1,2} assigns a role for damaged connective tissue in the causation of fecal incontinence. In 1999, it was observed that in 25 patients with double incontinence (stress urinary and idiopathic fecal incontinence) both types of incontinence were cured simultaneously following a midurethral sling operation.³ These findings were replicated by Dr Ian Hocking (paper No. 9, this issue). Three patients from that cohort³ subsequently reported recurrence of their FI coincident with development of uterovaginal prolapse. Both conditions, prolapse and FI, were cured with a posterior vaginal sling (infracoccygeal sacropexy).

Two hypotheses followed naturally from these observations

1. Both anterior (pubourethral) and posterior (uterosacral) suspensory ligaments may play a role in anorectal closure.

2. Damaged connective tissue was most likely a major cause of idiopathic fecal incontinence, as this was the only structure repaired.

The primary aim of this study was to prospectively test these hypotheses, by surgically implanting polypropylene tapes to reinforce damaged pelvic ligaments in patients with idiopathic fecal incontinence.

Royal Perth Ethics approval was obtained for the surgical procedures.

METHODS

Inclusion criteria were a history of solid or liquid fecal incontinence which, during episodes, occurred at least once a day. The only exclusion criterion was a torn external anal

sphincter. The same pictorial diagnostic algorithm used to guide urinary incontinence surgery was applied to guide the site of surgery (cf Fig. 1, Theory, Part 1).

Polypropylene tapes were inserted in the position of the pubourethral ligaments (PUL) (n = 3), uterosacral ligaments (USL) (n = 9), or both (n = 18) (Fig. 1), using the IVS tunneller (Tyco, Norwalk CT, USA). The perineal body and rectovaginal fascia were repaired simultaneously in all patients who had the posterior sling. Pre and post-operative anal manometry and nerve conduction studies objectively monitored the clinical outcomes.

At the 1st visit, all patients had a structured assessment⁴ including a self-administered semi-quantitative questionnaire, vaginal and rectal examinations, incontinence diary, transperineal ultrasound, urodynamics, and 2 pad tests, 10

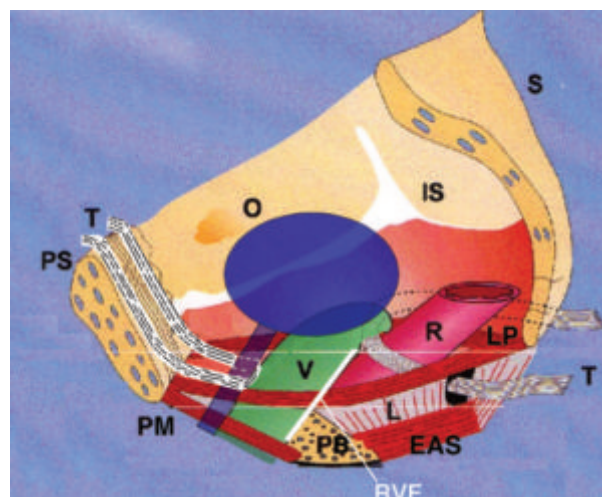


Fig. 1. – Surgery schematic 3D sagittal section. Implanted “tension-free” tapes “T” create collagenous pubourethral neoligaments anteriorly and uterosacral ligaments posteriorly. V = vagina; LP = levator plate; L = longitudinal muscle of the anus; PB = perineal body; EAS = external anal sphincter; LP = levator plate; IS = ischial spine; O = obturator membrane; RVF = rectovaginal fascia. LMA = m. longitudinal muscle of the anus; PCM = m. pubococcygeus; PUL = pubourethral ligament; USL = uterosacral ligament.

coughs to measure urine loss for stress incontinence, and a 24 hour pad test to assess 24 hour urine loss. These were performed by the gynecological team. On a second pre-operative occasion, a radiologist skilled in the procedure performed endoanal ultrasound to detect damage to the internal and external sphincters. On a 3rd pre-operative occasion the patients were independently assessed by the Dept of Colorectal surgery which also tested anal pressures (manometry) and pudendal nerve conduction times (PNCTs). The decision as to which ligaments to repair was guided by the symptoms and examination findings as summarized by the pictorial diagnostic algorithm.⁴ Post-operative anal manometry and PNCTs were performed by colleagues from the Dept of Colorectal surgery, who also reviewed the patients with regard to the fate of their fecal incontinence. The gynecological team objectively assessed the fate of the urinary incontinence with post-operative pad tests, ultrasound, and urodynamics. The patient self-assessed the percentage rate (0-100 scale) of improvement in her fecal incontinence, and urinary urgency. Frequency (>10/day) and nocturia (>2 night) were assessed with a validated semiquantitative questionnaire.⁴

RESULTS

Thirty patients were studied, all with "idiopathic" fecal incontinence, two of whom had thinned, but not torn, external anal sphincters. Only 10 patients had stress incontinence. The others had other bladder symptoms such as urgency, frequency and nocturia. Their mean age was 57 years (range 32-74 years), mean parity 2.7 (range 0-5). The main criterion for fecal incontinence cure, and also, frequency, urgency and nocturia cure, was a symptomatic improvement of 85% or more as assessed by the patient using a 0-100 scale. Of the 25/30 patients (83%) who were cured of fecal incontinence, 20/25 attended for post-operative manometry and PNCTs. No post-operative testing was performed in the 5 patients with failed surgery. Only one patient was nulliparous, and she was cured of fecal incontinence with a midurethral sling operation. In addition to fecal incontinence, 10 patients had stress urinary incontinence (SI), and all were cured of their SI. Twenty-five patients had urinary frequency, nocturia and urgency (FNU), and 19 (76%) were cured of their FNU. All patients were discharged within 24 hours of surgery, and were reviewed at 6 weeks and at 6 monthly intervals thereafter. The mean post-operative assessment time was 16 months (range 6-24 months).

Mean anal pressure (MAP), squeeze pressure, pudendal nerve conduction times (PNCT) and thinned internal anal sphincters were not predictors of surgical success or failure. Only the functional anal length demonstrated any significant change post-operatively, and then only minimally ($p = 0.049$).

Taking 40 mm Hg as normal, mean anal pressure (MAP) was low in 14 patients, and only 2 of these were not cured of fecal incontinence by the surgery. Post-operatively, MAP increased in 8 patients, decreased in 7 and remained similar in 5. Of the 7 patients cured of fecal incontinence but whose post-operative MAPs remained well below 40mm Hg, 5 improved their MAP only marginally, while 2 recorded a definite fall in MAP.

Taking 100 mmHg as a normal squeeze pressure, 11 patients were normal pre-operatively. Post-operatively, 11 patients showed a demonstrable increase, and 9 a decrease in their pre-operative squeeze pressures.

Pre-operatively, taking 2.2 seconds as a normal conduction time, 15/30 patients had abnormal pudendal nerve conduction times (PNCT) times on the right side, and 10/30 patients on the left side.

Of the 20 post operative PNCTs performed, allowing 0.2 seconds as a margin for measurement error, 5 patients increased their conduction times, and 2 decreased their conduction times in either the left or right side. The other PNCTs were unaltered.

Functional anal length (FAL) increased in 10 patients, decreased in 2, and was unaltered in the other 8. This was the only significant result ($p = 0.049$).

The internal anal sphincter was thinned in 13 patients (43%) and 2 of these were not cured of fecal incontinence.

Of the 5 patients not cured of fecal incontinence, 3 had normal PNCTs at least on one side, 3 normal MAPs, and one had normal squeeze pressures. Two of the 5 patients were cured entirely of their bladder problems, but not their FI problems. Of the other 3, two were cured for a short period of 6 weeks of both fecal incontinence and urinary incontinence, and both recurred after 6 weeks, first the urinary then the fecal.

One of the 2 patients with a thinned (but not ruptured) external anal sphincter (EAS) was cured of passive liquid soiling but continued to have fecal incontinence with "intestinal hurry". She was cured of the latter with a subsequent EAS and post-anal repair. For the purposes of this study, she has been classified as an operative failure. The other patient with thinned EAS was cured of her fecal incontinence and reported return of the ability to discriminate between wind and liquid feces following repair of both pubourethral and uterosacral ligaments. One patient reported 50% cure of her FI after repair of her anterior ligaments, and 100% cure after her posterior ligaments were repaired at a later date. Another patient reported 70% cure after the anterior tape repair, then 100% cure after the posterior tape repair. Two patients initially failed to respond to the posterior ligament reconstruction and remained incontinent of both urine and feces. Both were obese and it was reasoned the tapes had slipped. On repeating the posterior sling procedure, both were restored to continence of urine and feces. Both were classified as cured. No significant complications such as organ perforation, tape erosion, haemorrhage or infection occurred.

DISCUSSION

This study differs considerably from Hocking's study (No. 9, this issue), and a previous study.³ Only 10/30 patients from this group had associated urinary stress incontinence symptoms (pubourethral ligament defect (Fig. 1). Twenty patients had no SI whatsoever. Their associated symptoms were FNU (frequency, nocturia, urgency), consistent with a uterosacral ligament defect. The results indicate that posterior ligament laxity may also be an important cause of idiopathic FI, and this has been validated in studies No. 11&12.

It was radiologically demonstrated (Part 1), that the pelvic floor muscles effectively contract against the pubourethral and uterosacral ligaments. The theory predicts that: laxity in these anchoring ligaments may not allow the closure muscles to work properly, so that leakage of both urine and feces may occur; reinforcing these ligaments with polypropylene tapes will restore the weakened muscle forces, and therefore, continence. This was largely validated by the surgical study, but not entirely. A significant number of patients (17%) were not cured of their FI symptoms. Others achieved a good, but sub-optimal improvement (85%), suggesting either incomplete anatomical restoration, or other causation. The inherent inaccuracy of the diagnostic algorithm, and other as yet unknown causes may explain the former. The muscle damage hypothesis provides a rational explanation for the latter, given the fundamental tenet of the Musculo-Elastic Theory as described in Part 1, that an adequate muscle force is required to effect anorectal closure (continence).

We explain cure of FI in patients with pudendal nerve damage in our study (prolonged PNCT) as follows: the same pelvic floor muscles responsible for anorectal closure contract to contain the intra-abdominal organs. This indicates these muscles may possess reserves of strength far greater than required just for anorectal closure. Restoring the effective insertion points for these muscle forces, the suspensory ligaments, enables a damaged muscle to contract more efficiently, sufficient in many cases to cure fecal incontinence.

Partial cure in 2 patients with restoration of the anterior ligament followed by total cure after posterior ligament reconstruction indicates that the control of fecal continence is likely to be synergistic, similar in fact to the mechanism proposed for continence control in the bladder.⁴

Occurrence of fecal incontinence in nulliparas^{3,5} can only be explained by congenital collagen deficiency. Surgical cure by tape implantation in this and a previous study³ is consistent with a connective tissue aetiology such patients.

Of 13 patients with damaged IAS, 11 were cured. Seventeen patients had FI and normal IAS. This accords with previous data.³ The IAS damage hypothesis cannot explain the results of this work.

There was no statistical correlation between mean anal pressure (MAP) and squeeze pressure in patients who reported clinical cure, suggesting that low intra-anal pressures may not be a major factor per se in the causation of fecal incontinence. Pressure is not necessarily the same thing as closure. Pressure within a tube = Force/Area over which the force is exerted. Closure implies a water-tight resistance to leakage. Many other factors may play a role in closure, for example, stretching and narrowing of the tube (Pressure = Tension/radius, 'Laplace's law'), resistance within the tube (Resistance varies with tube length/4th power of the radius, 'Poiseuille's law'), and anal mucosal sealing, which we attribute to the internal anal sphincter. A restored musculoelastic mechanism would stretch the rectal tube backwards and downwards more efficiently to narrow the lumen. This creates an exponentially raised resistance within the lumen.⁶ For example, halving the anorectal diameter will increase the intra-anal resistance by a factor of 16. The exponential increase in intra-anal resistance with even a small decrease in diameter explains how evacuation difficulties may occur without any detectable mechanical obstruction.

Cure of urinary but not fecal incontinence in some patients indicates the causative relationship between urinary and fecal incontinence is not absolute.

CONCLUSIONS

Connective tissue damage in the anterior and posterior suspensory ligaments appears to be a significant cause of idiopathic fecal incontinence. Anal manometry and nerve conduction studies do not appear helpful in predicting surgical success or failure, and they are not at all useful in predicting which ligament has been damaged. The pictorial diagnostic algorithm is helpful in this regard, but only as a guide to surgery. It cannot directly assess the condition of each ligament. Given this limitation, one solution would be to routinely repair both anterior and posterior ligaments simultaneously in all patients with FI. However, such a solution would not help if there were other contributing causes, such as middle zone defect (damaged ATFP, cardinal ligaments), or severe muscle damage. Future pre and postoperative morphological studies using MRI, 3D and 4D ultrasound may help to further elucidate the role of specific muscles and ligaments. Study No. 11 attempts to assess the adjunctive role (if any) of damaged ATFP and cardinal ligaments in FI causation.

REFERENCE

1. Swash M, Henry MM, Snooks SJ. Unifying concept of pelvic floor disorders and incontinence. *Journal of the Royal Society of Medicine* 1985; 78: 906-911.
2. Sultan AH, Kamm MA, Hudson CN, Thomas JM and Bartram CI. Anal-sphincter disruption during vaginal delivery, *N Eng J Med* 1993; 329: 1905-11.
3. Petros PE. Cure of urinary and faecal incontinence by pelvic ligament reconstruction suggests a connective tissue aetiology for both. *International Journal of Urogynecology* 1999; 10: 356-360.
4. Petros PE and Ulmsten UU. An Integral Theory and its method for the diagnosis and management of female urinary incontinence. *Scand J Urol Nephrol* 1993; 26 (Suppl. 153): 1-93.
5. Parks AG, Swash M, Urich H. Sphincter denervation in anorectal incontinence and rectal prolapse. *Gut* 1977; 18: 656-665.
6. Bush MB, Petros PEP, Barrett-Lennard BR. On the flow through the human urethra. *Biomechanics* 1997 30: 967-969.

ACKNOWLEDGEMENTS

Mr Graham Hool, Dept of Surgery RPH, Dr Jim Anderson, Dept of radiology, RPH.

Correspondence to:

PETER PETROS

E-mail: kvinno@highway1.com.au

Study No. 11: Ligamentous repair using the Tissue Fixation System confirms a causal link between damaged suspensory ligaments and urinary and fecal incontinence

BURGHARD ABENDSTEIN^(*) - PETER PETROS^(**) - PETER RICHARDSON^(***)

^(*) Dept of Obstetrics and Gynaecology, Hall, Austria, ^(**) Royal Perth Hospital, University of Western Australia,

^(***) Gallier's Hospital, Armadale, Western Australia

Abstract: AIM. The aims of this study were: 1. To test the efficacy of a less invasive method (TFS) for tape implantation in patients with vaginal prolapse, urinary and fecal incontinence; 2. To test the contribution of ATFP/cardinal and their attached fascia (cystocoele repair), if any, to causation of fecal incontinence. PATIENTS AND METHODS. Eighty-one patients, mean age 60.1, mean weight 69 kg (43-112 kg), mean 2.0 previous pelvic operations, underwent 154 site specific operations in the 3 zones of the vagina as primary procedures using the Tissue Fixation System (TFS). The site of operation(s) was determined by reference to a pictorial diagnostic algorithm: pubourethral ligaments, n=43; ATFP, cardinal ligaments, (cystocoele) n = 39; uterosacral ligaments (apical prolapse), n = 72. The patients were assessed with a 24 hour urinary diary, structured questionnaire, transperineal ultrasound, urodynamics, cough stress test, and 24 hour pad test, pre and post-operatively at mean 12 months (6-18 months). RESULTS. Symptom improvement was as follows: fecal incontinence (n = 33) 88%, stress incontinence (n = 43) 89%, urgency and nocturia (n = 50) 80%. CONCLUSIONS. Both urinary and fecal incontinence (FI) symptoms were simultaneously cured, indicating a causal link. Repair of ATFP and cardinal ligament defects (cystocoele) did not produce a significantly higher cure rate for FI to that achieved by repairing just the anterior and/or posterior suspensory ligaments in studies No 9 & 10, indicating perhaps, the primacy of anterior and/or posterior suspensory ligaments in FI control.

Key words: TFS sling; Prolapse; Stress incontinence; Nocturia; Pelvic pain; Fecal incontinence; Integral Theory.

INTRODUCTION

In 1990 the concept of using a plastic tape to create artificial neoligaments ('tension-free tapes') was introduced.^{1, 2} We have reported how reinforcement of the pubourethral ligament (Study No. 9, this issue) and pubourethral/uterosacral ligaments with anterior/posterior "tension-free" slings successfully improved bladder and bowel symptoms. In 2005 the TFS (Tissue Fixation System) (Fig. 1) was introduced as a safer, less invasive method for inserting plastic slings for use in patients with stress incontinence,³ vaginal prolapse⁴ and cystocoele. Though the principle of artificial neoligament formation² is identical for the "tension-free" and TFS systems, there are important differences. All "tension-free" slings enter vaginally and exit more distally via the skin. The TFS sling is positioned entirely per vaginam. It can be accurately tensioned, and it can be used to repair damaged connective tissue structures in the pelvic floor not accessible to the "tension-free" system, in particular, the pubocervical and rectovaginal fascia, cardinal ligaments, and Arcus Tendineus Fascia Pelvis.

The aims of this study were

1. To test the efficacy of the less invasive TFS method for tape implantation in patients with vaginal prolapse, urinary and fecal incontinence.

2. To examine the contribution, if any, of middle zone fascial defect (cystocoele repair) to fecal incontinence.

Ethics Committee approval was obtained from the Royal Perth Hospital for these operations.

PATIENTS, MATERIALS AND METHODS

Eighty-one patients, mean age 65 (range 35-87), parity 2.7 (range 0-8) weight 69 kg (43-112kg) mean age 60.1 years, (33-88) parity 2.6 (0-8) had one or more surgeries performed simultaneously. Mean number of previous pelvic floor operations (including hysterectomy) was 2.0 per patient (range 0-10 operations). Only 23 patients had not had prior surgery. Forty-four patients (54%) had undergone prior hysterectomy. A single shot antibiotic consisting of amoxicillin and clavulanic acid was given intravenously on induction

of anaesthesia in all operations. In 12 (14.8%) of patients, the operations were performed under local anaesthesia/sedation.

Pre-operative assessment. The patients completed a structured questionnaire, 24 hour urinary diary, cough stress test, and 24 hour pad test. The symptoms were checked against the diagnostic algorithm (Fig. 2) to indicate the zone of connective tissue damage, anterior, middle, posterior. Vaginal examination,⁶ involved inspection for damage to 9 potential structures (Fig. 2). Transperineal ultrasound and urodynamic testing were also performed. In some patients with urinary urge symptoms, the office technique of "simulated operations"^{6,7} was used to achieve a more accurate diagnosis, as laxity in any zone (Fig. 3) may cause stress or urge symptoms.

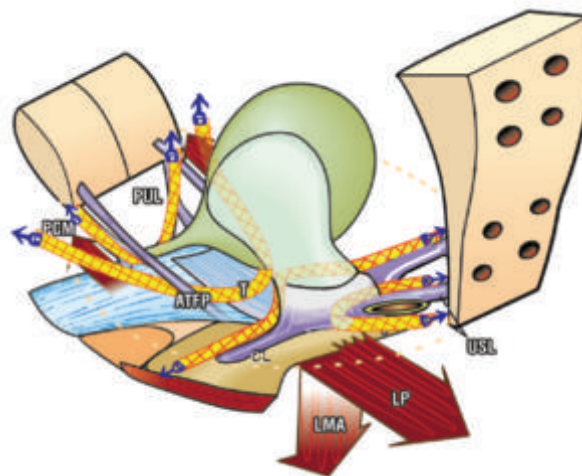


Fig. 1. – TFS anchor. The polypropylene tape is applied under direct vision, using the anchor to fix it adjacent to the damaged ligament or fascia: pubourethral (PUL), arcus tendineus fascia pelvis (ATFP), cardinal ligament (CL), uterosacral (USL). A one-way tightening mechanism at the base of the anchor tensions the tape to restore optimal length, and therefore function, of the damaged structure.

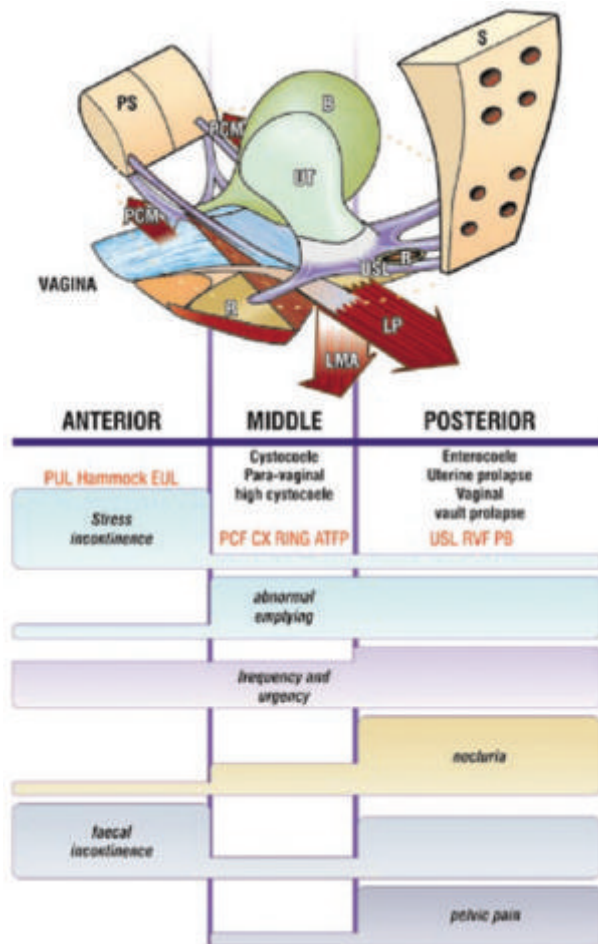


Fig. 2. – The Pictorial Diagnostic Algorithm was used to determine where the TFS tapes were to be applied. The algorithm summarizes the relationships between connective tissue damage in the three zones and symptoms. The size of the bar gives an approximate indication of the prevalence (probability) of the symptom. Connective tissue structures in each zone may cause prolapse and abnormal symptoms.

The patients were monitored at 6 weeks, and at 3 monthly intervals thereafter using a 24 hour urinary diary, structured questionnaire, cough stress test, 24 hour pad test, transperineal ultrasound and, where possible, urodynamic investigation.

Criteria for symptomatic improvement post-operatively were: stress incontinence: no urine loss during 10 coughs with a full bladder; nocturia: <2 episodes per night; urge incontinence (UI): self-assessed improvement expressed as a VAS percentage; faecal incontinence (FI) :>80% VAS improvement. The threshold for FI diagnosis was one soiling /day.

The anterior TFS sling operation (n = 43). The surgical technique for the anterior TFS sling³ is almost identical to that for the “tension-free tape” operation, except that the anchors insert on the under surface of the pelvic muscles (Fig. 3), and the tape is tightened via a one-way trapdoor at the anchor base.

Operation. Midline incision to midurethra; vagina dissected off the urethra; penetration of the urogenital diaphragm to a depth of 1 cm by the TFS applicator; release of the TFS anchor; procedure repeated on the contralateral side; tape tensioned over an intraurethral 18G Foley catheter; free ends of tape trimmed; vaginal hammock fascia and the external ligaments tightened with 2-0 Dexon sutures; no cystoscopy. Mean operating time was 5 minutes.

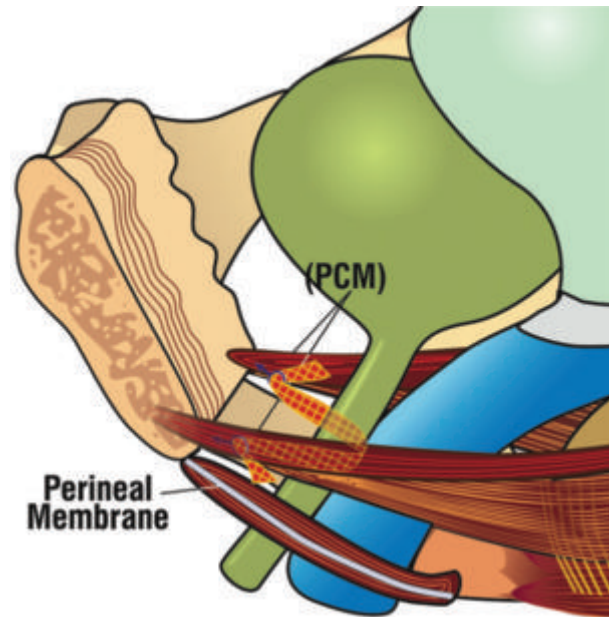


Fig. 3. – Anterior TFS sling. 3D sagittal view. A polypropylene mesh tape sited at midurethra and attached in the pelvic muscles below pubic symphysis (PS) reinforces the pubourethral ligament.

The posterior TFS sling. Primary uterosacral ligament (USL) repair⁴ was undertaken in 72 patients. The posterior TFS sling anchors the apical fascia into the uterosacral ligaments ‘USL’ (Fig. 4), much like a McCall operation.

Operation: Full thickness, 2.5cm transverse incision was made in the vaginal apex, 2 cm below the cervix, or just below the hysterectomy scar; uterosacral ligament remnants grasped with Allis forceps; fine dissecting scissors created a 4-5 cm space adjacent to the USL remnants; applicator inserted into the space; anchor was released and “set” by tugging on the tape; insertion was repeated contralaterally, and tape tightened; tapes trimmed; approximation of rectovaginal fascia as an extra layer to support the tape. Mean operating time 10 minutes.

Rectovaginal fascia and perineal body repair were carried out without any tissue excision. The fascial remnants of the rectocele and perineal body were repaired in 40 patients.

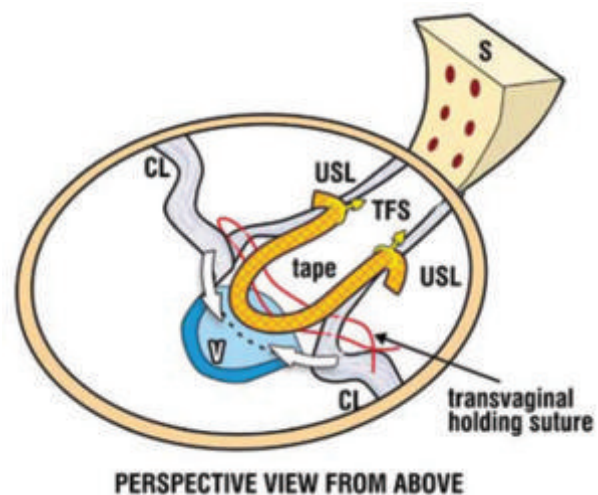


Fig. 4. – Posterior TFS sling. The tape is inserted along the line of the uterosacral ligaments “USL” between USL and vagina “V”. CL=cardinal ligament. The suture approximates the fascia overlying the tapes.

Middle zone repair (cardinal and ATFP ligaments). A different bioengineering principle is applied to that of large mesh. The tapes act like beams of a ceiling, and the vagina like a plaster board to support the prolapsed bladder wall. Unlike large meshes which only create a barrier to an organ herniation, the TFS tapes restore fascial and ligamentous tension by precise tightening of the tape. The correct tension is reached once a resistance is felt. This resistance is probably caused by muscle contraction against the fascia, according to Sturmdorf's 1919 description, "the levator ani is the tensor of the pelvic fascia".⁵

There were 48 primary operations for midzone repair (39 TFS) (Tab. 1).

Standard cystocele repair (n = 9). The vagina was dissected off the bladder without tissue excision and the overly-

TABLE 1. – Structural outcome for primary cystocele/anterior wall repair.

n = 48		
3 rd Degree n = 26		2 nd Degree n = 22
Operation	Patient No	Recurrence
Vaginal repair	9	4
Transverse TFS	22	1
TFS "U" sling	17	1

TABLE 2. – Structural outcome for primary posterior zone repair.

4 th degree: n=4. 3 rd degree: n=18. 2 nd degree: n=20. 1 st degree: n=30			
Operation	Patient No	Recurrence	
Posterior TFS	72	1	

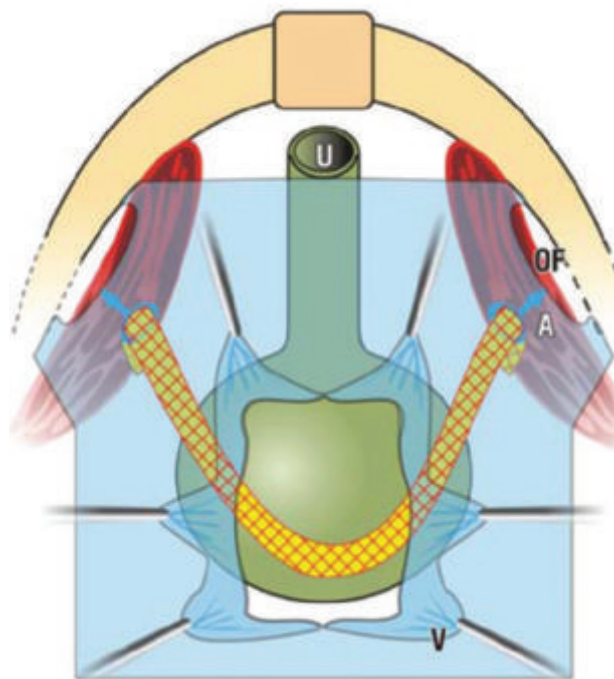


Fig. 5. – TFS "U sling"-View into the anterior vaginal wall. Vagina (V) is dissected off the bladder wall, and stretched laterally. The TFS tape is anchored (A) just medial to the obturator fossa (OF) muscles. Sutures (S) may be used to attach the tape to the vaginal fascia.

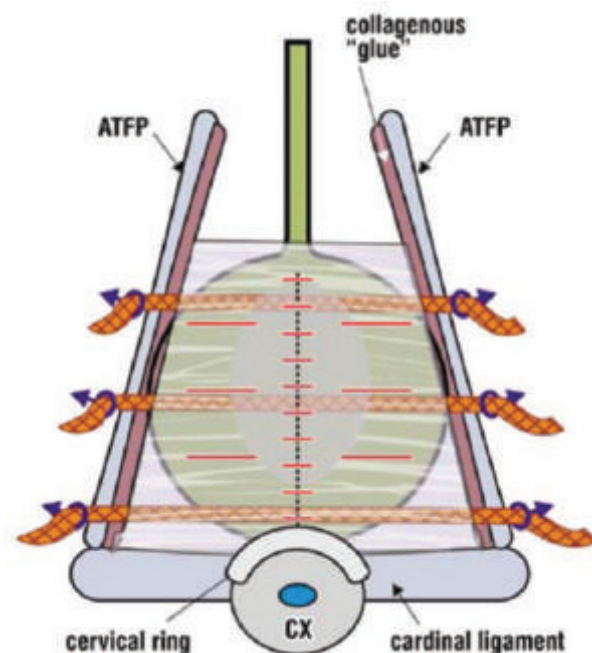


Fig. 6. – Transverse TFS Sling The bladder was dissected from the vaginal wall as laterally as possible. After repair of the fascial fragments, the anchor was attached to the ATFP (Arcus tendineus Fascia Pelvis) or adjoining muscle and tightened. The inferior tape reinforces the cardinal ligament.

ing fascial remnants repaired. This operation was discarded early in the trial because of the poor results (4/9 failures). Subsequently, tapes were used in every instance.

TFS "U sling" (Fig. 5) (total n = 17). The surgical principle was to mimic the arcus tendineus fascia pelvis (ATFP), and to reinforce centrally weakened pubococcygeus fascia. Bladder wall was dissected off the vagina; dissection channel was created to just medial to the obturator fossa; fascial remnants were approximated; TFS was inserted into the channel, the anchor displaced and set. This operation was repeated contralaterally. The tape was tightened just sufficiently to reduce fascial laxity.

Transverse TFS tapes (total n =22). The bladder was dissected off the vagina; the overlying fascial remnants were repaired; one two or three anchors were positioned into the lateral ligamentous tissues (ATFP) as required, and the tapes were tightened (Fig. 6).

RESULTS

General. Eighty-one patients, mean age 60.1 years, underwent 154 TFS operations in the 3 zones of the vagina as primary procedures. These were anterior zone (pubourethral ligament) n = 43, middle zone (ATFP and cardinal ligament) n = 39, posterior zone (uterosacral ligaments) n = 72. Mean hospital stay was 2.5 days (1-10 days). Mean post-operative review time was 12 months (range 6-18).

Post-operative course. In patients who had not undergone perineal body repair, only 2 required opiates post-operatively. Most patients were managed simply with paracetamol. Many patients who had previously undergone "tension-free tape" operations, reported a significant difference in post-operative pain and discomfort, an observation echoed by the recovery room and ward staff. Six patients (7%) developed urinary tract infection within 4 weeks of discharge and these were treated with antibiotics.

There were no cases of post-operative retention, haematoma or infection. All patients passed urine spontaneously.

Structural. Results are summarized in Tables 1 & 2. Two failed cystocele repairs were successfully re-operated with the U-sling TFS. There was one failure of vault prolapse repair, and evidence of rectocele / perineal body recurrence in 4 patients.

Symptomatic. All 33 patients with fecal incontinence had intact external anal sphincters, and were classified as having idiopathic fecal incontinence (FI). Symptomatic improvement >80% was noted in 88% of these patients for FI, 89% for stress incontinence (n = 43), and 80% for urgency and nocturia (n = 50). No erosions or dyspareunia have been reported to date.

DISCUSSION

The improvement rate for fecal incontinence using the TFS was equivalent to that reported for “tension free” anterior and posterior sling surgery (Studies No 9 & 10, this issue), and previously for other pelvic symptoms.⁸⁻¹⁰ This indicates that the TFS can be used as a safer and equally effective substitute for “tension free” sling surgery, especially in the old and infirm.

This study differed from studies No 9 & 10, in that middle zone ligamentous defects (cystocele) were also repaired. This extra operation did not appear to significantly improve the FI cure rate, indicating, perhaps, that the AFTP and cardinal ligaments (Fig. 3), may not be a significant cause of FI.

Even patients considered as gross failures in one area (e.g., urge incontinence) had cures in other areas (e.g., fecal incontinence, stress incontinence, urgency/nocturia). This appears to support the anatomical classification (Fig. 3), whereby some symptoms such as stress incontinence and nocturia may be largely zone specific, while others such as urge incontinence may occur across any zone.

The longer-term efficacy for FI cure by the TFS has not as yet been assessed. Recent data for stress incontinence indicates minimal deterioration at 3 years.¹¹

CONCLUSIONS

The TFS appeared to work as efficiently as the “tension-free tape” slings, but with greater safety and less invasiveness. Therefore it is especially applicable to aged and frail patients. Both urinary and fecal incontinence symptoms were simultaneously cured by suspensory ligament recon-

struction, indicating a causal link. It does not appear likely that the middle zone ligaments, AFTP and cardinal, play a major role in FI control.

REFERENCE

1. Petros PE & Ulmsten U. An Integral Theory of Female Urinary Incontinence, Acta Obstet Gynecol Scand. 1990; Suppl No 153: 1-79.
2. Petros PE, Ulmsten U and Papadimitriou J. The Autogenic Neoligament procedure: A technique for planned formation of an artificial neo-ligament. Acta Obstet Gynecol Scand 1990; 69; Supp. 153: 43-51.
3. Petros PEP, Richardson PA. The midurethral TFS sling - a ‘micro-method’ for cure of stress incontinence - preliminary report. ANZJOG 2005; 45: 372-375.
4. Petros PEP, Richardson PA. The TFS posterior sling for repair of uterine/vault prolapse-a preliminary report. ANZJOG 2005; 45: 376-379.
5. Sturmdorf A. The levator ani muscle. In: Gynoplastic Technology, FA Davis, Philadelphia 1919: 109-114.
6. Petros PEP. The Female Pelvic Floor, Function, Dysfunction and Management, according to the Integral Theory. Springer Heidelberg, Ch 2, 3 & 4, Diagnosis of Connective Tissue damage, Surgery 2004; 14-138.
7. *idem*, Ch 6, Dynamic Mapping with ‘simulated operations: a clinical example, 169-175.
8. Petros PE. New ambulatory surgical methods using an anatomical classification of urinary dysfunction improve stress, urge, and abnormal emptying. Int J Urogynecology 1997; 8: 270-278.
9. Farnsworth BN. Posterior Intravaginal Slingplasty (infracoccygeal sacropexy) for severe posthysterectomy vaginal vault prolapse - a preliminary report. Int J Urogynecol 2002; 13: 4-8.
10. Ulmsten U, Henriksson L, Johnson P, and Varhos G. An ambulatory surgical procedure under local anesthesia for treatment of female urinary incontinence. Int Urogynecol J 1996; 7: 81-86.
11. Petros PE, Richardson PA. Midurethral Tissue Fixation System (TFS) sling for cure of stress incontinence - 3 year results. International J Urogynecology 2008; in press.

Competing Interests: the 2nd author (Petros) has an interest in the IP of the TFS instrument.

Correspondence to:

PETER PETROS

E-mail: kvinno@highway1.com.au

Study No. 12: Role of the uterosacral ligaments in the causation of rectal intussusception, abnormal bowel emptying, and fecal incontinence. A prospective study

BURGHARD ABENDSTEIN^(*) - CHRISTINA BRUGGER^(*) - ANTON FURTSCHEGGER^(*)
MICHAEL RIEGER^(**) - PETER PETROS^(***)

() Bezirkskrankenhaus Hall in Tirol, (**) Innsbruck University Hospital, Austria, (***) Royal Perth Hospital, Perth, Western Australia*

Abstract: The aim of this study was to assess the role of damaged uterosacral ligaments and associated rectovaginal fascia in the causation of rectocele, rectal intussusception, evacuation disorders and fecal incontinence. **METHODS.** 48 patients with various degrees of vaginal vault descensus, clinical rectoceles and defecatory dysfunctions were treated by insertion of a posterior IVS (syn: infracoccygeal sacropexy), reconstruction of the rectovaginal fascia and perineal body repair. **RESULTS.** Of the 48 patients with evacuation difficulties, 45 (94%) patients reported complete normalization of defecation at both visits after surgery. Of the 27 patients with fecal incontinence, 18 (66%) reported cure, 5 (19%) >50% improvement, and 4 no change. Postoperative proctograms showed resolution of the rectal intussusception in 89% and 94% reported completely normal defecation after surgery. **CONCLUSIONS.** Connective tissue damage to the anterior rectal wall supports may cause it to sag inwards, "intussusception". The posterior sling creates a foreign body reaction which reinforces the damaged uterosacral ligament and "reglues" the ligament's attachments to levator plate, cervical ring and rectovaginal fascia to suspend and stretch the rectal wall.

Key words:

INTRODUCTION

Rectoceles are common findings in patients with intractable evacuatory disorders. Typical symptoms are difficulties to evacuate, incomplete evacuation, assisted digitation to aid defecation, fecal incontinence, constipation, impression of a pelvic mass, pelvic pain and dyspareunia. Occult rectal prolapse has been found in 33% of patients with rectoceles and defecatory dysfunction.¹ Endorectal, transvaginal, transperineal, abdominal or combined approaches are treatment options discussed for symptomatic rectoceles. In the presence of rectal intussusception, open or laparoscopic rectopexy, with or without sigmoid resection, is still most widely accepted. Although the anatomic results are mostly good, all procedures widely lack functional improvement. This is in particular true for posterior colporrhaphy² abdominal sacrocolpopexy^{3, 4} and rectopexy,⁵ all resulting in increasing defecatory dysfunctions.

In the normal pelvis, the sacrouterine ligament functions as the most important supporting structure for the uterus, vaginal apex and via the rectovaginal fascia, also for the posterior vaginal wall and rectum (Fig. 1).

The rectovaginal fascia (RVF) attaches to the perineal body (PB) below and levator plate (LP) above.⁶ The levator plate is attached to the posterior wall of the rectum. Contraction of the levator plate (LP) stretches both walls of the rectum during anorectal closure and defecation.

In cases with disrupted rectovaginal fascia, a rectocele may form. Due to distended sacrouterine ligaments, the rectum can no longer be kept in its normal position, and consequently proximal rectal parts may bulge into the distal rectum causing intussusception (syn. internal rectal prolapse) (Fig. 2).

According to the Integral Theory,⁷ dysfunctions of anorectal opening (evacuation disorders) and closure (fecal incontinence) are mainly caused by connective tissue damage in the vagina or its suspensory ligaments. The explanations offered above expand these concepts to the pathogenesis of rectal intussusception.

The infracoccygeal sacropexy ("posterior IVS")⁸ procedure belongs to the family of "tension free tape" operations. An implanted polypropylene tape (Tyco Healthcare), reinforces the uterosacral ligaments by irritating the tissues to

create a linear deposition of collagen. In contrast to other methods which aim at fixation of the rectum, the infracoccygeal sacropexy does not attach the vagina or the rectum firmly to bony structures. It allows the surgeon to restore the normal vaginal axis and the rectovaginal fascia anatomically correctly, thereby reestablishing normal function.

We could see the following reasons for the use of an IVS polypropylene sling in order to treat symptomatic rectoceles with intussusception.

1. Baden and Walker pronounced their tent theory⁸ stating that if the top of a tent caves in, the walls may follow. This translates for the vaginal situation that the first step in the treatment of vaginal or even rectal prolapse should be the restoration of a competent apical fixation, namely restoration of the sacrouterine ligaments by insertion of a polypropylene tape (posterior IVS). Important in this type

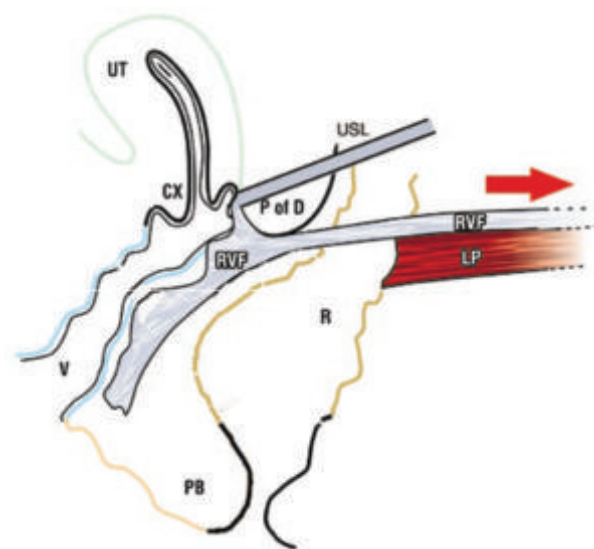


Fig. 1. – Normal anatomy. Schematic 3D sagittal view. The rectovaginal fascia (RVF) is suspended by a competent uterosacral ligament (USL) inserting into the cervical ring (CX), and tensioned by contraction of levator plate muscle (LP) pulling against perineal body (PB) and USL. P of D = Pouch of Douglas.

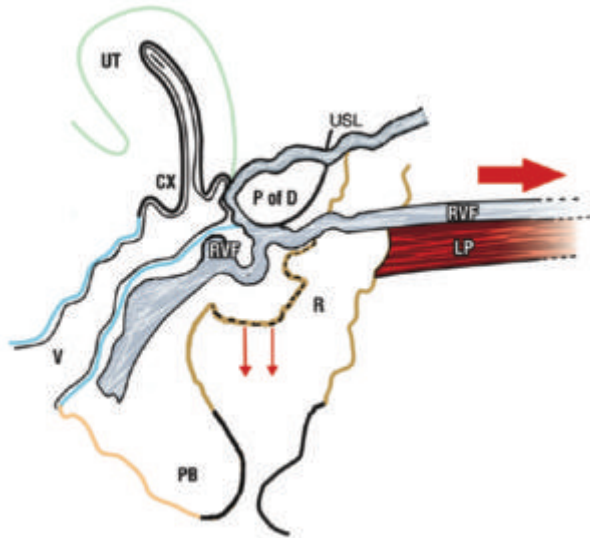


Fig. 2. – Rectal intussusception USL is lax; LP cannot tension RVF: force of gravity (small arrows) causes the rectal wall (R) to prolapse inwards, much like a tent whose apex is not firmly attached to the pole, “rectal intussusception”.

of anatomical restoration is buttressing of the side walls, namely the rectovaginal fascia in cases of a rectocele.⁹

2. The technique of posterior IVS follows the Integral Theory surgical principles, that “restoration of function follows restoration of form”.¹⁰ As we did not only wish to cure anatomical defects, but functional disorders also, we believed that restoring the ligamentous supports of the organs was more promising than other methods that work by stretching the organ and attaching it to fixed structures, either the rectum (rectopexy) or the vagina (sacrocolpopexy).³⁻⁵

3. Prior surgical experience with the Posterior IVS operation (PIVS) (Fig. 3), in patients who had prolapse, and who were also cured of their defecatory problems, suggested to us that this principle could be widely applied in patients with symptomatic rectocele and rectal intussusception.¹¹

Our aim in this study was to prospectively test this hypothesis by reconstructing the posterior zone anatomy, uterosacral ligaments, rectovaginal fascia, and perineal body.⁹⁻¹¹

MATERIAL AND METHODS

Between October 2001 and October 2004, 48 patients aged between 39 and 86 years with vaginal vault descensus I to III and clinical rectoceles presented with obstructive defecation symptoms. All patients were asked to complete a symptom focused questionnaire. After clinical assessment they underwent single contrast defecating proctography. Only patients with clear signs of rectal intussusception were included in the study. Written consent was obtained from all participants. Preoperative bowel preparation consisted of oral X-Prep (extract of mustard leaves) on the day before surgery and a micro-enema in the morning before surgery. The anus was covered with a sterile transparent drape during the entire procedure. All patients underwent the same type of surgery, that was a 3-level repair of the posterior compartment of the pelvic floor. In level 1 (apex) a posterior IVS-tape was inserted as published earlier for reinforcement of the sacrouterine ligaments, “Level 1 repair” (Fig. 3).⁹ In patients requiring level 2 repair (Fig. 3), the rectovaginal fascia was reconstructed conventionally in 28 cases using mattress sutures to approximate the disrupted edges of the

rectovaginal fascia defect. In 2 cases the “bridge technique” was used to repair the Level 2 defect.⁹ This technique uses a cutaneous flap of the posterior vaginal wall to bridge the distance between the ruptured edges of the rectovaginal fascia in the midline. In 18 cases the rectovaginal defect was restored by the insertion of a polypropylene mesh (Sur-gipro, Tyco) underneath the rectovaginal fascia. Level 3 (perineal body) repair was performed in all cases where the perineal body was loose.⁹ Care was taken to strictly follow aseptic surgical technique. Surgery was exclusively performed under general anesthesia. Single shot perioperative antibiotics was provided by amoxicillin and clavulanic acid. A vaginal pack and continuous catheterization were kept for 2 days. Six to nine weeks postoperatively the single contrast defecating proctography was repeated whenever possible. During the same visit and again 6 to 12 months after surgery patients were asked to complete the same questionnaire. Postoperative visits and the clinical assessment were performed by an independent assessor.

RESULTS

Only 20 (42%) patients still had the uterus in place at first visit. Hysterectomy was performed in 12 cases (60%) because of concomitant uterine pathology. The postoperative period was uneventful in all cases. After removal of the Foley catheter, micturition was normal with only minimal residual urine (0-80 ml measured by ultrasound). Discomfort and pain resolved after 3 days, mainly after removal of the vaginal pack. From that time on patients reported just minimal pain, sufficiently managed by oral analgesics (Naproxen) on demand. Patients returned to normal food on the first postoperative day and were discharged on the 7th day after surgery.

Functional results: All patients preoperatively complained about obstructive defecation disorders, and 45/48 (94%) patients reported complete normalization of defecation at both visits after surgery. They stated that no obstruction was felt any longer, no incomplete emptying, no pain and no incontinence or soiling. 3/48 (6%) felt unchanged after surgery regarding the ability to pass stools. However, these patients showed normal defecating proctograms at control.

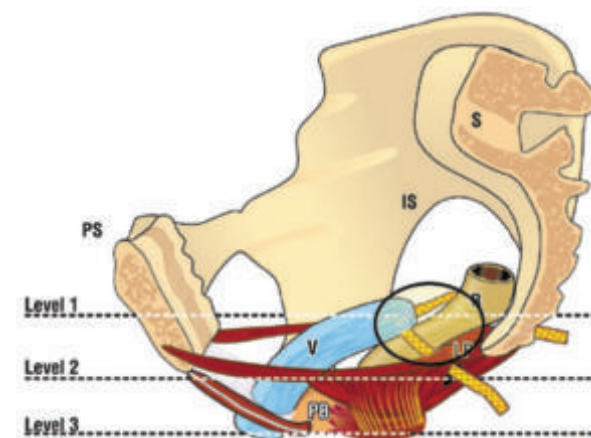


Fig. 3. – Proposed mechanism for surgical restoration of rectal intussusception. Connective tissue damage to the anterior rectal wall supports may cause it to sag inwards, “intussusception”. The posterior sling creates a foreign body tissue reaction (circle) which restores the damaged ligament and “reglues” the fascial attachments to levator plate and cervical ring. This re-suspends the rectal wall, and reconnects the fascia to the levator plate (LP) to stretch and tension the rectal wall to cure the intussusception. PB = perineal body; V = vagina; R = rectum; IS = ischial spine.

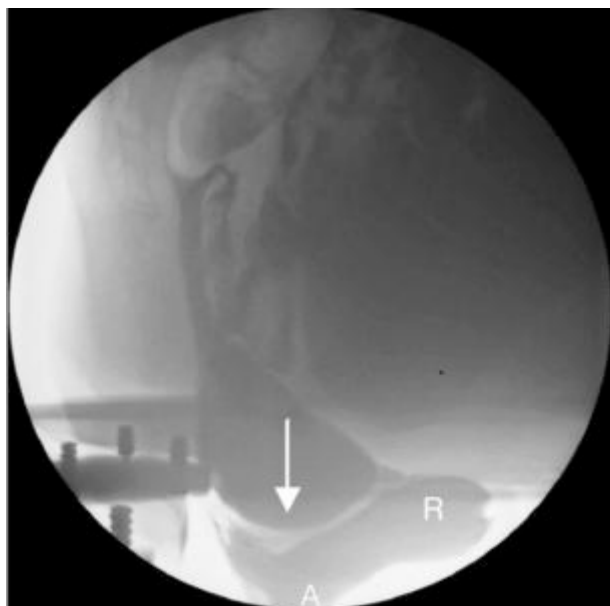


Fig. 4a. – Pre-operative defecating proctogram. Sagittal view, straining. Arrow indicates site of intussusception. R = rectum; A = anus.

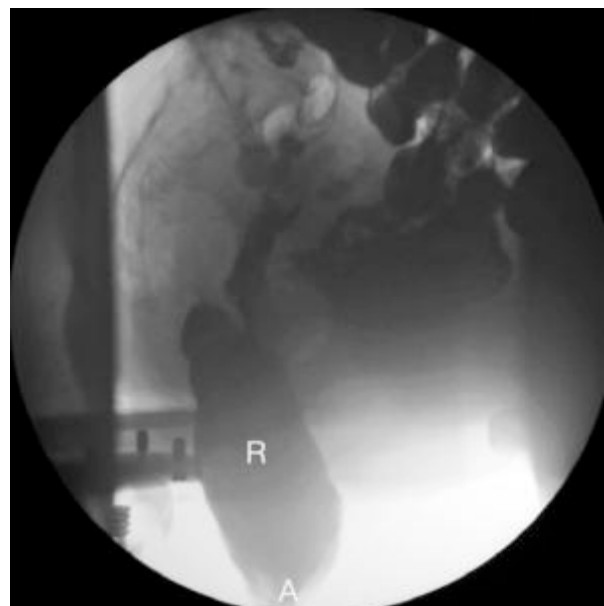


Fig. 4b. – Post-operative defecating proctogram. Sagittal view, straining. The intussusception has disappeared. R = rectum; A = anus.

Of the 27 patients (56%) who complained of fecal soiling, scoring on a numeric rating Scale (NRS), reached a total of 119 (mean 3.6). Of these, 18 (66%) were cured (NRS 0), 5 noted a very significant improvement (NRS <50%), and the other 4 reported no change. Of the 13 patients (27%) with pain in the lower pelvis (total NRS 57), 9 (71%) were cured (NRS 0), and the others reported a 50% improvement (NRS <50%)

Anatomical results: In all patients the vagina showed normal width and length and was normal in its axis. POPQ analysis showed median postoperative C – point at –9 (–7 to –11).

Radiologic results: Postoperative single contrast defecating proctography was obtained in 19 patients (40%). 17/19 (89%) showed a normal anatomy of the rectum and no intussusception (Fig. 4b). In 2/19 (11%) patients a minimal residual intussusception could be detected. However, all rectoceles disappeared. In all other cases patients denied to undergo this uncomfortable examination because they felt completely cured, especially when they lived too far from our hospital.

Complications: Intraoperative: In one patient during dissection of a large rectocele the anterior rectal wall was incidentally incised. After primary double layer suture the procedure was carried on according to standard protocol. In another patient we found the IVS tape inside the rectum on the right side after completing the procedure during routine rectal examination. After visualization by rectal speculum the perforating part of the tape was excised, the two little holes were sutured by one single stitch suture each and the patient was put on postoperative oral opium and prolonged antibiotic prophylaxis for 3 days.

Mesh erosions appeared in 2 cases and were treated by excision of the eroded tape in an outpatient setting. We did not see any haematoma, abscess formation or any other perioperative complication.

DISCUSSION

The concept of “tension free” reconstruction of distorted anatomy using intravaginal polypropylene slings has been shown to be successful for the treatment of various pelvic floor disorders in the female.⁷⁻¹² Until now it has been

used to treat stress urinary incontinence, as well as various degrees of uterine and/or vaginal descensus or prolapse. These minimally invasive techniques aim to treat impaired pelvic floor function by restoration of anatomy.

The functional results of existing rectopexy regimes for these cases are not only traumatic, but widely unsatisfactory.⁵ Our results appear to confirm our hypothesis that the sacrouterine ligaments are an essential structure for normal function of the anorectal complex.⁷ Furthermore, reinforcement of the sacrouterine ligaments by insertion of a posterior IVS tape is successful in restoring both anatomy and function, as demonstrated radiologically in Fig. 4b.

This “tension-free” approach sets out to mimic normal anatomy without distortion, by repairing all the anatomical levels which contribute to anorectal opening and closure.⁹⁻¹⁰ This 3 level approach does not alter the geometry or the axis of the pelvic organs, and would appear to offer a more anatomical, and therefore, more functional treatment plan than isolated rectopexy or sacrocolpopexy. The latter only perform a level 1 repair. We firmly believe that stretching and over-correction of the organs should be avoided. This is certainly the case for rectopexies. During rectopexy a distance of about 10 cm of the rectum is functionally disturbed by fixation of the rectal wall onto the sacral periostium. This may be the reason for the reported poor functional results of this procedure. The same reservations apply for sacrocolpopexy, a method which bears the problem of over-correction if fixated to the sacral promontory. Using posterior IVS avoids the danger of over-correction, since neither the rectum, nor the vagina are fixed to bony (and therefore immobile) structures during this procedure. Above all, organ mobility, a key element in pelvic floor function, can be maintained, as described in the Integral Theory.⁹⁻¹²

Compared to rectopexy, posterior IVS is less invasive and thereby less susceptible to surgical complications. In a large series,¹³ 33% operative morbidity was reported after rectopexy. Most complications occurred in the early postoperative period, including severe complications like bowel obstruction and ileus, but also late complications and fistulas occurred. In our series we did not have a single severe complication. Erosions (4% incidence) and their accompanying vaginal discharge may sometimes be disturbing to the patient, but really, they are a minor problem, and usually easy to treat.

We were not successful with this approach in 3/48 patients. Interestingly, these patients showed normal anatomy on defecation proctograms. Our anatomical concepts (Figs. 1 & 2) do not seem to explain such normal findings. All three patients were sent to a specialized gastroenterologic unit for further workup, with no success to date.

In our series hysterectomy did not appear to be a factor in clinical success or failure.

Cure of posterior zone symptoms such as pelvic pain is explained in previous works.^{7, 10, 12} The simultaneous cure of fecal incontinence and difficulty with bowel emptying is theoretically addressed in Part 1. The uterosacral ligament and perineal body are key functional insertion points for the backward/downward vector forces, and also, the rectovaginal fascia. Lax insertion points may invalidate these muscle forces, disabling the rotation around the anus necessary for anorectal closure, and also, the opening out of the anorectal angle during evacuation.

As concerns cure of FI, this work differs significantly from Studies No 9,10 &11 in this issue. All patients undergoing surgery had symptoms of obstructed defecation and radiological evidence of rectal intussusception; 56% had FI, and 85% of these were cured, or very significantly improved by a posterior sling repair limited exclusively to the posterior suspensory ligaments, the uterosacrals. The study emphasizes the importance of investigating such patients holistically: assessing evacuation and rectal wall intussusception, as well as incontinence. A major improvement (85%) in FI symptoms was achieved with repair only of the posterior ligaments. Whether the cure rate would have been improved with a midurethral sling is not known. Neither do we know how many patients had evidence of muscle damage, as this was not tested.

CONCLUSIONS

With regard to “obstructed defecation”, rectal intussusception and FI, we find that this new approach offers clear clinical advantages compared to more conventional procedures, minimal pain and trauma, rapid recovery, and fewer complications. It is a correct anatomical approach with no unphysiologic fixation of the rectum. Thereby the function of defecation is restored and the vast majority of our patients felt rapid normalization of stool habits immediately after surgery. Although the number is small, the demonstrated results are promising, suggesting this new approach should be pursued further.

REFERENCES

1. Thompson JR, Chen AH, Pettit PD, Bridges MD. Incidence of occult rectal prolapse in patients with clinical rectoceles and defecatory dysfunction. *Am J Obstet Gynecol* 2002; 187: 1494-9.
2. Kahn MA, Stanton SL. Posterior colporrhaphy: its effects on bowel and sexual function. *Br J Obstet Gynecol* 1997; 104: 82-6.
3. Baessler K, Schüssler B. Abdominal sacrocolpopexy and anatomy and function of the posterior compartment. *Obstet Gynecol* 2001; 97: 678-84.
4. Fox SD, Stanton SL. Vault prolapse and rectocele: assessment of repair using sacrocolpopexy with mesh interposition. *Br J Obstet Gynecol* 2000; 107: 1371-5.
5. Graf W, Karlbom U, Pahlman L, Nilsson S, Ejerblad S. Functional results after abdominal suture rectopexy for rectal prolapse or intussusception. *Eur J Surg* 1996; 162: 905-11.
6. Nichols DH, Randall CL. Massive eversion of the vagina In: Nichols DH, Randall CL (eds). *Vaginal Surgery*, 3rd ed. Baltimore: Williams Wilkins, 1989; 328-357.
7. Petros PEP. Chapter 2 - The Anatomy and Dynamics of Pelvic Floor Function and Dysfunction. In: “The Female Pelvic Floor, Function, Dysfunction and Management According to the Integral Theory. Springer Heidelberg 2004; 42-47.
8. Baden WF, Walker TA. Genesis of the vaginal profile: a correlated classification of vaginal relaxation. *Clin Obstet Gynecol* 1972; 15: 1048-54.
9. Petros PEP. Vault prolapse II: Restoration of dynamic vaginal supports by the infracoccygeal sacropexy, an axial day-care vaginal procedure. *Int J Urogynecol and Pelvic Floor* 2001; 12: 296-303.
10. Petros PEP. Chapter 4 - Reconstructive Pelvic Floor Surgery, in “The Female Pelvic Floor, Function, Dysfunction, and Management According to the Integral Theory Springer Heidelberg 2004; 77-137.
11. Petros PE. Cure of urinary and faecal incontinence by pelvic ligament reconstruction suggests a connective tissue aetiology for both. *International Journal of Urogynecology* 1999; 10: 356-360.
12. Petros PE & Ulmsten U. An Integral Theory of female urinary incontinence. *Acta Obstet Gynecol.Scand* 1990; Supp. 153: 1-79.
13. Schultz I, Mellgren A, Dolk A, Johansson C, Holmstrom B. Long-term results and functional outcome after Ripstein rectopexy. *Dis Colon Rectum* 2000; 43: 35-43.

Competing interests: none.

Correspondence to:

Dr BURGARD ABENDSTEIN

E-mail: burghard.abendstein@bkh-hall.or.at

Conclusions

Conclusions and future directions

PETER PETROS (*) - MICHAEL SWASH (**)

(*) Royal Perth Hospital, University of Western Australia

(**) Dept of Neurology, The Royal London Hospital, London, UK

The Theory states: "Anorectal dysfunction in the female is mainly caused by lax suspensory ligaments inactivating anorectal muscle forces".

The aim of Part 2 was to directly challenge the Theory by repairing specific ligaments, pubourethral only (Study No. 9), pubourethral and uterosacral (Study No. 10), pubourethral, uterosacral, ATFP, cardinal, and perineal body (Study No. 11), and uterosacral and perineal body only (Study No. 12). We used the pictorial algorithm (Fig. 1) to guide which zone to repair, anterior, middle or posterior. Clinical results from Studies 9-12 appeared to validate these assumptions.

Accurate diagnosis of structural damage

The first step in understanding causation is the appreciation that all structures work together inextricably as a system. Though our results indicated that laxity in the pubourethral and/or uterosacral ligaments appeared to be the main cause of the idiopathic fecal incontinence, these cannot be the only causes. It is theoretically possible for any of the structures in Fig. 1, red lettering, to contribute to the genesis of fecal incontinence. All these structures work synergistically, and each structure may contribute a different weight to the system. The varying size of each bar (Fig. 1), expresses this variation pictorially.

Though external anal sphincter damage was specifically excluded from this study, it needs to be diagnosed and repaired where present. The EAS has a key role in our theory. With reference to Fig. 1, EAS is a tensor of the perineal body, and the inferior insertion point of the downward rotating muscle force 'LMA' (arrow). Inability to tension the perineal body may invalidate backward stretching of the posterior vaginal wall by LP (backward arrow), with similar consequences to those reported in Study No. 12.

One consequence of the theory is that there has to be a critical mass below which a severely damaged muscle will not have sufficient contractile force to effect organ closure. Even tenotomy muscles can atrophy to a point of no return. Severe muscle damage may explain the lower cure rate in Study No. 10, which we consider was the worse affected group. At present we have no method for diagnosing severe muscle damage.

Surgery

One biomechanical consequence of our theory, which has surgical implications, is that the ligaments and fascia require a critical length and tension for optimal muscle contraction. The advent of the TFS provides a tool which can, for the 1st time, restore tension as part of the ligament/fascia reconstruction. The results of Study No11 are encouraging, but far more data will be required to fully assess the effects of surgical tensioning on restoration of function.

Finally there is the consequence of operating on damaged tissues. Study No 10 reports instances where repair of

one ligament may divert the pelvic forces to stretch another (subclinically damaged) ligament to cause de novo symptoms. For this reason, it may be prudent to consider routinely repairing both the pubourethral and uterosacral ligaments and in patients with idiopathic fecal incontinence, and the uterosacral ligaments, perineal body and rectovaginal fascia in patients with 'obstructed defecation'.

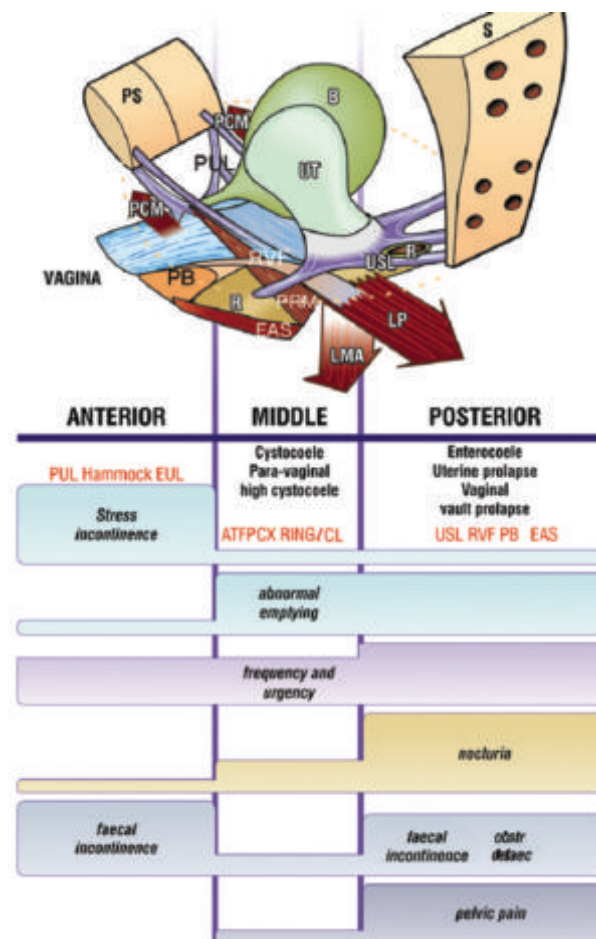


Fig. 1. – Pictorial diagnostic algorithm. The algorithm related prolapse and symptoms to 3 zones of damage. The structures (red lettering) denote the connective tissue structures in each zone which are liable to be damaged. PUL: pubourethral ligament; EUL: external urethral ligament; ATFP: arcus tendineus fascia pelvis; cx ring; cervical ring; CL: cardinal ligament; USL: uterosacral ligament; RVF: rectovaginal fascia; PB: perineal body; EAS: external anal sphincter.

Editorial Note

A number of experts have been invited to submit a commentary on this issue of the journal. Space permits us to publish only one commentary in conjunction with the papers of Petros et al., and this commentary was chosen because it was the first to be completed and returned. More commentaries will be printed in the next issue. Others are invited and will also be considered for publication.

The editors of *Pelvipерineology* see this as a wonderful opportunity to open up discussion of anorectal function to the general pelvic floor community. Please consider this opportunity to contribute to the discussion by submitting correspondence for publication.

Invited comment

Some years ago in an attempt to obtain the Holy Grail of every medic, the perfect golf swing, I found myself seduced into buying a set of instructional videos by a small town American golf instructor, Dalton McRary, who had by various observations of still images of golfers of yesteryear, where shutter speeds were not fast enough to prevent motion blur, come to the conclusion that much of the perceived and taught theory regarding the golf swing was in fact incorrect. He based his system for the golf swing on these observations.¹ More importantly in the introduction booklet to the videos he asks the reader to make a small mental leap of faith. He asked that although he did not necessarily expect the reader to automatically believe everything they were about to read and see, he asked them to open their minds to the possibility that it may be true. In other words to give the hypotheses a chance before closing ones mind to the fact that they went against the currently accepted wisdom. It was with this in mind that I read the work by Petros and Swash.

Our understanding of pelvic floor function, at least in colorectal circles is that the main cause of incontinence and other disorders is due to a lack of muscle power. Whether this is due to damaged muscles, damaged innervation or lack of muscle bulk, it is thought that it is an inherent lack of contractile strength that contributes to the dysfunction. This approach is confirmed by the current treatment rationales to help restore function, namely, muscle repair, sacral nerve stimulation and biofeedback. The decision as to which mode of treatment to use is based on the commonly performed investigations of anorectal physiology, pudendal nerve terminal motor latency recordings and anal ultrasound to gauge respectively, muscle power, nerve conduction and muscle damage.

It would appear that the initial observation made by the authors, that prompted much of this work was the finding that the vast majority of patients with concomitant urinary

and faecal incontinence treated with a mid-urethral sling-plasty were not only cured of their urinary symptoms but also their faecal symptoms. No attempt had been made to correct the muscles themselves. This observation clearly set the authors thinking about a possible mechanism for such an outcome and to rethink the current understanding of pelvic floor function.

The authors have therefore presented the reader with a new concept of anorectal function they have called "The Musculoelastic Theory". This concept is supported by the presentation of 12 papers which act to support the original concept, support each other and bring together observations made by other authors in previously published works. The various presented works involve individual case reports, which must obviously be taken on their individual merit only, along with small and large clinical series involving surgical repair, histological evaluations and radiological studies.

The basic tenet of The Musculo-Elastic Theory is that although faecal incontinence is in part contributed to by muscle damage or nerve conduction abnormalities, it can to a greater degree be explained by damage to, and weakening of the ligamentous attachments of the pelvic floor musculature, which if corrected surgically can produce a significant improvement in symptoms, without necessarily having to directly address the actual muscles or nerves themselves. It is not entirely unreasonable to assume that taut, appropriately directioned ligamentous attachments are fundamental to good muscle function. We have all heard the patient who is convinced her pelvic troubles all started after her hysterectomy.

Theoretically the theory has much to support it. The pelvic floor muscles are somewhat unique in that they represent a group of skeletal muscles, under voluntary as well as reflex control that although arising from bone insert directly into the soft tissues upon which they act. For the majority of muscles in the body which connect to bone at their origin as well as insertion, it is rare that they become stretched and lax to the point that they are unable to function as intended. With lack of use, or focal damage these bone oriented muscles may atrophy and weaken, but as they tend to maintain their original length can be re-strengthened with physiotherapy and exercise. How does a totally snapped hamstring in an Olympic athlete ever function normally again? When skeletal muscle inserts into soft tissue only, it is plausible that when overstretched or torn, especially if this involves ligamentous damage at the origin, that as normal length cannot easily be restored that power and function will be compromised. It is not hard to imagine how such stretching and damage can occur during pregnancy and childbirth. This may help to explain why the platysma, with no bony attachments is such a giveaway to our real age.

There is some evidence to support this. Krochmal et al studied muscle recovery following tenotomy and reinsertion of skeletal muscle in rats, by varying the length of the reinserted tendon.² In those muscles where the tendon was shortened, producing greater tension on the muscle fibres, greater muscle mass, greater muscle length, greater phys-

iological cross-sectional area, greater maximum isometric force, and greater maximum power relative to the control tendon length group was achieved. Admittedly the nerve was left intact but it is difficult to argue with the results. Furthermore, the other experimental group in this study, where the tendon was lengthened thereby inducing some laxity did not necessarily lose contractile power. It would however have reduced the degree of movement in the related joint. Our basic understanding of muscle physiology at undergraduate level should also allow us to accept this without too much difficulty.

We also know from the work by Malouf et al that external sphincter repair although producing good initial results has a significant rate of attrition.³ More interestingly, Malouf noted that other defaecatory disorders became apparent after such repair. Can we deduce a possible explanation for this from the work of Petros and Swash. Perhaps the initial overlap recreated tension in the muscle to allow an initial improvement, but as it does not address the main ligamentous bony attachments of the pelvic floor musculature, is only short lived. Perhaps the tension produced initially also has a distracting affect on other pelvic ligaments against their normal direction of activity thereby producing other defaecatory effects. Does sacral nerve stimulation work only by neuromodulation? Does it have some of its effect by increasing the resting tension of the muscle fibres. Maybe. I don't know, I'm only guessing. But the whole concept of a musculoelastic contribution to incontinence will produce many more questions.

Do we need to re-evaluate our pre-treatment investigations? Is sphincter physiology really valid? Is identification of muscle damage a good means for surgical selection? What does pudendal nerve conduction really tell us? Should all

patients with pelvic floor dysfunction of any kind undergo proctography? Should urodynamics be part of anorectal investigation? How can we quantify musculoelastic function? Which are the important ligaments for each disorder? How can we repair/strengthen them? Should we change our approach to rectal prolapse? The list is endless.

I am sure that the authors will agree that works such as this are rarely the final solution. There are aspects of the work that may need further consideration. The use of Poiseuille's formula only applies to laminar flow of an incompressible liquid through a circular tube of constant proportions. Its application in helping to explain continence in a narrowed rectum may not be relevant. That's not to say that retensioning the rectum doesn't help incontinence. It's just that it is unlikely to be explained by mere physics. The papers do however contain much to think about and will stimulate a huge amount of further study and research. As readers, if minds are kept open, the pelvic floor community has been thrown a fertile seed from which I am sure much will grow.

1. Dalton McCrary Straight Shootin' Golf. TVi productions.
2. Krochmal DJ, Kuzon WM Jr, Urbanchek MG. Muscle force and power following tendon repair at altered tendon length. *J Surg Res* 2008; 146: 81-9. Epub 2007 Oct 24.
3. Malouf AJ, Norton CS, Engel AF, Nicholls RJ, Kamm MA. Long-term results of overlapping anterior anal-sphincter repair for obstetric trauma. *Lancet* 2000; 355: 260-5.

Dr. DARREN M. GOLD

Senior Lecturer and Colorectal Surgeon
St Vincent's Hospital and Clinical School, UNSW
Darlinghurst, Sydney
Australia